

TOXICOLOGICAL PROFILING OF METHANOLIC AND AQUEOUS EXTRACTS OF *AMORPHOPHALLUS COMMUTATUS* VAR. *WAYANADENSIS* - ENDANGERED MEDICINAL PLANT IN RODENT MODELS

¹SREENA RAJ, ¹MERLENE ANN BABU, ²V. ABDUL JALEEL, ^{1*}K M GOTHANDAM

¹School of Bio Sciences and Technology, VIT University, Vellore - 632014, ²Department of P.G studies and Research in Botany, Sir Syed College, Thaliparamba, Kannur, Kerala-670142, India.

Email: gothandam@yahoo.com

Received: 10 March 2014, Revised and Accepted: 7 April 2014

ABSTRACT

Objective: *Amorphophallus commutatus* var. *wayanadensis* (ACW) is exclusive endemic of Wayanad has been used among the traditional medicinal healers of tribal communities of Wayanad for the treatment of various ailments. Our aim of the study is to evaluate the toxicity profile of ACW by acute and sub-acute toxicity studies in rodents.

Methods: In acute toxicity studies, mice were orally administered of single doses of 1000 and 2000mg/kg b.w. of methanolic and aqueous extract and sub-acute toxicity studies were performed by administration of 200 and 400mg/kg b.w. orally for 28 days.

Results: In acute toxicity studies, administration of methanolic and aqueous extract didn't observe any signs of mortality or toxicity up to 2000mg/kg b.w. No significant change in the physical, biochemical, hematological and histopathology analysis were observed for methanolic and aqueous extracts treated animals in sub-acute toxicity studies.

Conclusion: The methanolic and aqueous extract of *Amorphophallus commutatus* var. *wayanadensis* is relatively safe for long term oral administration fulfilling the basic priority for its use in traditional medicinal therapies.

Keywords: Acute toxicity; Sub-acute toxicity; *Amorphophallus commutatus* var. *wayanadensis*; LD₅₀ values; Phytochemical analysis.

INTRODUCTION

Amorphophallus commutatus is a wild herb which belongs to the family Araceae, mainly distributed in the tropical forest regions of peninsular India. Corns of this plant have been used by traditional healers for treating various ailments. According to Jain *et al.*, 2005 tuber of the plant has been used as antidote for snake bite. Pawra tribes of Nandurbar district of Maharashtra use the tuber paste of *A. commutatus* for curing scabies [2]. *A. commutatus* is used by the tribal communities of Dang region of Rajasthan as cooling agent [3]. Local communities of Kolhapur district of Maharashtra used to have tuber of this plant species for piles and the water in which tuber is boiled is used for mouth diseases [4]. *Amorphophallus commutatus* var. *wayanadensis*, commonly known as 'kattuchenna' is widely used among the tribal communities of Wayanad district for piles [5]. According to the tribal healers the corns of the plant is a boon to the patients having piles. *A. commutatus* is a Red listed medicinal plant species with a vulnerable status globally [6]. As the particular species of *Amorphophallus* is rare in occurrence and have potential medicinal values, the pockets or zones rich in its occurrence should be conserved for future [7]. Ethnobotanical knowledge on the traditional uses of *Amorphophallus commutatus* var. *wayanadensis* was collected through structured interviews of the Kuruma and Kurichar tribal communities of Wayanad district of Kerala, India. The efforts in our lab to evaluate pharmacological potential to this wild medicinal plant have found to be fruitful. Previous studies in our laboratory demonstrated potential antibacterial activity against pathogenic strains which validated the traditional claim of its use for microbial infections [8].

Even though the corns of *Amorphophallus commutatus* var. *wayanadensis* have potential ethno-botanical uses among various tribal communities, till date there is no relevant scientific literature available regarding the toxicological profiling of the plant which is essential for the validation of the traditional claiming.

Amorphophallus commutatus var. *wayanadensis* belong to the family Araceae which contain chemical compounds like calcium oxalate which causes irritation when consumed raw. Studies as demonstrated proteolytic enzymes along with other compounds are responsible for the irritation and several genera of this family have been listed as poisonous plants [9]. Hence identification of safest and most effective therapies is one major need of the hour for the promotion of traditional medicinal systems in the western global health market [10]. Therefore the present study were conducted to evaluate the toxicity profile of methanolic and aqueous extracts of *Amorphophallus commutatus* var. *wayanadensis* by acute and sub-acute toxicity studies by oral administration of the extract in rodents.

MATERIALS AND METHODS

Chemicals and reagents

The chemicals used in this study such as sodium chloride, ethylenediaminetetraacetic acid (EDTA), dimethyl sulfoxide (DMSO) and solvents used in the extraction procedure such as petroleum ether and methanol and were procured from Hi-media laboratories (India). All the chemicals and solvents used for the study are of analytical grade.

Plant material

The tubers of *Amorphophallus commutatus* var. *wayanadensis* were collected from the forest hills (Western Ghats) of Wayanad district, Kerala, India (11°36'18"N latitude and 76°04'59"E longitude). The plant species were authenticated by Dr. V. Abdul Jaleel, Assistant professor, Sir Syed College, Kerala and the herbarium specimen was deposited in Calicut University Herbarium, Malappuram, Kerala with the accession number RIA 62. The tubers were thoroughly cleaned with running distilled water to remove dirt and shade dried for 2 weeks. The dried tubers were powdered to fine size using electric

grinder and stored airtight until further use.

Extraction

The dried and powdered tubers of *A. commutatus* (100 g) were first defatted in soxhlet apparatus using 300 ml of petroleum ether. The defatted powdered samples were dried and further extracted using methanol followed by water, 300 ml each for 72 h in soxhlet apparatus [11]. The extracts were filtered using Whatman No. 1 filter paper using Buchner funnel. The methanolic extract thus obtained was concentrated at 40°C under reduced pressure using rotary evaporator (Superfit Rotavap model: PDU-6D) and the aqueous extract was dried using freeze drier (Bench top SLC model 4KBTZL-105, SP Industries, USA) to give a yield of 1.1 g and 1.3 g of methanolic and aqueous extract respectively. The dried extracts were stored in refrigerator for further use.

Phytochemical analysis

The methanolic and aqueous extracts were re-dissolved in DMSO and used for phytochemical analysis studies. Preliminary qualitative phytochemical screenings of the methanolic and aqueous extract of *A. commutatus* were determined by Harborne, 1984; Trease and Evans, 2002 [12, 13].

Total Phenolic content

The total phenolic content of methanolic and aqueous extract of *A. commutatus* was determined by Folin-Ciocalteu method [14] with slight modifications using gallic acid as standard. Briefly, 50 µl of methanolic and aqueous extracts of *Amorphophallus commutatus* was mixed with 2.5 ml of Folin-Ciocalteu reagent (1:10) and kept for 3 min. After incubation 2 ml of Na₂CO₃ (7.5% w/v) was added, mixed well and allowed to stand for 1 h at room temperature and the absorbance was measured spectroscopically at 765 nm (GeneQuant 1300, GE Healthcare, UK). The total phenolic content was expressed as mg gallic acid equivalent/ g extract.

Total flavonoid content

The total flavonoid content of the methanolic and aqueous extract was estimated with slight modifications [15]. 0.5 ml of extracts dissolved in DMSO was mixed with 3 ml of distilled water and 0.3 ml of 5% NaNO₂. After 5 min, 0.3 ml 10% AlCl₃ was added and incubated for 2 min. To this reaction mixture 1M NaOH was added and the final volume made up to 10 ml. The absorbance was measured spectrophotometrically at 510 nm against reaction blank (GeneQuant 1300, GE Healthcare, UK). The total flavonoid content was expressed as mg quercetin equivalent/ g extract.

Animals

Swiss albino mice (20-25 g) of either sex were obtained from the Animal House, VIT University, Vellore, India and were randomly divided into various experimental groups. All animals were housed in open mesh stainless steel cage in a room maintained at controlled temperature condition of 23±2°C and 12 h light and dark cycle. Commercially available feed pellets and water ad libitum were given to the animals and were acclimatized for one week prior to the experiments. Experimental protocols were approved by the Animal Ethical committee, VIT University, Vellore (Ref No.VIT/IAEC/V/3).

Acute toxicity studies

Acute toxicity studies were conducted in swiss albino mice of either sex (20-25 g), according to the OECD guidelines for testing of chemicals OECD-420 (adopted 17th December 2001) with slight modifications [16]. Mice of either sex were equally divided into five groups containing six mice each. After acclimatization to the experimental conditions, animals were fastened for 3-4 h prior to dosing and the animals were weighed before treatments. The different concentrations of methanolic and aqueous extracts were prepared by dissolving in 0.9% saline. The control group (group I) received 0.9% saline, while the experimental groups received methanolic and aqueous extracts administered orally (10 ml/kg) by gastric gavages [17]. Group II and III received methanolic extract and Group IV and V received aqueous extract of *A. commutatus* at a dosage of 1000 and 2000 mg/kg b.w. After the administration of

extracts, food has been withheld for 1-2 h. The animals were individually observed periodically 30 mins for the first 4 h and once daily for the further 14 days. The animals were observed for toxicity signs like changes in skin, fur, eyes, mucous membranes and behavioral changes like salivation, sleep, tremors, convulsions, diarrhoea, urination, lethargy and coma [18]. The animals were observed for the mortality and morbidity for 14 days and their body weight has been recorded periodically [19]. The surviving animals after 14 days were sacrificed to evaluate pathological changes of internal organs.

Sub acute toxicity studies

Swiss albino mice (20-25 g) of either sex were used to evaluate the sub-acute toxicity studies according to OECD- 407 guidelines (adopted on 3rd October, 2008) for repeated dose 28 days oral toxicity studies in rodents [20]. Thirty animals were divided into five groups containing six animals each. The control group, Group I received 0.9% saline p.o daily for 28 days. The experimental groups, Group II and Group III administered orally methanolic extract and Group IV and V received aqueous extract of *A. commutatus* in the doses 200 and 400 mg/kg b.w. for 28 consecutive days [21]. The body weights of animals were measured every week throughout the experimental period [22]. All the animals prior to sacrifice were fasted overnight with free access of water. The animals were anesthetized with pentobarbital sodium (30 mg/kg) by intraperitoneal injection [23] and blood was collected by cardiac puncture into two collecting tubes with and without EDTA for hematological and biochemical analysis respectively. Animals were sacrificed and internal organs were surgically extracted for histopathological analysis.

Biochemical analysis

The blood samples were allowed to clot completely and were centrifuged at 3000 rpm for 15 min. Pale yellow upper serum layer were collected and stored in -20°C until use. The serum samples were analyzed for biochemical parameters like total protein, alanine aminotransferase (ALT), alkaline phosphatase (ALP), aspartate transaminase (AST), creatinine, urea, total cholesterol, glucose, albumin, uric acid, total and direct bilirubin, calcium, sodium and potassium [24, 25, 26].

Hematological analysis

The whole blood samples collected in anticoagulant added tubes were used for hematological studies [27, 28, 29]. Hematological parameters like erythrocyte count (RBC), platelet count, total leucocyte count (TLC), differential leucocyte count (DLC), hemoglobin (Hb), mean corpuscular volume (MCV), hematocrit (HCT), mean corpuscular hemoglobin concentration (MCHC) and mean corpuscular hemoglobin (MCH) were analyzed using haematology auto analyser (PE-6000 Auto-hematology analyzer, Prokan Electronics Inc, China).

Histopathological analysis

Kidney, liver and spleen were collected, washed thoroughly in PBS solution and weighed immediately. After weighing the tissue samples were stored in 10% formalin for histopathological studies. Thin sections of organs were prepared using microtome and thin sections of samples were mounted on microscopic glass slides and further stained with hematoxylin-eosin stain to visualize morphological abnormalities [30, 31].

Statistical analysis

The results were expressed as Mean ± S.D. Statistical analysis was performed using one way ANOVA using Graphpad prism software version 5.01 software (GraphPad Software, Inc., San Diego, USA). Difference between groups of P value <0.05 were considered significant.

RESULTS

Phytochemical analysis

The phytochemical screening of the methanolic extract of tubers of *A. commutatus* showed the presence of terpenoids, steroids,

phenolics, flavanoids, glycosides and fatty acids. Reducing sugars, saponins, glycosides and phenolic compounds found to be the major phytoconstituents present in the aqueous extract. The total phenolic and flavonoid content was found to be higher in the methanolic extract compared to the aqueous extract. The methanolic extract exhibited highest phenolic content 15.56 ± 2.8 mg gallic acid equivalent/g extract followed by aqueous extract 8.44 ± 4.1 mg gallic acid equivalent/g extract. The total flavonoid content of different extracts of *A. commutatus* varied from 5.31 ± 2.3 and 14.74 ± 3.9 mg quercetin equivalent/ g extract for aqueous and methanolic extracts respectively.

Acute toxicity studies

Oral administration of methanolic and aqueous extracts of *A. commutatus* didn't show any mortality up to the concentration of 2000 mg/kg b.w. during 14 days of the study. The experimental animals didn't show any physiological and behavioral changes, except for mild sedation showed by the 2000 mg/kg b.w. experimental group for the initial 1 h after the drug administration. There is no significant difference in the body weight among animals of experimental and control groups.

Sub-acute toxicity studies

Body weight measurement

The experimental group didn't show any significant variation in the body weight compared to the control group. Table 1 showed the mean initial, mean final and mean changes in the body weight of mice during the 28 days of the experimental studies.

Relative organ weight measurement

The administration of methanolic and aqueous extracts of *A. commutatus* did not show any significant changes in the organ weight among the experimental and control groups (Table 2).

Biochemical analysis

Evaluation of the methanolic and aqueous extract of *A. commutatus* on the biochemical parameters showed slight decrease in the creatinine levels in plasma (Table 3). But there is no significant variation in other parameters. Hepatic enzymes like alkaline

phosphatase, aspartate transaminase and alanine aminotransferase did not show any significant difference between the experimental and control groups.

Table 1: Relative body weight of mice treated with methanolic and aqueous extracts of *Amorphophallus commutatus* var. *wayanadensis* in sub-acute toxicity study

Groups		Mean body weight (g)	
		Initial weight on day 1	Final weight on day 28
Group I	Control	24.45 ± 0.56	25.7 ± 0.58
Group II	Methanol (200mg/kg,p.o)	24.41 ± 0.65	25.76 ± 0.53
Group III	Methanol (400mg/kg,p.o)	24.41 ± 0.83	25.67 ± 0.74
Group IV	Aqueous (200mg/kg,p.o)	24.36 ± 0.58	25.59 ± 0.62
Group V	Aqueous (400mg/kg,p.o)	24.35 ± 0.68	25.82 ± 0.49

Table 2: Relative organ weight of mice treated with methanolic and aqueous extracts of *Amorphophallus commutatus* var. *wayanadensis* in sub-acute toxicity study

Groups		Mean Organ Weight (g)		
		Liver (g)	Kidney (g)	Spleen (g)
Group I	Control	1.71 ± 0.1	0.27 ± 0.02	0.21 ± 0.02
Group II	Methanol (200mg/kg,p.o)	1.85 ± 0.08	0.28 ± 0.05	0.21 ± 0.03
Group III	Methanol (400mg/kg,p.o)	1.81 ± 0.13	0.26 ± 0.01	0.183 ± 0.04
Group IV	Aqueous (200mg/kg,p.o)	1.57 ± 0.21	0.26 ± 0.03	0.194 ± 0.01
Group V	Aqueous (400mg/kg,p.o)	1.74 ± 0.35	0.25 ± 0.03	0.20 ± 0.02

Table 3: Biochemical analysis of mice treated with methanolic and aqueous extracts of *Amorphophallus commutatus* var. *wayanadensis* in sub-acute toxicity study

Parameters	Group I	Group II	Group III	Group IV	Group V
	Control	Methanol (200mg/kg,p.o)	Methanol (400mg/kg,p.o)	Aqueous (200mg/kg,p.o)	Aqueous (400mg/kg,p.o)
ALP (IU/L)	71.485 ± 0.6	72.29 ± 0.79	70.74 ± 2.05	70.82 ± 1.21	71.965 ± 0.91
AST (IU/L)	57.9 ± 1.03	57.69 ± 1.0	58.23 ± 2.57	57.52 ± 2.09	58.68 ± 1.54
ALT (IU/L)	26.75 ± 0.92	26.33 ± 0.51	24.26 ± 1.89	26.36 ± 1.47	26.33 ± 1.21
Calcium (mg/dL)	6.33 ± 0.31	6.34 ± 0.34	6.4 ± 0.30	5.98 ± 0.46	6.22 ± 0.46
Creatinine (mg/dL)	0.34 ± 0.05	0.29 ± 0.07	0.32 ± 0.04	0.31 ± 0.03	0.3 ± 0.02
Urea (mg/dL)	66.08 ± 0.8	66.79 ± 0.69	66.47 ± 1.25	68.20 ± 1.48	67.39 ± 1.28
Uric acid (mg/dL)	6.95 ± 0.31	6.84 ± 0.39	6.79 ± 0.47	6.84 ± 0.44	6.52 ± 0.18
Glucose (mg/dL)	150.29 ± 1.7	150.68 ± 1.83	142.94 ± 3.8	150.80 ± 1.12	150.10 ± 2.52
Albumin (g/dL)	4.54 ± 0.37	4.6 ± 0.30	4.69 ± 0.19	4.66 ± 0.25	4.65 ± 0.14
Total cholesterol (mg/dL)	77.15 ± 1.43	76.58 ± 1.01	77.49 ± 0.96	76.94 ± 0.88	76.59 ± 1.22
Triglycerides (mg/dL)	45.08 ± 0.65	45.85 ± 0.59	45.60 ± 1.52	44.77 ± 1.42	44.47 ± 2.05
Sodium (mmol/L)	143.47 ± 2.1	144.34 ± 1.41	144.37 ± 1.50	147.41 ± 2.64	143.23 ± 2.29
Potassium (mmol/L)	4.76 ± 0.23	4.85 ± 0.16	4.69 ± 0.21	4.58 ± 0.35	4.41 ± 0.31
Total bilirubin (mg/dL)	1.34 ± 0.13	1.38 ± 0.09	1.37 ± 0.11	1.33 ± 0.19	1.54 ± 0.23
Direct bilirubin (mg/dL)	0.26 ± 0.03	0.26 ± 0.03	0.24 ± 0.02	0.22 ± 0.05	0.24 ± 0.04
Total protein (g/dL)	8.88 ± 0.29	8.64 ± 0.28	8.88 ± 0.23	9.02 ± 0.35	8.85 ± 0.31

Hematological analysis

Repeated dose study of methanolic and aqueous extracts of *A. commutatus* on the hematological parameters revealed no statistical significant difference among control and experimental group in the hematological parameters being studied (Table 4).

Table 4: Hematological analysis of mice treated with methanolic and aqueous extracts of *Amorphophallus commutatus* var. *wayanadensis* in sub-acute toxicity study

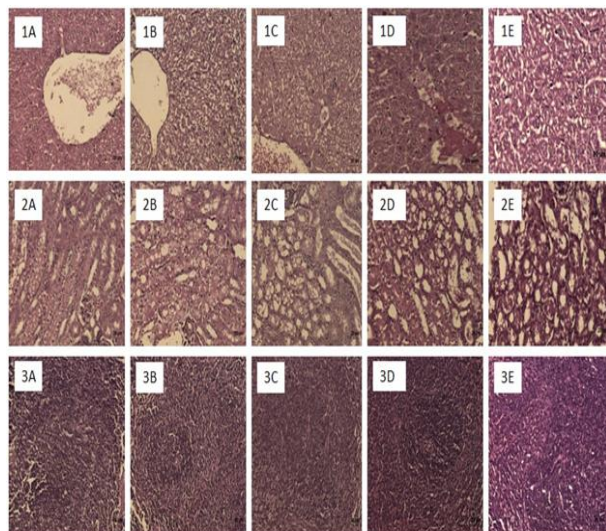
Parameters	Group I	Group II	Group III	Group IV	Group V
	Control	Methanol (200mg/kg, p.o)	Methanol (400mg/kg, p.o)	Aqueous (200mg/kg, p.o)	Aqueous (400mg/kg, p.o)
WBC (10 ³ /μL)	7.44± 0.38	7.47±0.58	7.48 ± 0.14	7.62 ±0.17	7.65 ± 0.13
Neutrophil (%)	27.56±1.6	26.87 ±1.33	26.79 ± 2.12	25.91± 1.54	26.14±2.29
Eosinophil (%)	4.97± 0.27	4.99± 0.47	4.94± 0.47	5.45± 0.24	5.29± 0.27
Basophil (%)	0.17±0.04	0.14±0.07	0.14 ±0.05	0.18± 0.06	0.17±0.04
Monocyte (%)	3.74± 0.29	3.83±0.41	3.57± 0.32	3.54±0.33	3.28±0.17
Lymphocyte (%)	55.89±1.4	56.75±2.48	54.97±1.64	55.06±1.89	55.75±2.49
RBC (10 ⁶ /μL)	5.58±0.31	5.45±0.22	5.61± 0.23	5.67± 0.41	5.47±0.29
Platelet (10 ⁵ /μL)	3.62±0.14	3.6±0.09	3.73±0.12	3.42±0.19	3.62±0.25
Hemoglobin(g/dL)	9.95±0.52	10.05±0.47	10.46±0.51	10.36±0.40	9.81±0.56
MCV (fL)	63.14±0.7	62.24±1.45	62.07±1.16	62.78±1.17	61.9±0.92
MCH (pg)	16.8±0.60	16.88±1.02	16.76±0.77	16.71±0.86	17.42±0.59
MCHC (g/dL)	31.76±0.5	31.69±0.66	33.29±1.2	32.25±0.59	32.18±0.83
PCV (%)	32.32±0.9	32.31±1.55	32.44±0.86	31.79±0.9	32.25±1.23

Histopathological analysis

Histopathological studies on liver section (Figure.1) showed no significant pathological alteration. The section of kidney and spleen (Figure. 2 and Figure. 3) also didn't show detectable morphological changes in the animals of all the groups as compared with the control group.

Figure 1: Histopathological analysis of liver sections, Figure 2: Histopathological analysis of kidney sections, Figure 3: Histopathological analysis of spleen sections of mice treated with methanolic and aqueous extracts of *Amorphophallus commutatus* var. *wayanadensis*.

(A) Normal control; (B) Methanolic extract 200 mg/kg b.w.; (C) Methanolic extract 400 mg/kg b.w.; (D) Aqueous extract 200 mg/kg b.w.; (E) Aqueous extract 400 mg/kg b.w.



DISCUSSION

Traditional medicinal system is an empirical approach of practice which requires scientific evidence and toxicity profiling for building bridges between alternative and western medicinal systems. *Amorphophallus commutatus* var. *wayanadensis* is a recently identified variety of *Amorphophallus* species from the hilly region of Western Ghats [5]. The tribal communities' native of Wayanad districts use corns of this particular species in various traditional cuisine and for various ailments like piles, tumors and scabies. Also a corn of *A. commutatus* is used in various Ayurvedic preparations like kashayams and rasayanams. Previous reports from our lab showed promising anti-bacterial activity of *A. commutatus* against Gram

negative organisms which found to be more efficacious than the standard erythromycin [8]. Our laboratory in collaboration with ayurvedic research centres has initiated for the development of external formulation of hemorrhoids from *A. commutatus*. Even though it has potential bioactivity and also widely used in various traditional medicinal systems, there are no studies done so far to evaluate the toxicity profile of the plant. Hence the present work to evaluate the toxicity profile of *Amorphophallus commutatus* var. *wayanadensis* by acute and sub-acute toxicity studies are essential for its safe and long term use in traditional medicine.

The phytochemical analysis of the methanolic extract confirmed the presence of phenolics, flavanoids, tannins, terpenoids, steroids, glycosides and fatty acids while aqueous extract showed the presence of reducing sugars, carbohydrates, glycosides and saponins. Alkaloids were found to be absent in both the extracts. Fatty acids and phenolic compounds found to be the major phyto-constituents in the methanolic extract of *A. commutatus*. These compounds are already reported for wide range of pharmacological applications [32, 33, 34, 35]. The presence of these metabolites might be attributing to the ethano-botanical application of the plant among the tribal communities.

In the acute toxicity studies, the experimental animals treated with methanolic and aqueous extracts of *A. commutatus* at the concentration 1000 and 2000 mg/kg b.w. did not show any behavioral changes and mortality. According to OECD guideline for acute oral toxicity LD50 dosage of 2000 mg/kg b.w. or above is considered as safe [36]. Hence the methanolic and aqueous extracts of *A. commutatus* found to be safe up to the dosage of 2000 mg/kg b.w. The experimental groups did not show any significant difference in the body weight regardless of the dosage used for the study. The acute toxicity study did not alter the food and water consumption by the animals during the study period [37]. The result of acute toxicity studies suggests that the methanolic and aqueous extracts of the plant when administered orally has very low toxicity profile.

In the sub-acute toxicity studies, the experimental animals did not show any mortality during the 28 days of treatment period and also no significant variation in the body weight compared to the control group. Variation in the relative organ weight of animals is a major indication of toxicity [38, 39]. The experimental groups treated with various concentrations of methanolic and aqueous extracts did not show any significant changes in the relative organ weight of vital organs like liver, kidney and spleen. Circulatory system is one among the major physiological systems involved in the transport of compounds towards the targeted site. Hence variation in the hematological parameters is considered as a major index for evaluating the toxicity of compounds [40]. Administration of methanolic and aqueous extracts by the experimental groups did not alter the hematological parameters like hemoglobin, red blood cells,

platelets and leucocytes count compared to the control group. Serum biochemical analysis is another major index for toxicological profiling because variation in serum parameters directly correlates to the hepatic and kidney damage [41, 42]. Creatinine, urea, total cholesterol and uric acid are considered as major markers of kidney damage [17, 43]. Oral administration of methanolic and aqueous extracts of *A. commutatus* did not alter the levels of kidney biomarkers. Histopathological results of kidney confirm the biochemical results. Serum enzymes are considered as major index for internal organ damage. Alanine aminotransferase are major indicator of hepatic injury. These enzymes are usually present in the hepatic cells, when hepatic injuries occur these enzymes leak out from the cells into the blood stream leading to elevated levels in serum [44] which indicate liver damage. Aspartate transaminase is present in various internal organs like liver, kidney, skeleton, pancreas and heart, hence increase in AST indicate severe damage to internal organs [45]. Alkaline phosphatase is a major enzyme involved in the removal of phosphate group. The elevated levels of ALP indicate damage of liver, gall bladder and pancreas [46]. The administration of repeated dose of extracts did not show any remarkable variation in the serum enzymes indicates that the extracts are non-toxic to internal organs for the dosage of 200 and 400 mg/kg b.w. Elevated levels of serum bilirubin refer to hepatic injury, excessive hemolysis and obstructed bile secretion. The extracts did not change the total and direct bilirubin levels in the serum and it inferred that methanolic and aqueous extracts does not have any toxic effect on hepatic cells and biliary secretions [47]. Sodium and potassium are two principle ions in body fluids [48]. Sodium plays a central role in regulating body fluid balance and distribution of fluids between intracellular and extracellular compartments [49]. Potassium is essential for normal growth, cellular metabolism and enzymatic reactions. During pathological conditions the levels of sodium and potassium get altered [50]. Calcium present in physiological fluids play major role in various biological processes like muscle contraction, hormonal responses, blood clotting, intracellular communication and growth. High level of calcium in blood is an indication of chronic renal failure in which kidney does not allow escape of calcium from blood to urine which shows high calcium levels in blood [51]. There were no significant variation in levels of electrolyte like potassium, sodium and calcium in the serum of extracts treated group compared to the vehicle control group. After 28 days of sub-acute toxicity studies by oral administration of methanolic and aqueous extracts of *A. commutatus* did not alter the levels of total protein, glucose and albumin compared to the control animals. Histopathological analysis of liver and spleen also did not show any morphological alteration in the cellular structures. Biochemical and histopathological results confirm that methanolic and aqueous extracts of *Amorphophallus commutatus* var. *wayanadensis* did not induce any toxicity to the experimental group compared to the control group.

In conclusion, *Amorphophallus commutatus* var. *wayanadensis* is a potential unexplored medicinal plants used by the traditional medicinal healers of Wayanad, India for the treatment of external inflammation and inflammation-related diseases likes piles, cysts and tumors. Evaluation of the toxicity index by acute and sub-acute toxicity studies on the methanolic and aqueous extracts of *A. commutatus* did not show any adverse toxicological effects on swiss albino mice up to 2000 mg/kg b.w. which suggests that the methanolic and aqueous extracts are safe for therapeutic purpose with a wide safety dosage profile. The hematological, biochemical and histopathological results of sub-acute toxicity studies also concluded that the extracts are safe with a NOAEL (No observed adverse effect level) proposed to be above 400 mg/kg body weight by oral administration. The present study confirms that methanolic and aqueous extracts of *Amorphophallus commutatus* var. *wayanadensis* is safe for the tested dosage and route of administration, which signify its traditional application and also pay way for further studies to evaluate the pharmacological potential of this vulnerable medicinal plant.

ACKNOWLEDGEMENTS

The authors are thankful to the authorities of the VIT University for providing the required facilities and financial assistance for the research work.

CONFLICT OF INTEREST

The authors declare that there are no conflicts of interest.

REFERENCES

- Jain A, Katewa SS, Galav PK, Sharma P. Medicinal plant diversity of Sitamata wildlife sanctuary, Rajasthan, India. J Ethnopharmacol 2005; 102: 143-57.
- Jagtap SD, Deokule SS, Bhosle SV. Ethnobotanical uses of endemic and RET plants by Parwa tribe of Nandurbar district, Maharashtra. Indian J Tradit Knowl 2008; 7: 311-5.
- Leena SSK. Traditional Uses of Plants as Cooling Agents by the Tribal and Traditional Communities of Dang Region in Rajasthan, India. Ethnobot Leaflets 2010; 14: 218-24.
- Jadhav VD, Mahadkar SD, Valvi SR. Documentation and ethnobotanical survey of wild edible plants from Kolhapur district. Recent Res Sci Technol 2011; 3(12): 58-63.
- Sivadasan M, Jaleel VA. Two new varieties of *Amorphophallus commutatus* (Schott) Engl. (Araceae) from India. Rheedea 2002; 12: 155-7.
- Ravikumar K, Ved DK, Vijaya SR, Udayan PS, FRLHT. Illustrated Field Guide- 100 Redlisted medicinal plants of conservation concern in Southern India, first ed. FRLHT, Bangalore, India; 2004.
- Ved DK, Goraya GS. Diversity of Herbal Raw Drugs and Plant Species in Trade. ENVIS Newsletter Med Plants 2008; 2: 4-6.
- Arjun RK, Asis S, Abdul JV, Sreena R, Karthikeyan S, Gothandam KM. Morphological, phytochemical, and anti-bacterial properties of wild and indigenous plant *Amorphophallus commutatus*. J Med Plants Res 2013; 7: 744-8.
- Lampe KF, McCann MA. AMA Handbook of Poisonous and Injurious Plants. Chicago. 1985.
- World Health Organization. "WHO Traditional Medicine Strategy 2002-2005," 2002.
- Fursule RA, Patil SD. Hepatoprotective and antioxidant activity of *Phaseolus trilobus*, Ait on bile duct ligation induced liver fibrosis in rats. J Ethnopharmacol 2010; 129: 416-9.
- Harborne JB. Phytochemical Methods: A Guide to Modern Techniques of Plant Analysis. Chapman and Hall, London, UK. 1984.
- Trease GE, Evans WC. Pharmacognosy. 15th Ed. London: Saunders Publishers. 2002.
- Singleton VL, Rossi JA. Colorimetry of total phenolics with phosphomolybdic acid-phosphotungstic acid reagents. Amer J Enology Viticulture 1965; 16: 144-58.
- Park YS, Jung ST, Kang SG, Heo BK, Arancibia AP, Toledo F, Drzewiecki J, Namiesnik J, Gorinstein S. Antioxidants and proteins in ethylene-treated kiwifruits. Food Chem 2008; 17: 640-8.
- OECD. OECD Guideline for Testing of Chemicals, No. 420, Acute Oral Toxicity -Fixed Dose Procedure. Adopted 17th December 2001. Organization for Economic Cooperation and Development, Paris. 2001.
- Adel T, Zafar HI, Badiâa L. Acute and sub-chronic toxicity of a lyophilised aqueous extract of *Centaureum erythraea* in rodents. J Ethnopharmacol 2010; 132: 48-55.
- Sathya M, Kokilavani R, Ananta Teepa KS. Acute and subacute toxicity studies of ethanolic extract of *Acalypha indica* Linn in male wistar albino rats. Asian J Pharm Clin Res 2012; 5: 97-100.
- Gireesh KS, Vikas K. Acute and sub-chronic toxicity study of standardized extract of *Fumaria indica* in rodents. J Ethnopharmacol 2011; 134: 992-5.
- OECD. OECD Guideline for Testing of Chemicals. No.407. Repeated Dose 28- Day Oral Toxicity Study in Rodents. Adopted 3rd October 2008."Organization for Economic Cooperation and Development, Paris. 2008.
- Velpandian V., Ashwini A, Anbu J, Prema S. Acute and subacute

- toxicity studies of Kodi Pavala Chunnam in rodents. Asian J Pharm Clin Res 2012; 5: 36-41.
22. Satheesh KB, Sharmila, KP, Suchetha KN, Vadisha BS. Acute and subacute toxicity study of the ethanolic extracts of *Punica granatum* (Linn). whole fruit and seeds and synthetic ellagic acids in swiss albino mice. Asian J Pharm Clin Res 2013; 6: 192-8.
 23. Zhou W, Ai Qin Z, Fumiko T, Ryo O, Yicong L, Yuka H, Shizheng W, Hiroshi N. Brazilian Green Propolis Suppresses the Hypoxia-Induced Neuroinflammatory Responses by Inhibiting NF- κ B Activation in Microglia. Oxid Med Cell Longev 2013; 1-10.
 24. Alexis V, Adyary Fallarero, Blanca RP, Maria EM. Bienvenido Gra, Felicia Rivera, Yamilet Gutierrez, Pia MV. Studies on the toxicity of *Punica granatum* L. (Punicaceae) whole fruit extracts. J Ethnopharmacol 2003; 89: 295-300.
 25. Adeneye AA, Ajagbonna OP, Adeleke TI, Bello SO. Preliminary toxicity and phytochemical studies of the stem bark aqueous extract of *Musanga cecropioides* in rats. J Ethnopharmacol 2006; 105: 374-9.
 26. Batomayena B, Benedicte B, Kwashie Eklu-Gadegbeku, Amegnon A, Kodjo A, Messanvi G, Edmond EC, Nicholas M. Acute and sub-chronic (28 days) oral toxicity evaluation of hydroethanolic extract of *Bridelia ferruginea* Benth root bark in male rodent animals. Food Chem Toxicol 2013; 52: 176-9.
 27. Demma J, Gebre-Mariam T, Asres K, Evgetie W, Engindawork E. Toxicological study on *Glinuslotoides*: a traditionally used technical herb in ethiopia. J Ethnopharmacol 2006; 111: 451-7.
 28. Tan PV, Mezui C, Enow-Orock G, Njikam N, Dimo T, Bitolog P. Teratogenic effects, acute and sub chronic toxicity of the leaf aqueous extract of *Ocimum suave* Wild (Lamiaceae) in rats. J Ethnopharmacol 2008; 115: 232-7.
 29. Anurag P, Manu Chaudhary, Anupama Tamta, Vivek KD. Sub-Acute Toxicity Study of Etimicin Sulphate in Wistar Rat. Int. J. Pharma. Sci. Drug Res 2010; 2: 120-2.
 30. Singh A, Dubey SD, Patne S, Kumar V. Acute and sub-chronic toxicity study of calcium based ayurvedic 'Bhasmas' and a 'Pishti' prepared from marine-sourced animals. J Herbal Med Toxicol 2010; 4: 35-47.
 31. Preeja G, Pillai PS, Gayatri A, Gaurav D, Vidhi B. X. Pharmacognostical standardization and toxicity profile of the methanolic leaf extract of *Plectranthus amboinicus* (Lour) Spreng. J Appl Pharm Sci 2010; 1(2): 75-81.
 32. Aneta Wojdylo, Jan Oszmianski, Renata Czemerzys. Antioxidant activity and phenolic compounds in 32 selected herbs. Food Chem 2007; 105: 940-9.
 33. Pereira AP, Ferreira IC, Marcelino F, Valentao P, Andrade PB, Seabra R, Estevinho L, Bento A, Pereira JA. Phenolic compounds and antimicrobial activity of olive (*Olea europaea* L. Cv. Cobrançosa) leaves. Molecules 2007; 12: 1153-62.
 34. Suheyli K, Nazli B, Huseyin S, Suleyman GR, Nazli A. Essential fatty acid components and antioxidant activities of eight *Cephalaria* species from southwestern Anatolia. Pure Appl Chem 2007; 79: 2297-304.
 35. McAnulty SR, Nieman DC, Fox-Rabinovich M, Duran V, McAnulty LS, Henson DA, Jin F, Landram MJ. Effect of n-3 fatty acids and antioxidants on oxidative stress after exercise. Med Sci Sports Exerc 2010; 42:1704-11.
 36. Chandrashekar J, Sanmuga PE, Subramanian V. Acute and subacute toxicity studies on the Poly herbal antidiabetic formulation Diakyur in experimental animal models. J Health Sci 2007; 53: 245-9.
 37. Mukinda JT, Syce JA. Acute and chronic toxicity of the aqueous extract of *Artemisia afra* in Rodent. J Ethnopharmacol 2007; 111: 138-44.
 38. Albert DA, Telesphore BN, Jacques YD, Albert K. Acute and subchronic oral toxicity assessment of the aqueous extract from the stem bark of *Erythrina senegalensis* DC (Fabaceae) in rodents. J Ethnopharmacol 2011; 134: 697-702.
 39. Feres CAO, Madalosso RC, Rocha OA, Leite JPV, Guimaraes TMDP, Toledo VPP, Tagliati CA. Acute and chronic toxicological studies of *Dimorphandra mollis* in experimental animals. J Ethnopharmacol 2006; 108(3): 450-6.
 40. Hedrich H. The Laboratory Mouse. Hematology of the mouse. B. Gillian, and Peter Petrusz. London, Elsevier Academic press. 2004; 271-86.
 41. Corns CM. Herbal remedies and clinical biochemistry. Ann Clin Biochem 2003; 40: 489-507.
 42. Obici S, Otobone FJ, da Silva Sela VR, Ishida K, da Silva JC, Nakamura CV. Preliminary toxicity study of dichloromethane extract of *Kielmeyera coriacea* stems in mice and rats. J Ethnopharmacol 2008; 115: 131-9.
 43. Lin HM, Yen FL, Ng LT, Lin CC. Protective effects of *Lingustrum lucidum* fruit extract on acute butylated hydroxytoluene-induced oxidative stress in rats. J Ethnopharmacol 2007; 111: 129-36.
 44. Ishwer K, Mohd AK, Yusufuddin I, Goud AV. Hepatoprotective potential of ethanolic and aqueous extract of flowers of *Sesbania grandiflora* (Linn) induced by CCl₄. Asian Pac J Trop Biomed 2012; 2: S670-9.
 45. Aniagu SO, Nwinyi FC, Olanubi B, Akumka DD, Ajoku GA, Izebe KS, Agala P, Agbani, EO, Enwerem NM, Iheagwara C, Gamaniel KS. Is *Berlina grandiflora* (Leguminosae) toxic in rats? Phytomedicine 2004; 11: 352-60.
 46. James MP, John Short, Albert IL. Irving Lieberman. Function and Control of Liver Alkaline Phosphatase. J Biol Chem 1972; 247: 1767-74.
 47. Wonder KMA, George KA, Eric Boakye Gyasi. Acute and Sub-acute Toxicity Studies of the Ethanolic Extract of the Aerial Parts of *Hillieria latifolia* (Lam.) H. Walt. (Phytolaccaceae) in Rodents. West African J Pharm 2011; 22: 27-35.
 48. Cohen AJ, Roe FJ. Evaluation of the Aetiological Role of Dietary Salt Exposure in Gastric and Other Cancers in Humans. Food Chem Toxicol 1997; 35: 271-93.
 49. Palmer BF, Robert JA, Donald WS. Physiology and Pathophysiology of Sodium Retention. In The Kidney: Physiology and Pathophysiology. W. Donald, Seldin, and Gerhard Giebisch., Philadelphia, Lippincott Williams and Wilkins, II: 2000; 1473-517.
 50. Rodriguez-Soriano J. Potassium Homeostasis and Its Disturbance in Children. Pediatr Nephrol 1995; 9: 364-74.
 51. Lafferty FW. Differential diagnosis of hypercalcemia. J Bone Miner Res 1991; 6 Suppl 2: S51-9.