

WOUND HEALING ACTIVITY OF *BARRINGTONIA ACUTANGULA* FRUIT EXTRACT

ARNABADITYA MOHANTY*, PAL A, SAHU PK

Department of Pharmacology, School of Pharmaceutical Sciences, Siksha O Anusandhan University, Bhubaneswar, Odisha, India.

Email: marnabaditya@gmail.com

Received: 31 December 2015, Revised and Accepted: 27 January 2016

ABSTRACT

Objective: To evaluate wound healing activity of methanolic extract of *Barringtonia acutangula* fruits (MEBA).**Methods:** Both excision and incision models were used in rats. In the excision wound model, the wound area of each animal was measured on days 0, 2, 4, 6, 8, 10, 12, and 14 after inflicting the wound. Wound contraction (WC) was calculated as a percentage change in the initial wound size. The histopathology study of the skin (newly formed on the wounds) was carried out on the 12th post wounding day. In the incision wound model, the tensile strength was measured using tensiometer on the 14th post wounding day.**Results:** MEBA at 20% w/w showed highly significant wound healing activity ($p < 0.01$) as compared to control. The percentage of WC on the 14th day by MEBA at 5%, 10%, and 20% w/w were found to be 93.86%, 93.86%, and 96.43%, respectively. There is increased the number of fibroblasts, increased collagen tissue and complete epithelialization in the case of MEBA ointment 20% w/w.**Conclusion:** MEBA fruit (ointment) showed significant wound healing activity in both excised wound model (20% w/w) and incision wound model (10% w/w) rats.**Keywords:** Barringtonia, Wound healing, Excision, Incision.

INTRODUCTION

Barringtonia acutangula belongs to the family Barringtoniaceae [1]. It is mostly found common in Meghalaya, Assam, West Bengal, Bihar, Odisha, Madhya Pradesh, and Deccan peninsula, Bangladesh, Myanmar, and Sri Lanka [2]. Fruits are 3.2-3.8 by 1.3-2 cm, bluntly quadrangular, broadest in the middle, slightly narrowed toward and truncate at each end, crowned by the small persistent calyx [3].

Aqueous extract of fruit at a dose of 400 mg/kg significantly decreases blood glucose levels in streptozotocin-induced hyperglycemic rats [4]. The ethanolic fruit extract shows anti-inflammatory property [5]. Traditionally, fruit is used in diseases of the blood, bronchitis, sore eyes, headache, hallucinations, abdominal colic, syphilis, nasal catarrh, wound, ulcer, leprosy, cough, dysmenorrhea, etc. [1,3,6]. However, thorough literature survey reveals that there is no scientific report on wound healing activity of *B. acutangula*. So, the present study is an attempt to evaluate wound healing activity of methanolic extract of its fruit.

METHODS

Collection and preparation of plant extract

The plant material for the proposed study was collected from a local area of Barpali (Dist-Bargarh, Odisha). The fruit was dried under shade and powdered by the help of mechanical process. The shade dried coarse powder of fruit (100 g) was subjected to continuous hot extraction with solvent petroleum ether and methanol successively by a Soxhlet apparatus for 16-18 hrs. The solvent was removed under pressure, and the extracts were concentrated under vacuum at 40-60°C [7].

Preparation of ointment

A simple ointment containing the methanol extract of the fruit of *B. acutangula* was prepared by trituration method in a ceramic mortar and pestle using white soft paraffin ointment base. The batches of the ointment containing 5%, 10%, and 20% w/w of methanol extract were prepared for the study. Povidone-iodine ointment (5% w/w) was used as the standard drug for comparing the wound healing potential of the extract in the different animal model [8].

Animals

Albino rats (Wistar strain) of either sex (150-200 g) were obtained from School of Pharmaceutical Sciences, Bhubaneswar. The study protocol was approved by the Institutional Animal Ethics Committee (Registration No.1171/C/08/CPCSEA).

The animals were kept under controlled environmental conditions at 25±2°C temperature and 45-55% relative humidity with natural light/dark cycle and allowed free access to food (Standard Pellet Diet, Hindustan Lever Ltd., India) and water. They were acclimatized for at least a week before the commencement of the experiment.

Treatment protocol

The animals were depilated and wounded under light ether anesthesia, semi-aseptically. Then, they were divided into five groups of six animals each and treated as follows:

Group I: Simple ointment base was applied and served as control.

Group II: Povidone-iodine ointment (5% w/w).

Group III: 5% w/w methanolic extract of *B. acutangula* (MEBA) ointment.

Group IV: 10% w/w MEBA ointment.

Group V: 20% w/w MEBA ointment.

Wound healing study

Screening for wound healing activity was performed by excision wound model and incision wound model without infection. All the test sample and standard drug were applied topically.

Excision wound model

Each animal was anesthetized by open mask method with mild anesthetic ether. The rats were depilated on the back and a predetermined area of 500 mm² full thickness skin was excised in the dorsal interscapular region. The areas of the wounds were measured (sq.mm) immediately placing a transparent polyethylene graph paper over the wound and then tracing the area of the wound on it. This was taken as the initial wound area reading. All the test samples were applied once daily. The wound area of each animal was measured on days 0, 2, 4, 6, 8, 10, 12, and 14 after inflicting the wound. Wound

Table 1: Effect of MEBA in excision wound

Treatment	Wound area in mm ² mean±SEM							
	0 day	2 nd day	4 th day	6 th day	8 th day	10 th day	12 th day	14 th day
Control	491.66±3.33	443.83±10.99	383.66±9.87	267.33±15.03	144.83±16.44	82.16±9.06	59.83±5.34	52.83±8.46
Povidone iodine 5% w/w	489.33±2.91	446.83±8.15	374.66±12.44	299.16±16.07	190.16±19.34	115.66±6.66*	34.16±5.13*	24.50±5.24*
5% w/w MEBA	486.33±3.15	440.33±9.36	354.16±18.34	295.50±18.22	216.66±14.29*	122.16±6.19**	37.50±3.19*	29.83±2.86*
10% w/w MEBA	491.50±1.80	459.66±7.56	402.16±14.14	333.33±10.52*	228.33±4.5**	137.16±5.51**	41.33±3.09	30.16±3.50*
20% w/w MEBA	491.00±2.30	445.33±4.82	370.83±11.45	269.50±21.78	200.33±10.10*	125.66±5.61**	37.16±3.96*	17.50±3.06**

n=6; p value: *p<0.05, **p<0.01 values are expressed as mean±SEM. One-way ANOVA followed by Dunnett's t-test, all the groups are compared with control. MEBA: Methanolic extract of *Barringtonia acutangula*, SEM: Standard error of mean

contraction (WC) was calculated as a percentage change in the initial wound size [9].

$$\% \text{ of WC} = \frac{\text{Initial wound size} - \text{specific day wound size}}{\text{Initial wound size}} \times 100$$

Incision wound model

The animals were anesthetized under light ether anesthesia. One full thickness paravertebral incision of 1.5 cm length was made including the cutaneous muscles depilated back of each rat. After the incision, the parted skin was kept together and stitched with black silk at both the end of the created wounds. The test sample was applied in a similar manner as in excision wound model [10].

Determination of tensile strength

The tensile strength of wound represents the effectiveness of wound healing. Usually, wound healing agents promote the gaining of tensile strength. Tensile strength (the force required to open the healing skin) is used to measure the completeness of the healing. The tensile strength was measured using tensiometer on the 14 post wounding day [11].

Histopathology

The histopathology study of the skin (newly formed on the wounds) was carried out on the 12th post wounding day by fixing the skin in 10% formalin. Paraffin sections (5-10 μ) were prepared stained with hematoxylin and eosin and finally mounted in di-n-butyle phthalate in xylene medium. Histopathological examination was performed to study the process of epithelialization on the excised wound and to find out evidence of granuloma, dysplasia, edema, and malignancy in the skin under examination [12].

Statistical analysis

The means of wound area measurement and wound breaking strength of all the groups were compared with control at different time intervals were compared by one-way ANOVA followed by the Dunnett's t-test [13].

RESULTS

MEBA at 20% w/w showed highly significant wound healing activity (p<0.01) as compared to control (Table 1). There is significant and faster rate of wound closure and reduced epithelialization period.

In incision wound model, there is a significant increase in skin tensile strength (p<0.01) by 10% w/w and 20% w/w ointment of MEBA and standard as compared to control group animals (Table 2).

In histopathological studies of granulation tissue, there is increased number of fibroblasts, increased collagen tissue, and complete epithelialization in case of povidone iodine 5% w/w and MEBA ointment 20% w/w but in 5% w/w and 10% w/w MEBA mild healing was observed as compared to control group (Fig. 1a-e).

DISCUSSION

In our study using wound healing model, there is a significant increase in wound healing activity by MEBA fruits in treated rats. There are three

Table 2: Effect of MEBA on tensile strength of incised wound in rats

Groups/treatment	Tensile strength (g/cm ²), mean±SEM
Group I (solvent control)	97.50±15.15
Group II (standard)	222.50±15.41**
Group III (MEBA 5% w/w)	120.33±5.22
Group IV (MEBA 10% w/w)	204.83±9.18**
Group V (MEBA 20% w/w)	234.16±11.13**

n=6; p value: *p<0.05, **p<0.01 values are expressed as mean±SEM. One-way ANOVA followed by Dunnett's t-test, all the groups are compared with control. MEBA: Methanolic extract of *Barringtonia acutangula*, SEM: Standard error of mean

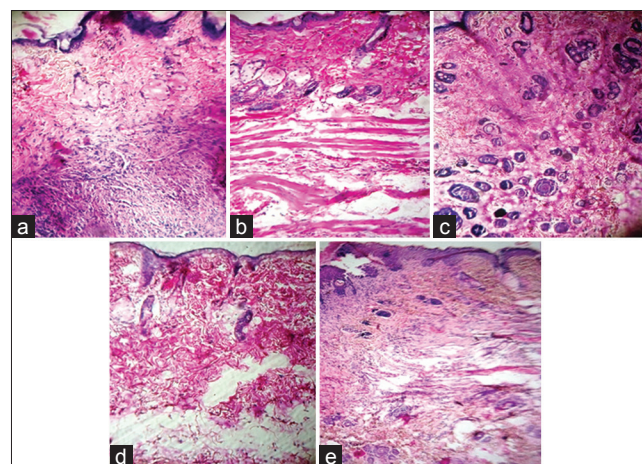


Fig. 1: (a) Solvent control - Wounded area skin shows ulcer with inflammation exudate. Mild increase in fibrous tissue as well as granulation tissue and congested blood vessels, (b) positive control - Increase in fibrous tissues, collagen. Inflammatory cells are not present. The intact portion of the skin reveals normal histology of skin, (c) methanolic extract of *Barringtonia acutangula* (MEBA) 5% w/w - Incomplete formation of epithelial cells, fibrous tissues are not fully formed and mild edema with lymphoid cells, (d) MEBA 10% w/w - Incomplete formation of epithelial cells and fibrous tissue as well as fibroblast arranged in irregular manner, (e) MEBA 20% w/w - Formation of epithelial layer, collagen. Fibrous tissues are completely intact. Normal histology of skin

stages of wound healing, i.e. inflammation, proliferation, and remodeling. There are reports of anti-inflammatory activity of *B. acutangula* [5]. The proliferative phase of wound healing demonstrates angiogenesis, collagen deposition, granulation tissue formation, epithelialization, and WC [14]. Since MEBA 20% w/w ointment increases the number of fibroblasts, collagen tissue and causes complete epithelialization, MEBA may have a significant effect on the proliferative phase of wound healing.

Similar types of wound healing activity were reported for *Datura alba*, *Pterocarpus santalinus*, and *Terminalia chebula* [15-17]. The results of

this investigation provide pharmacological evidence on the folkloric use of *B. acutangula* for wound healing. Preliminary phytochemical screening of MEBA showed the presence of alkaloid, saponin, and polysaccharides. There are reports of the presence of saponins, tannins, and terpenoids in *B. acutangula* fruits [4]. So, the wound healing activity of MEBA may be attributed to such compounds.

CONCLUSION

MEBA fruit (ointment) showed significant wound healing activity in both excised wound model (20% w/w) and incision wound model (10% w/w) rats. Further study is needed to find out the phytoconstituents responsible for the observed effect.

REFERENCES

- Nadkarni KM. Indian Materia Medica. Vol. 1. Mumbai, India: Popular Prakashan Ltd.; 1954. p. 176-7.
- Guha Bakshi DN. A Lexicon of Medicinal Plants of India. Vol. 1. Bidhan Sarani, Calcutta: Naya Prakash; 1999. p. 243-4.
- Kirtikar KR, Basu BD. Indian Medicinal Plants. 2nd ed., Vol. IV. Allahabad: Lalit Mohan Basu; 1999. p. 1058-9.
- Khatib NA. Evaluation of hypoglycemic activity of *Barringtonia acutangula* fruit extracts in streptozotocin induced hyperglycemic wistar rats. J Cell Tissue Res 2011;11:2573-8.
- Muralidhar A. Anti-inflammatory studies of *Barringtonia acutangula* (Linn) fruits on wistar rats. Int J Phytomed 2013;5(3):350-5.
- Joshi SG. Medicinal Plants. New Delhi: Oxford and IBH Publication; 2003. p. 237-8.
- Harborne JB. In: Jackman H, editor. Phytochemical Methods. London: Springer; 1973. p. 70.
- Sunilson AJ, Venkatanarayan R. Wound healing activity of *Jasminum sambac* leaf extract. Adv Pharmacol Toxicol 2004;5:1-10.
- Morton JJ, Malone MH. Evaluation of vulnerary activity by an open wound procedure in rats. Arch Int Pharmacodyn Ther 1972;196(1):117-26.
- Ehrlich HP, Hunt TK. Healing potential of some natural agents. J Ann Surg 1969;170:203-5.
- Lee KH, Krei CH. Efficacy of some natural agents on dermal wounds. J Pharm Sci 1968;57:102-4.
- Kar DM, Dash GK. Antimicrobial and wound healing properties of stem bark of *Toddalia asiatica*. Indian J Pharm Soc 2005;67:220-3.
- Kulkarni SK. Handbook of Experimental Pharmacology. 3rd ed. Delhi: Vallabh Prakashan; 1999. p. 178-80.
- Greenhalgh DG. Wound healing and diabetes mellitus. Clin Plast Surg 2003;30(1):37-45.
- Priya KS, Gnanamani A, Radhakrishnan N, Babu M. Healing potential of *Datura alba* on burn wounds in albino rats. J Ethnopharmacol 2002;83(3):193-9.
- Biswas TK, Maity LN, Mukherjee B. Wound healing potential of *Pterocarpus santalinus* Linn: A pharmacological evaluation. Int J Low Extrem Wounds 2004;3(3):143-50.
- Chaudhari M, Mengi S. Evaluation of phytoconstituents of *Terminalia arjuna* for wound healing activity in rats. Phytother Res 2006;20(9):799-805.