

AMELIORATIVE EFFECTS OF MELATONIN AGAINST 2,4-DICHLOROPHENOXYACETIC ACID TOXICITY IN KIDNEY OF MICE – A HISTOLOGICAL STUDY

ASHLESH M UPADHYAYA, MANDAVA V RAO, DEVENDRASINH D JHALA*

Department of Zoology, Biomedical Technology and Human Genetics, University School of Sciences, Gujarat University, Ahmedabad - 380 009, Gujarat, India. Email: ddjhala@gmail.com

Received: 08 August 2017, Revised and Accepted: 27 September 2017

ABSTRACT

Objective: The compound, 2,4-dichlorophenoxyacetic acid (2,4-D), is a systemic phenoxy herbicide and a plant growth regulator. Histopathological effects of 2,4-D alone and in combination with melatonin on the kidney in adult albino male mice of the Swiss strain were evaluated in the present study.

Methods: Twenty adult male albino mice weighing between 30 and 40 g were assigned into four groups with five mice in each group. Group I served as control; Group II - melatonin alone (10 mg/kg body weight); Group III - 2,4-D alone (50 mg/kg body weight); and Group IV - 2,4-D + melatonin was given orally for 45 days.

Results: It revealed a significant reduction in the body and kidney weights ($p < 0.001$ and $p < 0.01$ respectively) of mice treated with 2,4-D, while the body and kidney weights after treatment of melatonin and 2,4-D + melatonin were comparable to control. Histological study revealed that 2,4-D induced nephrotoxicity evidenced by various histological changes including shrinkage of the glomerulus, tubular dilation, hypertrophy of tubular epithelium, and degeneration of renal tubules.

Conclusion: Treating animals with the melatonin along with 2,4-D showed mitigative effects of melatonin and minimized the structural alteration in the kidney of mice appeared due to 2,4-D toxicity.

Keywords: 2,4-dichlorophenoxyacetic acid, Histopathology, Melatonin, Mice, Mitigation, Nephrotoxicity.

© 2018 The Authors. Published by Innovare Academic Sciences Pvt Ltd. This is an open access article under the CC BY license (<http://creativecommons.org/licenses/by/4.0/>) DOI: <http://dx.doi.org/10.22159/ajpcr.2018.v11i1.21829>

INTRODUCTION

Pesticides have played a vital role in controlling agricultural, industrial, home, and public health pest worldwide [1,2]. However, their use poses animal and human health concerns because of their toxicity, widespread use, and release into the environment [3,4]. According to the World Health Organization, 3 million cases of pesticide poisoning occur every year, resulting in more than 250,000 deaths [5]. 2,4-dichlorophenoxyacetic acid (2,4-D) is a systemic phenoxy herbicide developed in the 1940s and still in use today [1]. There are over 1500 pesticide/herbicide products containing 2,4-D as the main ingredient [6].

Human and other living organisms are exposed to 2,4-D in many ways: By breathing contaminated air, drinking and bathing in contaminated water, contacting contaminated soil, eating contaminated food, ingesting contaminated dust, and while working with 2,4-D. While each kind of exposure may involve small amounts of 2,4-D, their cumulative effect poses a serious concern. In toxicity tests, significant adverse effects were noted in the blood [7] and kidneys [8-10]. 2,4-D toxicity in peripheral blood mononuclear cells is associated with significant oxidative properties of this compound, which is responsible for cell death mostly through the induction of apoptosis [7]. 2,4-D treatment showed a fair degree of derangement of renal functions with concomitant changes in the histological structure of the kidney [8-10]. Moreover, the increment in plasma urea and creatinine levels and the reduction of uric acid in plasma along with histopathological alterations of 2,4-D-treated rats reported by Tayeb *et al.* [8] also supported the impairment of renal functions. Teratogenic [11-13], genotoxic [14], neurotoxic [2,15-17], immunosuppressive [18], cytotoxic [19-20], and hepatotoxic [21-23] effects of 2,4-D have also been well documented.

Melatonin (N-acetyl-5-methoxytryptamine) is a secretory product of the pineal gland and a tryptophan-derived molecule with pleiotropic activities. The discovery of melatonin as an antioxidant was made in 1993 [24]. Numerous reports documented its antioxidant, anticancer, and free radical scavenging properties [25-27]. Melatonin as an antioxidant in cancer therapy, liver disease, pulmonary disease, and cardiovascular disease has been well described [28]. As a potent free radical scavenger, melatonin and its secondary and tertiary metabolites are able to neutralize numerous toxic oxygen derivatives. These metabolites are potent antioxidants against both reactive oxygen species and reactive nitrogen species [29].

The present study was conducted to evaluate protective effects of melatonin on the kidney histology against 2,4-D-induced toxicity.

METHODS

Chemicals

The herbicide, 2,4-D (CAS No. 94-75-7; Purity: $\geq 99.0\%$), was obtained from Loba Chemie, Mumbai, India. Melatonin (CAS No. 73-31-4; Purity: $\geq 99.0\%$) was obtained from HiMedia Laboratories, Mumbai, India. All chemicals utilized in hematoxylin and eosin staining were procured from Sigma-Aldrich (St. Louis, MO, USA), Merck (Darmstadt, Germany), and HiMedia Laboratories (Mumbai, India) (AR grade).

Experimental animals

Healthy, adult male albino mice of the Swiss strain weighing between 30 and 40 g obtained from Zyodus Cadila Pharmaceutical, Ahmedabad, Gujarat, India, were used for all experiments. Animals were kept in the Animal House of Zoology Department of Gujarat University, Ahmedabad, India, under controlled conditions (temperature $22 \pm 3^\circ\text{C}$, 12 h light/dark cycle, and relative humidity 50–55%). They were fed with

certified pelleted rodent feed supplied by Amrut Feeds, Pranav Agro Industries Ltd., Pune, India, and water *ad-libitum*. All the experimental protocols were approved by the Committee for the Purpose of Control and Supervision of Experiments on Animals (Reg-167/1999/CPCSEA), New Delhi, India. Animals were handled according to the guidelines published by the Indian National Science Academy, New Delhi, India (2000) [30].

Treatment

As shown in Table 1, 20 mice weighing between 30 and 40 g were divided into four groups with five mice in each group for 45-day treatment. Group I served as control; Group II was given oral administration of melatonin alone (10 mg/kg body weight), while Group III was given oral administration of 2,4-D (50 mg/kg body weight) and in Group IV 2,4-D along with melatonin was given at the same dose level as those in Group III and II, respectively.

After completion of the 45-day treatment, on the 46th day, the body weight of each group of mice was recorded on an animal weighing balance (OHAUS, USA) to the nearest gram and sacrificed by cervical dislocation. The kidney was dissected out carefully, blotted free of blood, weighed to the nearest gram, and utilized to study the histopathology.

Histopathology

Histopathological studies were carried out using the standard technique of hematoxylin and eosin staining [31]. The fresh pieces of the kidney were fixed for 18 h in alcoholic Bouin's fixative. The tissue was dehydrated by passing through ascending grades of alcohol, cleared in xylene, and embedded in paraffin wax. About 5 μ m thick sections were cut on a rotary microtome and stained with Ehrlich's hematoxylin and eosin (alcohol soluble), dehydrated in alcohol, cleared in xylene, mounted in DPX, and examined microscopically.

Statistical analysis

All the data are expressed as the mean \pm standard error. Statistical analysis was performed using GraphPad Prism software version 5.03. The data were statistically analyzed using one-way analysis of variance followed by Tukey's test. The level of significance was accepted at $p < 0.05$.

RESULTS

Body and kidney weight

As shown in Table 2, a significant reduction in whole body weight ($p < 0.001$) and kidney weight ($p < 0.01$) in 2,4-D-treated mice was observed. Moreover, percent relative weights were also reduced. Melatonin administration ameliorated the adverse effect on the body ($p < 0.05$) and kidney ($p < 0.01$) weights significantly, and results were comparable to control, whereas melatonin alone had shown no effect.

Histopathology

Figs. 1-8 show transverse section of control and experimental groups of mice kidney with hematoxylin and eosin stain.

Histology of the kidney of control mice exhibited normal histoarchitecture. Melatonin alone group showed normal histoarchitecture

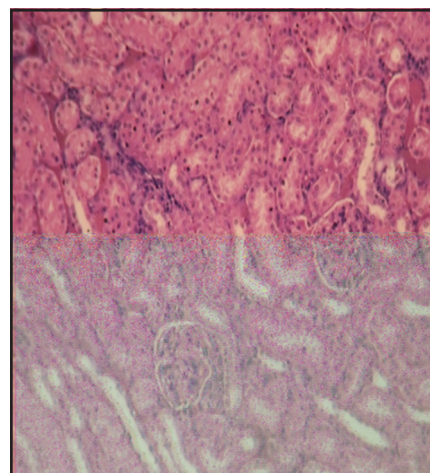


Fig. 1: Histology of control mice showed normal histoarchitecture ($\times 210$)

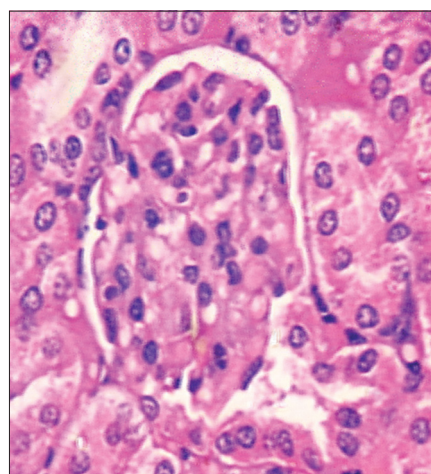


Fig. 2: Histology of control mice showed normal histoarchitecture ($\times 840$)

Table 1: Experimental groups

Groups	Treatment and dose	Duration	Day of autopsy	Number of animals used
I	Control (untreated)	45 days	46 th day	5
II	Melatonin alone (10 mg/kg body weight)	45 days	46 th day	5
III	2,4-D (50 mg/kg body weight)	45 days	46 th day	5
IV	2,4-D + melatonin	45 days	46 th day	5

2,4-D: 2,4-dichlorophenoxyacetic acid

Table 2: Effect of melatonin on 2,4-D-induced changes in the body and kidney weights of mice

Groups	Total body weight (g)	Relative body weight (%)	Kidney weight (g)	Relative kidney weight (%)
I - Control	38.60 \pm 1.43	100	0.75 \pm 0.06	100
II - Melatonin	40.00 \pm 1.55 ^{NS}	103.63	0.77 \pm 0.07 ^{NS}	102.67
III - 2,4-D	30.00 \pm 1.2**	77.72	0.42 \pm 0.02*	56
IV - 2,4-D + melatonin	35.20 \pm 0.37 ^{NS;#}	91.19	0.72 \pm 0.06 ^{NS;##}	96

Values are mean \pm SE, NS: Non-significant; * $p < 0.01$; ** $p < 0.001$ when Groups II to IV were compared with control (Group I); # $p < 0.05$; ## $p < 0.01$ when Group IV compared with Group III. 2,4-D: 2,4-dichlorophenoxyacetic acid, SE: Standard error

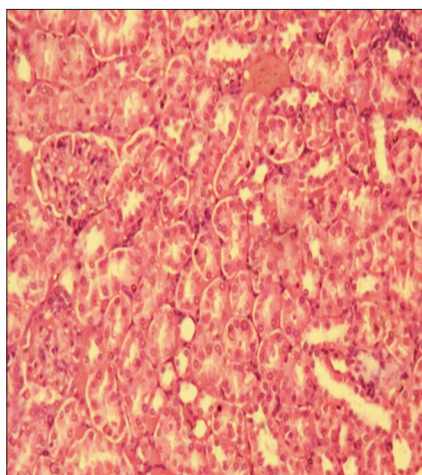


Fig. 3: Histology of melatonin treated mice showed normal histoarchitecture (×210)

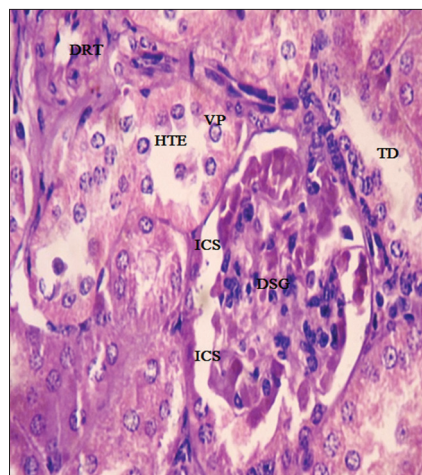


Fig. 6: Histology of 2,4-D treated mice exhibiting damaged and shrinkage of the glomerulus (DSG), increased capsular space (ICS), tubular dilation (TD), hypertrophy of tubular epithelium (HTE), degeneration of renal tubules (DRT), and vacuolization of proximal (VP) convoluted tubule (×840)

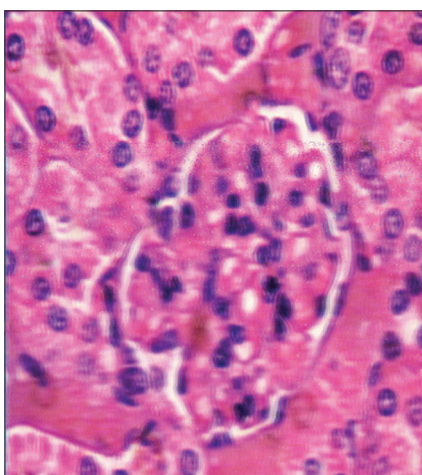


Fig. 4: Histology of melatonin treated mice showed normal histoarchitecture (×840)

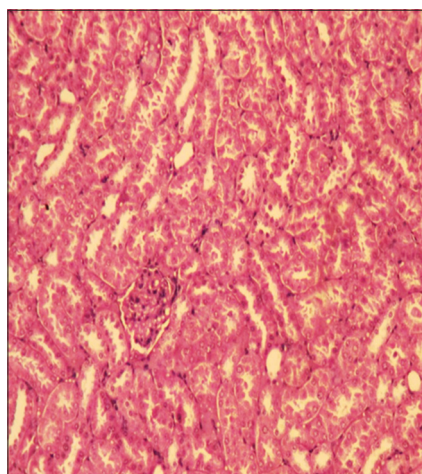


Fig. 7: Histology of 2,4-D + melatonin-treated mice showed the almost normal structure of the glomerulus and histoarchitecture were comparable to control (×210)

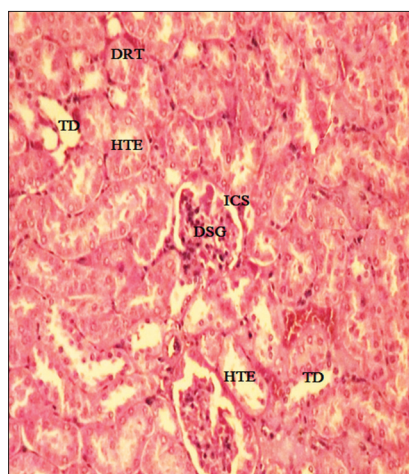


Fig. 5: Histology of 2,4-D treated mice exhibiting damaged and shrinkage of the glomerulus (DSG), increased capsular space (ICS), tubular dilation (TD), hypertrophy of tubular epithelium (HTE), degeneration of renal tubules (DRT), and vacuolization of proximal (VP) convoluted tubule (×210)

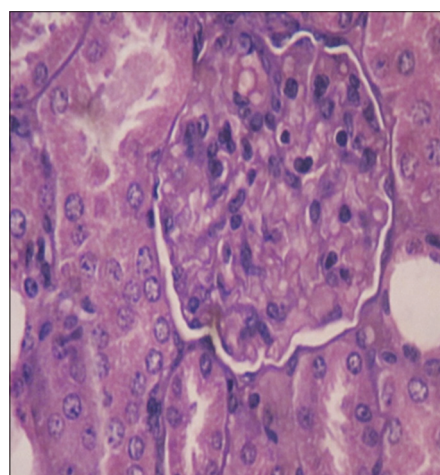


Fig. 8: Histology of 2,4-D + melatonin-treated mice showed the almost normal structure of the glomerulus and histoarchitecture were comparable to control (×840)

of the kidney as observed in the control group (Figs. 1-4). The 2,4-D-treated mice kidney revealed irregular organization of renal tubules with increased periglomerular space. Degenerative changes were also observed in the tubular epithelial cells. Animals had renal tubular necrosis and had degenerative changes in the glomerulus. The tubular endothelial cells exhibited abnormal morphology. The tubular lumen was also altered along with more extensive vacuolization of proximal convoluted tubule as compared to the distal convoluted tubule (Figs. 5 and 6). Amelioration of adverse histological effects was observed in kidney histoarchitecture of the mice supplemented 2,4-D with melatonin (Group IV) and were comparable to control (Figs. 7 and 8).

DISCUSSION

The results revealed that dose of 2,4-D (50 mg/kg body weight) for 45 days produced a significant reduction in the body and kidney weights. Our findings are in accordance with other earlier reports which have attributed the reduction in body and kidney weights due to reluctant food intake [8-10]. It is possible that 2,4-D may have suppressed the hunger centers of a central nervous system, resulting in decreased food intake. The mechanism by which the growth rate is inhibited by 2,4-D could be due to alteration in food intake as well as a reduction in protein synthesis.

It was observed that 2,4-D accumulated in the kidney [8-10] and might affect their structure. Hence, kidney exhibited degenerative changes gradually with cellular atrophy. Glomerular necrosis was also evident. In our study, further extensive vacuolization, disorganization of the renal tissue with increased periglomerular space, highly damaged, and distorted glomerulus along with degenerative changes in the tubular epithelial cells as well as in the glomerulus were observed. Our findings with regard to histopathology of 2,4-D-treated mice show an agreement with the results of Tayeb *et al.* [8] who reported histopathological damage and change in terms of severe glomerular atrophy, glomerular space, and tubular damages in 2,4-D-treated rat kidney. Another histopathological study of 2,4-D-treated rat kidney done by Uyanikgil *et al.* [10] revealed that renal corpuscular degeneration, vacuolization of proximal tubules, and epithelial change in distal tubules also support the observation of the present study.

The phenoxyacetic acid herbicides have previously been shown to accumulate at high levels in the liver and kidney through the organic acid transport system, and this accumulation depresses oxygen consumption by renal cortical slices and results in uncoupling of renal mitochondria raising the possibility of organ-specific toxicity secondary to transport [32].

According to the literature, 2,4-D is a weak peroxisome proliferator, and the rat is the species most sensitive to the nephrotoxic effects of peroxisome proliferators probably due to free radical-induced toxicity as reported in the liver to support these data [21,33]. There is a site specificity to this toxicity related to areas of peroxisome proliferation or related enzyme induction (namely proximal tubule cells), and 2,4-D is the most effective peroxisome proliferator at inducing renal lesions [34]. It is well known that peroxisome proliferator-activated receptor- α is highly expressed in the proximal tubule cells of the kidney [35]. Thus, it is noted that histological damages, observed in our study and proliferation of peroxisome, have affected both the tubular structure and the glomerular part. These morphological and functional alterations have affected kidney function.

It is well known that melatonin functions as a free radical scavenger and easily enters into the cells, subcellular compartments, as well as crosses the blood-brain barrier [28]. The protective effects of melatonin against 2,4-D were described by Bongiovanni *et al.* [16] in which they showed an amelioration by melatonin against oxidative stress produced by 2,4-D in rat cerebellar granular cells. Melatonin was shown as beneficial in preserving the renal function of rats against iron overload-induced toxicity and in renal ischemia-reperfusion injury by reducing lipid peroxidation, increasing glutathione levels, and preventing the increase

in nitrite levels [36,37]. In this study also, administration of melatonin at a dose of 10 mg/kg body weight to 2,4-D-administered mice revealed ameliorative histological effects in the kidney. The histopathological alterations such as damaged and shrinkage of the glomerulus, increased capsular space, tubular dilation, and hypertrophy of tubular epithelium induced by 2,4-D had been normalized after administration of melatonin. Hence, this study confirmed mitigative effects of melatonin against 2,4-D-induced nephrotoxicity.

CONCLUSION

Oral administration of 2,4-D caused a reduction in body weight and kidney weight as well as alteration in the histopathology of the kidney, which could be responsible for its nephrotoxicity. Melatonin reduced 2,4-D-induced nephrotic changes. Protective effects of melatonin may be attributed due to its strong antioxidant properties.

AUTHORS CONTRIBUTION

Mr. Ashlesh M. Upadhyaya contributed in performing the experiment, data compilation and wrote the first draft of the manuscript. Dr. Mandava V. Rao and corresponding author, Dr. Devendrasinh D. Jhala were involved in experimental design, statistical analysis, corrections in the manuscript and overall management of the study. All authors read and approved the final manuscript.

CONFLICT OF INTERESTS

The authors confirm that this article content has no conflict of interest.

REFERENCES

- Peterson MA, McMaster SA, Riechers DE, Skelton J, Stahlman PW. 2, 4-D past, present, and future: A review. *Weed Technol* 2016;30:303-45.
- Björling-Poulsen M, Andersen HR, Grandjean P. Potential developmental neurotoxicity of pesticides used in Europe. *Environ Health* 2008;7:50.
- Yang CC, Deng JF. Intermediate syndrome following organophosphate insecticide poisoning. *J Chin Med Assoc* 2007;70:467-72.
- Sharma RK, Goyal AK. Agro-pesticides and andrology. *Int J Pharm Pharm Sci* 2014;6:12-9.
- WHO. The Impact of Pesticides on Health: Preventing Intentional and Unintentional Deaths from Pesticide Poisoning. Geneva, Switzerland: World Health Organization; 2004.
- Aylward LL, Hays SM. Biomonitoring equivalents (BE) dossier for 2,4-dichlorophenoxyacetic acid (2,4-D) (CAS No 94-75-7). *Regul Toxicol Pharmacol* 2008;51 3 Suppl:S37-48.
- Bukowska B, Wieteska P, Kwiatkowska M, Sicinska P, Michalowicz J. Evaluation of the effect of 2,4-dichlorophenol on oxidative parameters and viability of human blood mononuclear cells (*in vitro*). *Hum Exp Toxicol* 2016;35:775-84.
- Tayeb W, Nakbi A, Trabelsi M, Miled A, Hammami M. Biochemical and histological evaluation of kidney damage after sub-acute exposure to 2,4-dichlorophenoxyacetic herbicide in rats: Involvement of oxidative stress. *Toxicol Mech Methods* 2012;22:696-704.
- Tayeb W, Nakbi A, Miled A, Hammami M. The toxic effects of a commercial herbicide in various tissues of Wistar rats. *J Res Environ Sci Toxicol* 2013;2:71-9.
- Uyanikgil Y, Ates U, Baka M, Biçer S, Oztas E, Ergen G. Immunohistochemical and histopathological evaluation of 2,4-dichlorophenoxyacetic acid-induced changes in rat kidney cortex. *Bull Environ Contam Toxicol* 2009;82:749-55.
- Marouani N, Tebourbi O, Cherif D, Hallegue D, Yacoubi MT, Sakly M, *et al.* Effects of oral administration of 2,4-dichlorophenoxyacetic acid (2,4-D) on reproductive parameters in male Wistar rats. *Environ Sci Pollut Res Int* 2017;24:519-26.
- Li K, Wu JQ, Jiang LL, Shen LZ, Li JY, He ZH, *et al.* Developmental toxicity of 2,4-dichlorophenoxyacetic acid in zebrafish embryos. *Chemosphere* 2017;171:40-8.
- Tan Z, Zhou J, Chen H, Zou Q, Weng S, Luo T, *et al.* Toxic effects of 2,4-dichlorophenoxyacetic acid on human sperm function *in vitro*. *J Toxicol Sci* 2016;41:543-9.
- Venkov P, Topashka-Ancheva M, Georgieva M, Alexieva V, KaranovE. Genotoxic effect of substituted phenoxyacetic acids. *Arch Toxicol* 2000;74:560-6.

15. Amel N, Wafa T, Samia D, Yousra B, Issam C, Cheraif I, et al. Extra virgin olive oil modulates brain docosahexaenoic acid level and oxidative damage caused by 2,4-Dichlorophenoxyacetic acid in rats. *J Food Sci Technol* 2016;53:1454-64.
16. Bongiovanni B, De Lorenzi P, Ferri A, Konjuh C, Rassetto M, Evangelista de Duffard AM, et al. Melatonin decreases the oxidative stress produced by 2,4-dichlorophenoxyacetic acid in rat cerebellar granule cells. *Neurotox Res* 2007;11:93-9.
17. Bortolozzi AA, Evangelista De Duffard AM, Duffard RO, Antonelli MC. Effects of 2,4-dichlorophenoxyacetic acid exposure on dopamine D2-like receptors in rat brain. *Neurotoxicol Teratol* 2004;26:599-605.
18. Pistl J, Kovalkovicová N, Holovská V, Legáth J, Mikula I. Determination of the immunotoxic potential of pesticides on functional activity of sheep leukocytes *in vitro*. *Toxicology* 2003;188:73-81.
19. Tuschl H, Schwab C. Cytotoxic effects of the herbicide 2,4-dichlorophenoxyacetic acid in HepG2 cells. *Food Chem Toxicol* 2003;41:385-93.
20. Rosso SB, Cáceres AO, de Duffard AM, Duffard RO, Quiroga S. 2,4-Dichlorophenoxyacetic acid disrupts the cytoskeleton and disorganizes the Golgi apparatus of cultured neurons. *Toxicol Sci* 2000;56:133-40.
21. Rao MV, Satapathy A. Ameliorative effect of melatonin on 2,4-dichlorophenoxy acetic acid (2,4-d) exerted hepatotoxicity in mice. *Bioscan* 2016;11:2281-6.
22. Al-Baroudi DA, El-Kholy T, Arafat R, Ali A. The potential protective role of chamomile extract on rat liver ultrastructural changes induced by 2, 4-dichlorophenoxyacetic acid. *J Diagn* 2016;3:11-20.
23. Toledo-Ibarra GA, Díaz Resendiz KJ, Ventura-Ramón GH, González-Jaime F, Vega-López A, Becerril-Villanueva E, et al. Oxidative damage in gills and liver in Nile tilapia (*Oreochromis niloticus*) exposed to diazinon. *Comp Biochem Physiol A Mol Integr Physiol* 2016;200:3-8.
24. Tan DX, Chen LD, Poeggeler B, Manchester LC, Reiter RJ. Melatonin: A potent, endogenous hydroxyl radical scavenger. *Endocr J* 1993;1:57-60.
25. Hardeland R, Pandi-Perumal SR. Melatonin, a potent agent in antioxidative defense: Actions as a natural food constituent, gastrointestinal factor, drug and prodrug. *Nutr Metab (Lond)* 2005;2:22.
26. Reiter RJ, Acuña-Castroviejo D, Tan DX, Burkhardt S. Free radical-mediated molecular damage. Mechanisms for the protective actions of melatonin in the central nervous system. *Ann N Y Acad Sci* 2001;939:200-15.
27. Tan DX, Manchester LC, Terron MP, Flores LJ, Reiter RJ. One molecule, many derivatives: A never-ending interaction of melatonin with reactive oxygen and nitrogen species? *J Pineal Res* 2007;42:28-42.
28. Eghbal MA, Eftekhari A, Ahmadian E, Azarmi Y, Parvizpur A. A review of biological and pharmacological actions of melatonin: Oxidant and prooxidant properties. *J Pharm Rep* 2016;1:1-9.
29. Tan DX, Manchester LC, Esteban-Zubero E, Zhou Z, Reiter RJ. Melatonin as a potent and inducible endogenous antioxidant: Synthesis and metabolism. *Molecules* 2015;20:18886-906.
30. INSA. Guidelines for Care and Use of Animals in Scientific Research. New Delhi, India: Indian National Science Academy; 2000.
31. Cardiff RD, Miller CH, Munn RJ. Manual hematoxylin and eosin staining of mouse tissue sections. *Cold Spring Harb Protoc* 2014;2014:655-8.
32. Pritchard JB, Krall AR, Silverthorn SU. Effects of anionic xenobiotics on rat kidney. I-tissue and mitochondrial respiration. *Biochem Pharmacol* 1982;31:149-55.
33. Kawashima Y, Katoh H, Nakajima S, Kozuka H, Uchiyama M. Effects of 2,4-dichlorophenoxyacetic acid and 2,4,5-trichlorophenoxyacetic acid on peroxisomal enzymes in rat liver. *Biochem Pharmacol* 1984;33:241-5.
34. Ozaki K, Mahler JF, Haseman JK, Moomaw CR, Nicolette ML, Nyska A. Unique renal tubule changes induced in rats and mice by the peroxisome proliferators 2,4-dichlorophenoxyacetic acid (2,4-D) and WY-14643. *Toxicol Pathol* 2001;29:440-50.
35. Braissant O, Fougelle F, Scotto C, Dauça M, Wahli W. Differential expression of peroxisome proliferator-activated receptors (PPARs): Tissue distribution of PPAR-alpha, -beta, and -gamma in the adult rat. *Endocrinology* 1996;137:354-66.
36. Abd-Elkader M, Aly H. Protective effect of melatonin against iron overload-induced toxicity in rats. *Int J Pharm Pharm Sci* 2015;7:116-21.
37. Rodríguez-Reynoso S, Leal C, Portilla-de Buen E, Castillo JC, Ramos-Solano F. Melatonin ameliorates renal ischemia/reperfusion injury. *J Surg Res* 2004;116:242-7.