

## POTENCY OF CHIVES (*ALLIUM SCHOENOPRASUM* L.) LEAVES INFUSE AS INHIBITOR CALCIUM LITHOGENESIS ON URINARY TRACT

SITI MORIN SINAGA\*, IKSEN IKSEN, GINDA HARO, SELVY WARDHANY

Department of Pharmaceutical Chemistry, Faculty of Pharmacy, Universitas Sumatera Utara, Medan 20155, Indonesia.

Email: Sitimorinsinaga28@gmail.com

Received: 01 October 2017, Revised and Accepted: 25 November 2017

### ABSTRACT

**Objective:** This study examined the antilithogenesis activity by *in vitro* and histopathologic study from the infuse solution of chives leaves powder.

**Methods:** The study begins with standard phytochemical screening on the powder of chives leaves. For performing *in vitro* antilithogenesis activity, atomic absorption spectrophotometry method was adopted to measure the dissolved calcium level. Histopathologic study was using animal models.

**Result:** Phytochemical screening of chives leaves powder has a lot of phytochemical constituents. *In vitro* assay showed that chives infuse can dissolve the human calcium stone (47.7% for 12.5% concentration of chives leaves infuse). The histopathologic study showed that chives leaves can be used to treat the calcium lithogenesis.

**Conclusion:** This experiment provides evidence that chives leaves have highlighted the potential efficacy for the treatment of calcium lithogenesis.

**Keywords:** Chives, Calcium oxalate, Lithogenesis, Infuse, Urinary.

© 2018 The Authors. Published by Innovare Academic Sciences Pvt Ltd. This is an open access article under the CC BY license (<http://creativecommons.org/licenses/by/4.0/>) DOI: <http://dx.doi.org/10.22159/ajpcr.2018.v11i3.22851>

### INTRODUCTION

The problems related with kidney are the major problem for human beings. The major functions of the kidney are balancing of electrolytes and regulation of water, production of erythrocytes, regulating the acid-base balance, regulation of blood calcium level, and involve the process of gluconeogenesis [1-3]. There will be many diseases which can affect the kidney function. Urolithiasis is one of the most painful ailments of the urinary tract disorder. In industrialized countries, approximately 10-12% of the population will develop kidney stones [4]. With a prevalence of >10% and an expected recurrence rate of ~50% stone disease has an important effect on the health-care system [5]. The most common type of stone contains calcium in combination with oxalate or phosphate [6].

Invasive procedures for the treatment of urinary calculi may cause serious complications and they also impose a great load of costs to the health-care system [7]. Using of herbal plants for the calcium lithogenesis is the best method in the traditional medicine. Because when we use the chemical compounds may induce the side effects for many organs of our body. However, plants are having a lot of phytochemicals, which heal the kidney damages without the side effects [3].

Chives (*Allium schoenoprasum* L.) is one of the important medicinal plants in Indonesia coming under the family of Liliaceae [8]. Chives contains a lot of phenolic compounds such as gallic acid, coumaric acid, ferulic acid, and rutin. Chives also contained a lot of potassium around 2960 mg/100 g [9]. The biomedical application of chives is very bulky one because it plays a very good role in various health problems such as treatment of vaginal discharge, constipation, infection, speed up the blood flow, antioxidants, breast cancer, and antihypertensive [10-13].

Previous research using the atomic absorption spectrophotometry showed that calcium levels will increase in kidney induced by ethylene glycol [14]. *In vitro* study using calcium oxalate powder showed that chives leaves effect can dissolve the calcium oxalate [15]. In this present investigation study of anticalcium lithogenesis activity of chives leaves

infuse is carried out using real calcium stone from human to test the *in vitro* solubility in chives leaves infuse. The histopathology of kidney tissue from rats will be investigated by seeing the effect of chives leaves infuse on the damaged kidney tissue.

### METHODS

#### Plant material preparation

*A. schoenoprasum* L. (chives) plant was collected from Pantai Labu region of North Sumatera, Indonesia, in February 2017. The plant sample was identified and authenticated by the Herbarium Medanense of University of Sumatera, Medan, Indonesia (No: 928/MEDA/2017).

#### Preparation of infuse solution

After authentication, *A. schoenoprasum* L. (chives) was collected and the leaf was separated carefully, washed thoroughly, and then dried it in oven. After drying, the leaves of *A. schoenoprasum* L. (chives) were ground using a mechanical blender into a powder. The infusion solution was made using dried chives leaves powder. Variation concentration of dried chives leaves infuse was made in 7.5%, 10%, and 12.5% (w/v). The doses used were in accordance with the Indonesian pharmacopoeia 4<sup>th</sup> edition [16].

#### Preliminary phytochemical screening

Phytochemical screening carried out on *A. schoenoprasum* L. (chives) leaves powder included examining the chemical metabolites constituent of alkaloids, flavonoids, glycosides, saponins, tannins, triterpenoids, and steroids [17-19].

#### *In vitro* study using human calcium stone

*In vitro* study was conducted according to Iksen *et al.* In this study, samples were divided into three variations concentration of chives leaves powder (7.5%, 10%, and 12.5%). Each 100 mL of infuse from each group will be incubated with 100 mg human calcium stone at 37°C for 4 h. The human calcium stone collected from nephrolithiasis patients in Permata Bunda Hospital, Medan, Indonesia. After 4 h, the solution of chives leaves powder will be measured using atomic

absorption spectrophotometry at a wavelength of 422.7 nm to check the solubility of calcium.

#### Preparation of calcium calibration curve

A total of 10 mL of 1000 ppm calcium (the mother liquor) were added to a 100 mL volumetric flask and then added aquadest right to mark boundaries, the obtained raw potassium 100 ug/mL. Each of 1 mL, 2 mL, 3 mL, 4 mL, and 5 mL pipetted calcium standard solution 100 ug/mL in a 50 mL volumetric flask to obtain a successive concentration of 1 ppm; 2 ppm; 3 ppm; 4 ppm; and 5 ppm and measured at a wavelength of 422.7 nm with an air-acetylene flame type using atomic absorption spectrophotometry.

#### Destruction of samples

100 mL for each infuse solution was added by 10 mL nitric acid 65% and heat on a hot plate until the infuse solution become transpicuous.

#### Measurement of dissolved calcium from calcium stone

The sample solution that has been prepared with the absorbance measured using flame atomic absorption spectrophotometry at a wavelength 422.7 nm for calcium. Absorbance values obtained should be within the range of the calibration curve of calcium standard solution. Levels of calcium were calculated based on the regression equation of the calibration curve [15].

#### Experimental design for histological assay

For inhibiting calcium lithogenesis studies, adult male Wistar albino rats weighing around 170–180 g were selected. The animals were acclimatized to standard laboratory conditions and maintained for 12 h light and dark cycle. They were provided with regular rat chow and drinking water *ad libitum*. Our Institutional Animal Research Ethics Committees Approval No: 697/KEPH-FMIPA/2016.

In this study, animals were divided into five groups, each with five rats. The Group I act as normal group. Group II act as calculi control negative where animals received 0.75% ethylene glycol with 2% ammonium chloride in drinking water for 20 days. Group III animals received 0.75% ethylene glycol with 2% ammonium chloride in drinking water along with Batugin Elixir<sup>®</sup> from the 1<sup>st</sup> day till the 10<sup>th</sup> day. Rats in Group IV, V, and VI were treated, respectively, with dried chives leaves infuse solution (doses: 7.5%, 10%, and 12.5%) from day 11 till the last day.

#### Collection and analysis of tissue for histological assays

After the last time of animal treatment, animals were anesthetized and killed. The kidneys were immediately excised and washed in ice cold PBS solution. Then, the kidneys were fixed in 10% buffered formalin. The stages of preparing histopathologic preparations consist of fixation, dehydration, clearing, embedding, blocking, sectioning, staining, and covering. The 5 µm thick sections were stained through hemotoxylin-eosin solution and examined by light microscopy.

## RESULTS

#### Phytochemical screening

Screening results of chives leaves powder showed on Table 1. which mean that chives leaves powder has different chemical compound.

#### Calibration curve of calcium

Fig. 1 showed that the correlation coefficient obtained can be accepted as the appropriate requirements for the correlation coefficient which should not smaller than 0.995 [15].

#### *In vitro* result of dissolved calcium

The dissolved calcium level from human calcium stone was investigated using atomic absorption spectrophotometry. Table 2 summarizes the result from *in vitro* dissolved calcium level.

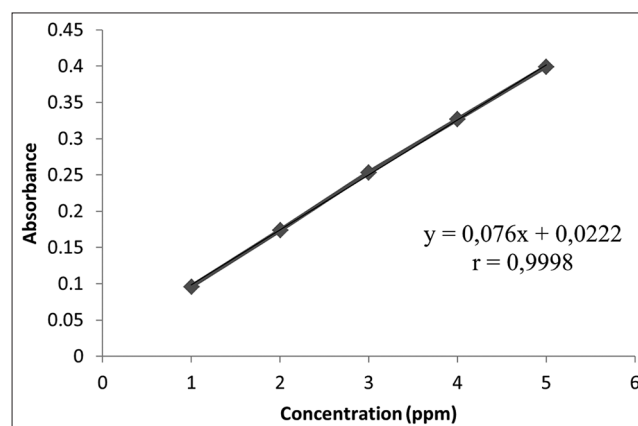
#### Histopathologic studies

The result of histopathologic studies showed that the treatment group (Group IV-VI) showed similar characters in normal group (Figs. 2-4).

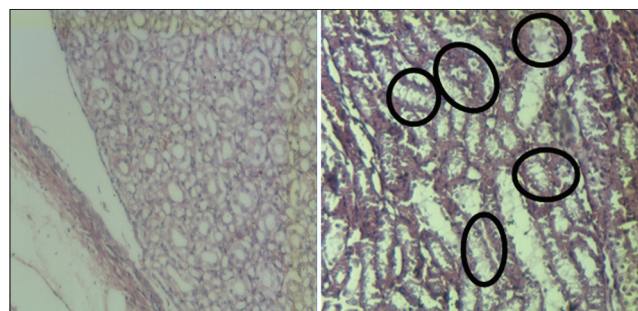
The crystal of calcium oxalate in negative control group is shown by circled area.

**Table 1: Phytochemical screening result of chives leaves powder**

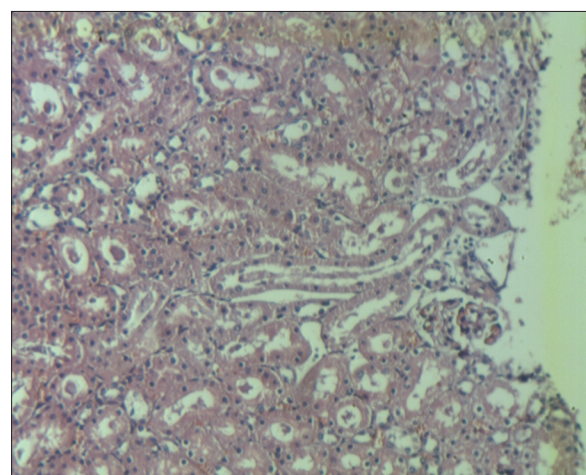
No	Screening	Chives leaves powder
1	Alkaloids	+
2	Flavonoids	+
3	Glycosides	+
4	Saponins	+
5	Tannins	+
6	Triterpenoid/steroids	+



**Fig. 1: Calibration curve of calcium**



**Fig. 2: The histopathology of kidney tissue in normal and negative control group**



**Fig. 3: The histopathology of kidney tissue in negative control group**

Table 2: Percentage of dissolved calcium from human calcium stone

No	Chives leaves powder infuse solution (%)	Dissolved calcium level ( $\mu\text{g/mL}$ )	Percentage of dissolved calcium
1	7.5	33.7986	47.70
2	10	17.5005	18.92
3	12.5	46.3024	40.09

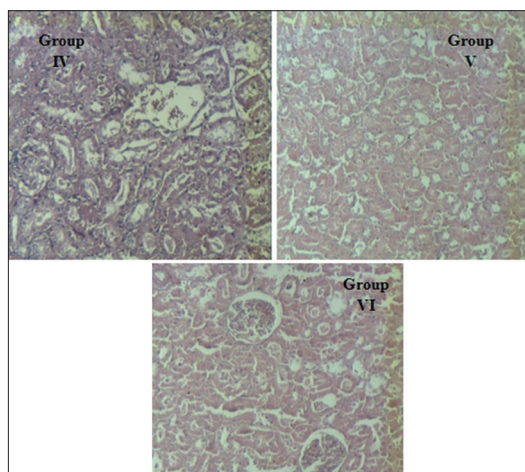


Fig. 4: The histopathology of the kidney tissue for Group IV-VI

## DISCUSSION

According to our research, chives leaves infuse has a preventive effect on inhibit calcium lithogenesis, especially on calcium oxalate calculi formation in the kidney of rats. From the *in vitro* study results, it is observed that all concentrations of chives leaves powder infuse can dissolve the calcium oxalate stone. The best concentration observed from 7.5% w/v which produced the highest dissolution of calcium oxalate stones comparison to other concentration. Chives leaves infuse has a disruptive effect on calcium oxalate crystals formed by the final metabolic yield of ethylene glycol. In Fig. 2, no any calcium oxalate or other pathological defects were found in the different segments of the kidney tissue of the rats in Group I (control positive group).

On the other groups, many calcium oxalate crystal deposits were found in the Group II (negative control group). These calcium oxalate crystals can be found due to the effect of ethylene glycol induction effect. Metabolites of ethylene glycol such as glycolaldehyde, glycolate, and oxalate can induce tissue damage. The biochemical mechanisms for this process are related to an increase in the urinary concentration of oxalate [18]. Evidence from previous studies indicated that in response to 10 days period of ethylene glycol (0.75% v/v) and ammonium chloride (2% w/v) administration, male albino rats form renal calculi which can be shown by the increased calcium level in kidney [14]. The crystals of calcium oxalate in negative control group are shown in Fig. 2.

According to the histopathologic studies, the kidney tissue in Group III (positive control), Group IV-VI showed characters similar in normal control group. This can happen due to the effect of potassium and flavonoids in chives leaves infuse. Potassium can destroy the calcium stone according to the principle of Volta's row, while flavonoids can form complexes with calculi forming compounds and make it become soluble [14,15]. The other research investigation also said that the effect of inhibiting calcium lithogenesis is from the antioxidant effect of the flavonoids. It seems that flavonoids in chive could play an antioxidant role against oxidative stress that is induced by the ethylene glycol [20-25]. The histopathology of the kidney tissue for Group III-V is shown in Fig. 4.

## CONCLUSIONS

The presented data indicate that chives leaves infuse has a good inhibitory calcium lithogenesis. Further studies are needed to prove the antiurolithiatic activity of chives leaves extract in other animal models.

## ACKNOWLEDGMENTS

The authors wish to thank Suthinee Theerachetmongkol (Department of Internal Medicine, Faculty of Medicine Siriraj Hospital, Mahidol University) for helpful support in this project research.

## AUTHORS CONTRIBUTION

All the author have contributed equally.

## CONFLICTS OF INTERESTS

Declared none.

## REFERENCES

- Sodimbaku V, Pujari L. Urolithiasis-an updated review over genetics, pathophysiology and its clinical management. *Int J Pharm Pharm Sci* 2014;6:23-31.
- Suryavanshi MV, Jadha SD, Gune RP, Bhatia MS, Shouche YS. HPLC analysis of human urine for oxalate content. *Int J Pharm Pharm Sci* 2016;8:54-9.
- Ramesh K, Manohar S, Rajeskumar S. Nephroprotective activity of ethanolic extract of *Orthosiphon stamineus* leaves on ethylene glycol induced urolithiasis in albino rats. *Int J PharmTech Res* 2014;6:403-8.
- Winston D. Herbal and nutritional treatment of kidney stones. *J Am Herbalists Guild* 2011;10:61-9.
- Saha S, Ramtej JV. *Bergenia ciliata* extract prevent ethylene glycol induced histopathological changes in the kidney. *Acta Pol Pharm Drug Res* 2010;68:711-5.
- Taylor CS, Goyal A. Isolation of phytoconstituents and *in vitro* anthilithiatic by titrimetric method, antioxidant activity by 1,1-diphenyl-2-picryl hydrazyl scavenging assay method of alcoholic roots and rhizomes extract of *Hedychium coronarium* J Koenig Plant species. *Asian J Pharm Clin Res* 2015;8:225-9.
- Hadjzadeh MA, Mohammadian N, Rahmani Z, Rassouli FB. Effect of thymoquinone on ethylene glycol-induced kidney calculi in rats. *Urol J* 2008;5:149-55.
- Iksen. The Effect of Chives (*Allium schoenoprasum*, L.) Leaves Infuse on the Calcium Salt Solubility Using *in vitro* and *in vivo* by Atomic Absorption Spectrophotometry. Thesis 2017, Faculty of Pharmacy, University of Sumatera Utara: 1-72.
- Al-Snafi AE. Pharmacological effects of allium species grown in Iraq. *Int J Pharm Health Care Res* 2014;1:132-55.
- Amalia L, Sukandar EY, Roesli RM, Sigit JI. The effect of ethanol extract of kucai (*Allium schoenoprasum* L.) bulbs on serum nitric oxide level in male wistar rats. *Int J Pharm* 2008;4:487-93.
- Jalkumar B, Jasmine R. A review of a few medicinal plants possessing anticancer activity against human breast cancer. *Int J PharmTech Res* 2016;9:333-65.
- Parvu AE, Parvu M, Vlase L, Miclea P, Mot AC, Dumitrescu RS. Anti-inflammatory effects of *Allium schoenoprasum* L. leaves. *J Physiol Pharmacol* 2014;65:309-15.
- Sachinm UR, Priyanka RP, Sagar RM. Use of natural antioxidants to scavenge free radicals: A major cause of diseases. *Int J PharmTech Res* 2010;2:1074-81.
- Haro G, Sinaga SM, Iksen I, Nerdy N, Theerachetmongkol S. Protective effects of chives leaves (*Allium schoenoprasum* L) infusion against ethylene glycol and ammonium chloride induced nephrolithiasis in rats. *J Appl Pharm Sci* 2017;7:222-5.
- Iksen I, Haro G, Sinaga SM. *In vitro* test of chive leaves infuse (*Allium schoenoprasum*, L) on calcium oxalate solubility using atomic

- absorption spectrophotometry. *Int J ChemTech Res* 2017;10:99-2.
16. Indonesia's Ministry of Health. *Indonesia Pharmacopoeia*. 4<sup>th</sup> ed. Jakarta: Indonesia's Ministry of Health;
  17. Depkes RI. *Materia Medika*. Vol. 6. Indones: Ditjen POM; 1995. p. 297-307.
  18. Farnsworth NR. Biological and phytochemical screening of plants. *J Pharm Sci* 1996;55:225-76.
  19. Harbone JB. *Metode Fitokimia*. Vol. 2. Bandung: ITB 1987. p. 49.
  20. Velpandian V, Rajaprehidha SS, Banumathi V, Anbu J, Anjana A. Effect of vediyuppu cheyaneer in ethylene glycol induced hyperoxaluria model in rats. *Int J Life Sci Pharm Res* 2012;2:63-7.
  21. Shekha MS, Ismail TF, Aziz FM. Anti-urolithiatic and anti-oxidant effects of fenugreek on ethylene glycol-induced kidney calculi in rats. *Jordan J Biol Sci* 2015;8:159-63.
  22. Deepika A, Minu S, Singla SK. The role of natural antioxidants as potential therapeutic agent in nephrolithiasis. *Asian J Pharm Clin Res* 2013;6:48-53.
  23. Lee HJ, Jeong SJ, Park MN, Linnes M, Han HJ, Kim JH, et al. Gallotannin suppresses calcium oxalate crystal binding and oxalate-induced oxidative stress in renal epithelial cells. *Biol Pharm Bull* 2012;35:539-44.
  24. Antunes LM, Darin JD, Nde LB. Effects of the antioxidants curcumin or selenium on cisplatin-induced nephrotoxicity and lipid peroxidation in rats. *Pharmacol Res* 2001;43:145-50.
  25. Sudhahar V, Veena CK, Varalakshmi P. Antiurolithic effect of lupeol and lupeol linoleate in experimental hyperoxaluria. *J Nat Prod* 2008;71:1509-12.