

## OSTEOMETRIC ESTIMATION OF SEX FROM MASTOID TRIANGLE IN MALAYSIAN POPULATION

ABDELNASSER IBRAHIM<sup>1,2</sup>, ASPALILAH ALIAS<sup>1,3</sup>, MOHAMED SWARHIB SHAFIE<sup>1</sup>, SRIJIT DAS<sup>4</sup>,  
FARIDAH MOHD NOR<sup>1\*</sup>

<sup>1</sup>Forensic Unit, Department of Pathology, Universiti Kebangsaan Malaysia Medical Centre, Jalan Yaacob Latif, Bandar Tun Razak, 56000 Kuala Lumpur, Malaysia. <sup>2</sup>Department of Forensic Medicine and Clinical Toxicology, Faculty of Medicine, Al Azhar University, Almokhayam Aldaem Street, Cairo, Egypt. <sup>3</sup>Department of Basic Sciences and Oral Biology, Faculty of Dentistry, Universiti Sains Islam Malaysia, Tingkat 15, Menara B, Persiaran MPAJ, Jalan Pandan Utama, Pandan Indah, 55100 Kuala Lumpur, Malaysia. <sup>4</sup>Department of Anatomy, Universiti Kebangsaan Malaysia Medical Centre, Jalan Yaacob Latif, Bandar Tun Razak, 56000 Kuala Lumpur, Malaysia. Email: mnfaridah@gmail.com

Received: 16 March 2018, Revised and Accepted: 12 April 2018

## ABSTRACT

**Objective:** Determination of sex is one of the most important parameters for conducting biological profile of unknown skeletal remains in anatomical anthropology and forensic medicine. Mastoid bone is useful for the identification of sex, as it is the most protected bone and is resistant to damage, due to its anatomical position at the base of the skull. The aim of this study was to develop new equation for the estimation of sex from mastoid triangle in the Malaysian population.

**Methods:** About 10 parameters were studied on 388 computed tomography scans of crania in 231 males and 157 females. The parameters comprised three sides of mastoid triangle, its perimeter and area on both sides. T-test was used to compare between the right and left sides and between males and females. Stepwise discriminant function was used to reveal the best discriminatory parameter and its classification accuracy.

**Results:** Comparison of means by T-test revealed no difference between the right and left sides in both sexes. T-test showed a significant difference between males and females for all parameters. Perimeter of mastoid triangle was found to be the best parameter by stepwise discriminant analysis. The equation based on perimeter of mastoid triangle was developed with 84.4% classification accuracy.

**Conclusion:** The developed equation could be used to assess sexual dimorphism of fragmented Malaysian crania with intact mastoid region. The achieved cross-validated classification was relatively high compared to that in other previous studies.

**Keywords:** Mastoid, Sex, Computed tomography scan, Anthropology, Forensic.

© 2018 The Authors. Published by Innovare Academic Sciences Pvt Ltd. This is an open access article under the CC BY license (<http://creativecommons.org/licenses/by/4.0/>) DOI: <http://dx.doi.org/10.22159/ajpcr.2018.v11i7.25986>

## INTRODUCTION

Identification of skeletal remains and dismembered remains is a vital part in any medicolegal investigation. The need for the identification of remains arises, particularly in cases of mass disasters [1,2]. Identification is vital when the dead body is mutilated to conceal the identity of the victim. In such cases, the main role of the forensic scientists is to establish the biological profile by estimating age, sex, stature, and ancestry [3,4].

Bioanthropological analyses of an individual from its burn remains are a very challenging task. This is due to fragmentation and other heat-induced changes that make the analyses more difficult, thereby restricting the use of conventional methods that are usually used for identification purposes [5,6]. Primary identifiers such as fingerprints and DNA are frequently damaged in soft tissue damage. In such cases, decomposition may negate facial recognition, and high temperature may denature DNA [7,8]. As a result, positive identification based on comparison of features using antemortem records may be of limited use [9,10].

The mastoid region is highly resistant to physical damage due to its anatomical position and the compact structure of the mastoid bone. This explains the usefulness of mastoid bone in cases, where there is inability to use other metric and morphological methods for the determination of sex in skull [11]. The World Health Organization Fracture Risk Assessment Tool (FRAX) indicated that the most probable fractures are hip fracture and other major osteoporotic fractures such as (spine, forearm, hip, and shoulder), and this was due to chronic inflammation,

inactivity, and increased risk of falling [12]. Metric analyses are often found to be more superior in determining sex than nonmetric traits. This is attributed to a greater statistical weight and objectivity in metric analysis than in nonmetric trait analysis [13]. Sexual dimorphism can be achieved by discriminant function analysis, which is an objective statistical method for sex determination [14]. Discriminant function analysis selects the minimum number of parameters yielding maximum discriminating effectiveness [15].

A study by Paiva and Segre (2003) in a population of Sao Paulo, Brazil, showed that the mastoid triangle can fairly determine the sex of an unidentified skull [16]. Saini *et al.* (2012) studied sexual dimorphism in mastoid triangle among 138 North Indians and offered good indicators to identify sex using mastoid process [17]. Kemkes and Gobel (2006) assessed the metric measurements of mastoid triangle in 97 German skulls and 100 Portuguese skulls to evaluate validity of the method by Paiva and Segre (2003); however, replication of the results by Paiva and Segre was not possible [18].

Nagoka *et al.* (2005) developed new standards for determining sex in human skeletal remains. The length, height, and width of the mastoid process were measured in the medieval to early modern Japanese skeleton. Although high classification accuracy was achieved, there was also high level of error in intra- and interobserver error measurements of the mastoid process [19]. Galdames *et al.* (2008) studied the existence of sexual dimorphism in the dimensions and the area of mastoid triangle (AMT) using statistical and discriminant function analysis among 81 skulls of Brazilian individuals [20].

Another study was done on 100 Thai skulls to estimate sex from measurements of mastoid triangle, which provided an accurate method for the determination of sex in Thai skulls [21]. Gupta *et al.* (2012) developed a new standard for the determination of sex in fragmentary human skeletal remains using mastoid process of 70 South Indians skulls [22]. Determination of sex from mastoid process was achieved in 80 Egyptian skulls by anthropometric measurements using multidetector computed tomography [23].

The present study aimed to determine the most sexually dimorphic dimensions of the mastoid process to develop population-specific, sex-discriminating anthropometric standards for the mastoid triangle in a documented Malaysian population using computed tomographic (CT) scans of lateral aspect of skull. Besides, using the various dimensions of the mastoid triangle, the perimeter and area of the mastoid triangle were computed to study the sex difference in these parameters. In this study, discriminant function was derived, which will help in determining the sexual dimorphism of skull or even fragmentary pieces of Malaysian skulls.

## METHODS

### CT scans

The retrospective study was conducted on 388 CT scans of the Malaysian crania (231 males and 157 females). The sample was retrieved from the archived image server at the Forensic Department in Hospital Kuala Lumpur and the Department of Radiology in Hospital Universiti Kebangsaan Malaysia (HUKM). The CT images of the skulls were done at 0.5 mm slices with small field of view from vertex to interthoracic level. The images were autoprogrammed for reconstruction at 1.0 mm for better resolution using volume rendering technique (VRT). The reconstructed VRT images of each skull were selected and enlarged by Toshiba bone CT software. The specific relevant measurements were taken for each individual case. The CT images were obtained in this manner for all patients during the research period. All cases were above or equal to 18 years, i.e., between 18 and 68 years of age. Cases with a poorly pneumatized mastoid due to previous inflammation were excluded from the study [24]. Moreover, cases with fracture, deformation, or surgery in the mastoid region were excluded from the study. The sex and age of the subjects were taken from the hospital records. Ethics of the study was approved by the Medical Ethics Committee, Faculty of Medicine, UKM, with code number UKM PPI/111/8/JEP-2016-344.

### Bony landmarks

A total of six landmarks, namely left mastoidale, left porion, left asterion, right mastoidale, right porion, and right asterion were collected by the Checkpoint Stratovan software and exported in Morphologika format as three dimensions (x, y, and z). Mastoidale, porion, and asterion are three craniometric points that form the mastoid triangle on the lateral aspect of the skull (Fig. 1). The mastoidale (M) represents the lowest craniometric point at the mastoid process. The porion (P) represents the superior surface of the external auditory meatus. The asterion (A) represents the craniometric point at the junction of the lambdoid, occipitomastoid, and parietomastoid sutures. The collected landmarks were exported from Stratovan software in Morphologika format and gathered by Notepad Plus software. Next, the data were run on the MorphoJ software. The raw coordinate dataset was exported from MorphoJ to be used in Excel sheet. Distances between landmarks (D) were collected in cm according to the following formula  $D = \sqrt{[(x_2 - x_1)^2] + [(y_2 - y_1)^2] + [(z_2 - z_1)^2]}$ . The following measurements were taken on the identification of the aforementioned craniometric points:

1. Asterion-porion (AP): It is the linear distance from asterion to porion.
2. Asterion-mastoidale (AM): It is the linear distance from asterion to mastoidale.
3. Porion-mastoidale (PM): It is the linear distance from porion to mastoidale [11].

The AMT was calculated in cm<sup>2</sup> using the Heron's formula [18],  $AMT = \sqrt{[S * (S - AM) * (S - AP) * (S - PM)]}$ , where S represents the semi-perimeter of the triangle,  $S = (AM + AP + PM) / 2$ . Perimeter of

mastoid triangle was calculated in cm as the sum of three sides of mastoid triangle (AP+AM+PM). The data were analyzed using SPSS (version 21). An independent sample t-test was performed to test the significance of all parameters between the right and left sides of mastoid triangle and between both sexes. A discriminant function was performed to determine the best parameter between sexes using Wilks' lambda with F=3.84 to enter and F=2.71 to remove. As there was no difference between the right and left sides, the mean of both sides was taken, and a total of five parameters were analyzed in a stepwise discriminant and Cross-validated function analysis [11].

## RESULTS

The present study used CT images of skull in 231 males and 157 females within the age range of 18–70 years old. In both sexes, the left and right measurements of mastoid triangle and AMT showed no difference (Table 1). All three dimensions of mastoid triangle were found to be larger in males than females, irrespective of the sides (Table 2). The male to female differences were significant in their linear distances between asterion and mastoidale ( $p < 0.01$ ), between porion and mastoidale ( $p < 0.01$ ), and also between asterion and porion ( $p < 0.01$ ). The perimeter of the mastoid triangle was larger in males than in females. The AMT was significantly different between different sexes ( $p < 0.01$ ).

Stepwise discriminant analysis produced perimeter of mastoid triangle as the best parameter to differentiate between males and females (Table 3). Determination of sex was done by comparing the discriminant scores (DSs) with sectioning point.

DS was as follows (Table 3):

$DS = [(0.854 * \text{Perimeter}) - 12.11]$ , whereby perimeter is the sum of the three sides of mastoid triangle (A-P+A-M+P-M).

$[P = (a_1 \times x_1) + (a_2 \times x_2) + \dots + (a_n \times x_n) + b]$ , whereby  $a_1$  to  $a_n$  are unstandardized raw factors (the discriminant coefficient),  $x_1$  to  $x_n$  are discriminating parameters, and  $b$  is the constant.

The sectioning point is the mean of male and female centroids of the same function. To assign the case to either male or female, the product DS was compared to the sectioning point derived by the discriminant function. A value higher than the sectioning point was deemed to be male, and a value below it was deemed to be female [25]. The average mean of perimeter of mastoid for males and females (15.17 and 12.72) was used to test the equation.

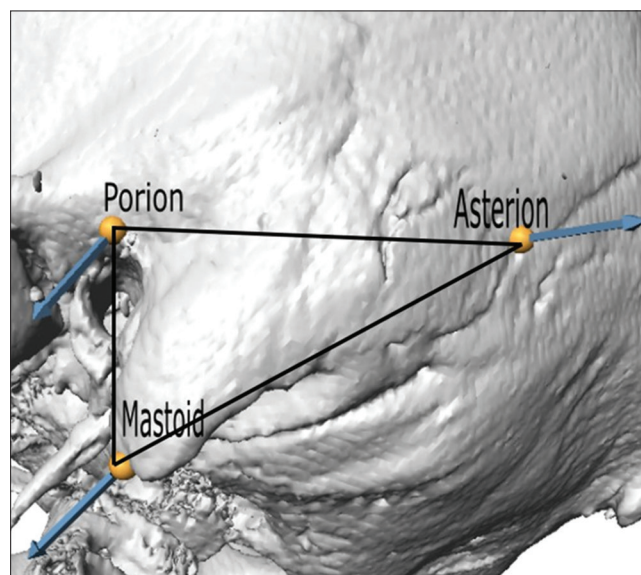


Fig. 1: Boundaries of the mastoid triangle

Sectioning point=(male centroid+female centroid)/2=(0.848-1.247)/2=-0.199.

A DS for males was as follows:  
DS=[(0.854\*15.17)-12.11]=0.851

A DS for females was as follows:  
DS=[(0.854\*12.72)-12.11]=-1.244.

The DS for males was found to be greater than the sectioning point, while the DS for females was less than the sectioning point.

In the original sample, the sensitivity was 83.3% and specificity was 88.5%. By cross-validation, sensitivity was 82.3% and specificity was 88.5%. About 84.4% of cross-validated grouped cases were correctly classified (Table 4). Cross-validation was done for all cases in the

analysis. In cross-validation, each case was classified by the functions derived from all cases. The perimeter of the mastoid was included when the measurements were analyzed by stepwise discriminant analysis (Table 3).

**DISCUSSION**

To the best of our knowledge, this is the first study to be conducted in the Malaysian population for the determination of sex using mastoid process. In this study, a new set of sex discriminant functions was generated by CT images of skull based on recent anthropometric standards for the mastoid triangle of adults. It provided a baseline data for the determination of sex in crania or any fragmented piece of skull bone, namely mastoid process in particular. Identification of the human remains is essential especially with the frequent occurrence of mass disaster in flood, aircraft crash, and other related accidents in Malaysia.

**Table 1: Summary statistics for individual measurements and area of mastoid triangle**

*Parameter		Lt		Rt		T	p
		Mean±SD	Range	Mean±SD	Range		
Male (N=231)	A-P (cm)	5.6±0.61	(4.2-7.7)	5.6±0.64	(4.4-7.9)	1.18	0.27
	A-M (cm)	5.9±0.61	(3.9-7.3)	5.9±0.65	(3.8-7.7)	-1.1	0.23
	P-M (cm)	3.5±0.45	(2.3-4.7)	3.5±0.42	(2.4-4.7)	0.2	0.84
(Lt=Rt)	Perimeter (cm)	15.1±1.37	(11.3-18.7)	15.1±1.4	(11.2-19.7)	0.1	0.92
	AMT (cm <sup>2</sup> )	9.8±1.79	(5.73-14.39)	9.76±1.82	(5.52-15.47)	0.24	0.8
Female (N=157)	A-P (cm)	4.7±0.53	(3.2-6.9)	4.7±0.49	(3.2-6.9)	-0.35	0.72
	A-M (cm)	4.8±0.56	(3.2-6.7)	4.9±0.51	(3.2-6.7)	-1.5	0.11
	P-M (cm)	3±0.36	(2.1-3.8)	2.9±0.36	(2.1-3.8)	1	0.31
(Lt=Rt)	Perimeter (cm)	12.6±1.19	(8.7-16.9)	12.7±1.1	(8.7-16.9)	-0.58	0.56
	AMT (cm <sup>2</sup> )	6.88±1.26	(3.43-10.92)	6.88±1.21	(3.43-10.92)	0.004	1

\*A-M: Linear distance measured from the asterion to the mastoidale, A-P: Linear distance measured from the asterion to the porion, P-M: Linear distance measured from the porion to the mastoidale, Perimeter: Sum of sizes of the mastoid triangle, AMT: Area of the mastoid triangle, SD: Standard deviation

**Table 2: Descriptive statistics: Dimensions of the mastoid triangle, perimeter, and area of the mastoid triangle between males and females**

*Parameter	Males (n=231)		Females (n=157)		T assumed Not assumed	p value
	Mean±SD	Range	Mean±SD	Range		
A-M (cm)	5.9±0.55	(4.3-7.7)	4.9±0.46	(3.3-6.06)	18.8 19.5	p<0.01
A-P (cm)	5.6±0.54	(3.9-7.5)	4.7±0.43	(3.6-6.04)	16.6 17.4	p<0.01
P-M (cm)	3.5±0.41	(2.5-4.6)	3±0.34	(2-3.9)	13.8 14.3	p<0.01
Perimeter (cm)	15.1±1.2	(11.2-19.1)	12.7±1	(9.6-14.9)	20.2 21.1	p<0.01
AMT (cm <sup>2</sup> )	9.78±1.68	(5.63-14.4)	6.88±1.12	(3.96-10.03)	18.8 20.3	p<0.01

\*A-M: Linear distance measured from the asterion to the mastoidale, A-P: Linear distance measured from the asterion to the porion, P-M: Linear distance measured from the porion to the mastoidale, Perimeter: Sum of sizes of the mastoid triangle, AMT: Area of the mastoid triangle, SD: Standard deviation

**Table 3: Stepwise discriminant function analysis and unstandardized coefficient for the variables**

Function	Variable entered	Wilk's lambda	Unstandardized coefficient	Constant	Males and females centroids	Sectioning point
Function 1	Mastoid perimeter	0.485	0.854	-12.112	0.848-1.247	-0.199

**Table 4: Correct group membership and cross-validation**

Function	Predicted group membership%			% Correctly classified
	Classification	Males	Females	
Function 1	Original	83.3	88.5	84.4
	Cross-validated	82.3	88.5	84.4

Table 5: Comparison of studies in the dimensions of the right mastoid triangle (mm) and area (mm<sup>2</sup>)

Study	Study region	Number of tested crania		P-M		A-M		A-P		Area		Correctly classified (%)
		M	F	M	F	M	F	M	F	M	F	
Paiva and Serge [16]	Brazil	30	30	-	-	-	-	-	-	752.1	608.7	63.33
Kemkes and Globel[18]	German	72	25	30.9	28.9	50.5	49.4	48.6	46.3	717.6	655.9	58.8
Galdames et al. [20]	Portuguese	50	50	31.5	28.4	49.5	45.4	47.7	45.1	718.9	609.5	66
Manoonpol and Plakornkul [21]	Brazil	50	31	30.7	27.6	50.2	48.3	47.5	46.7	703.3	624.1	64.2
Singh et al. [28]	Thailand	60	40	35.1	31.2	57.2	52.2	53.5	49.6	912.7	752.5	76.9
Kanchan et al. [27]	North India	100	100	23.1	21.7	45.2	41.1	41.9	39.0	478.0	412.1	61
Madadin et al. [11]	South Indians	69	49	27.4	25.7	48.7	47.2	43.9	42.3	592.2	542.1	67
Present study	Saudi population	103	103	33.4	29.9	50.2	47.3	44.5	40	700.6	578.5	68.9
	Malaysia	231	157	35.6	29.8	59.8	49.7	56.2	47.9	976.1	688.6	84.4

In this research study, dimensions of the mastoid process and AMT were found to be significantly greater in males than females. The literature also showed that the mastoid process was steadily greater in male than in female in many racial groups [18,22,23,26,27]. Besides, other studies had also analyzed the classification accuracy of sexual dimorphism of the mastoid process [19,22,26].

Paiva and Serge (2003) evaluated the measurements of the mastoid triangle in determining sex in 60 skulls (30 males and 30 females). The mastoid triangle was measured in both the right and left sides so that the total area of these measurements was analyzed. The study showed that 60% of the values obtained from the right side overlapped between sexes, while 51.67% of the values obtained from the left side overlapped too. Overlapping of values between sexes was found to be 36.67%. It was also found that the mean for male (15.05 cm<sup>2</sup>) was greater than that in female (12.21 cm<sup>2</sup>). The study by Paiva and Segre (2003) demonstrated significant results in the right and left mastoid and in the AMT for the determination of sex. The value that was  $\geq 14.47$  cm<sup>2</sup> belonged to males, while the value that  $\leq 12.6$  cm<sup>2</sup> belonged to females [16].

In this study, the best parameter selected by stepwise discriminant analysis was the perimeter of mastoid triangle. The cross-validated classification accuracies for males, females, and combined were 82.3%, 88.5%, and 84.4%, respectively. This was higher than the study by Manoonpol and Plakornku (2012), who studied sexual dimorphism using mastoid process in Thais with 74.7% validated classification accuracy rate [21]. Madadin et al. (2015) evaluated mastoid triangle for estimation of sex in Saudi population and showed that the best method was to include all parameters except for perimeter of mastoid triangle. Madadin et al. (2015) achieved 71.4% classification accuracy, which was lower than that achieved by the present study (84.4%) [11].

The present study showed no difference between the right and left sides in the AMT in both sexes, which was in agreement with Madadin et al. (2015). Nevertheless, Kemkes and Gobel (2006) found asymmetry between the right and left sides in the Portuguese sample population [18]. For further analysis, the right and left sides of areas of mastoid triangle were not considered together based on the recent research study by Madadin et al. (2012).

In general, the AMT was statistically different between sexes [11], which were consistent with Saini et al. (2012). A study on the North Indians showed that the three sides of mastoid triangle were greater in males than females. Saini et al. (2012) utilized eight different measurements on the mastoid process. The prediction accuracy in stepwise discriminant function was based on the asterion-mastoidale and mastoid breadth, which were considered as the best parameters with 87% accuracy rate [17].

In the present study, the overall classification accuracy was 84.4%. This was consistent with the classification accuracy achieved in the Egyptian adults

(85%) for sex determination based on the anthropometric measurements on CT images of mastoid process. However, the study on the Egyptian population used different method, i.e. by measuring the mastoid size, in which the conventional mastoid height, oblique sagittal diameter, and mastoid volume were more sexually dimorphic in the Egyptians [24]. Kanchan et al. (2013) determined sex from mastoid triangle in the South Indians and concluded that mastoid triangle was a poor indicator of sex [27].

The average dimensions of the mastoid triangle in the present study were comparable with that in Thailand's (Table 5). Both Malaysian and Thailand studies showed greater dimensions of mastoid triangle than the other populations. This may be attributed to the same Asian origin of populations as in Thailand and Malaysia [21]. The Saudi population came next after the present study based on the dimensions of mastoid triangle [11]. The dimensions of mastoid triangle and areas were comparable between Brazil, German, and Portuguese populations, which were smaller than those in our study [16,18,20]. Minimum dimensions of mastoid triangle and areas were found in the North Indians [28]. Classification accuracy of the present study was the highest (84.4%) when compared with all the other populations (Table 5). Besides, the sample size in the present study was the largest (388 CT scans of the skulls) compared to that in the literature.

## CONCLUSION

The results of this study indicated that the perimeter of mastoid triangle is the best parameter to be used for the determination of sex. The results also indicated that all three sides of mastoid triangle, perimeter, and AMT were sexually dimorphic in the Malaysian population. The formula for sexual dimorphism was developed, which can be used for the identification of fragmentary skeletal remains with intact mastoid region. However, this formula is population specific because many environmental, genetic, nutritional conditions and effects of migration are likely to influence the shape and size of bone. The accuracy of measurements depend heavily on the specific method used in measuring the distances in the sides of the mastoid triangle, particularly along the curved surface between the landmarks. Thus, CT measurements of skull are highly recommended as it is more accurate and objective than direct morphometric measurements. The cross-validated classification accuracy achieved in this study was relatively high compared to that in previous studies. It is recommended in future to study ancestry, age groups, and stature in mastoid triangle for identification purposes in the Malaysian population.

## ACKNOWLEDGMENT

Special thanks to UKM and HKL for having access to the cases under study. The authors are grateful to UKM for the funding of this research project (Code project: GGPM-2016-069).

## AUTHORS' CONTRIBUTIONS

Dr. Abdelnasser Ibrahim, Dr. Faridah Mohd Nor, Dr. Swarhib Mohamed,



Dr. Srijit Das, and Dr. Aspalillah Alias had contributed to the concept and design of the study, acquisition, analysis, interpretation of data, drafting the article, or revising it critically for important intellectual content and final approval of the version to be published.

## REFERENCES

- Burns KR. Forensic Anthropology Training Manual. 2<sup>nd</sup> ed. Upper Saddle River: New Jersey Prentice-Hall; 2007.
- Cattaneo C. Forensic anthropology: Development of a classical discipline in the new millennium. *Forensic Sci Int* 2007;165:185-93.
- Chandrakanth HV, Kanchan T, Krishan K, Arun M, Kumar GP. Estimation of age from human sternum: An autopsy study on a sample from South India. *Int J Leg Med* 2012;126:863-8.
- Krishan K, Kanchan T, Ghosh A, Menezes RG. Forensic anthropological casework-essential methodological considerations in stature estimation. *J Forensic Nurs* 2012;8:45-50.
- Thompson TJ. Recent advances in the study of burned bone and their implications for forensic anthropology. *Forensic Sci Int* 2004;146:S203-5.
- Thompson TJ. Heat-induced dimensional changes in bone and their consequences for forensic anthropology. *J Forensic Sci* 2005;50:185-93.
- Fairgrieve S. Forensic Cremation: Recovery and Analysis. Boca Raton, Florida: CRC Press; 2008.
- Gonçalves D, Thompson TJ, Cunha E. Osteometric sex determination of burned human skeletal remains. *J Forensic Leg Med* 2013;20:906-11.
- Schmidt CW. The recovery and study of burned human teeth. In: Schmidt CW, Symes SA, editors. *The Analysis of Burned Human Remains*. London: Academic Press; 2008. p. 55-74.
- Lain R, Taylor J, Croker S, Craig P, Graham J. Comparative dental anatomy in disaster victim identification: Lessons from the 2009 Victorian Bushfires. *Forensic Sci Int* 2011;205:36-9.
- Madadin M, Menezes RG, Al Dhafeeri O, Kharoshah MA, Al Ibrahim R, Nagesh KR, et al. Evaluation of the mastoid triangle for determining sexual dimorphism: A Saudi population based study. *Forensic Sci Int* 2015;254:244-e1.
- Syngle T, Kaur S, Garg N. Osteoporotic fracture risk in rheumatoid arthritis. *Int J Pharm Pharm Sci* 2018;10:106-9.
- France DL. Observational and metric analysis of sex in the skeleton. In: Reichs KJ, editor. *Forensic Osteology. Advances in the Identification of human Remains*. Springfield: Charles C. Thomas; 1986. p. 163-86.
- Hsiao TH, Chang HP, Liu KM. Sex determination by discriminant function analysis of lateral radiographic cephalometry. *J Forensic Sci* 1996;41:792-5.
- Iscan MY, Helmer RP. Forensic Analysis of the Skull in Morphologic and Osteometric Assessment of Age, Sex, and Race From the Skull. New York: Willy Liss; 1993. p. 71-83.
- Paiva LA, Segre M. Sexing the human skull through the mastoid process. *Rev Hosp Clin Fac Med Sao Paulo* 2003;58:15-20.
- Saini V, Srivastava R, Rai RK, Shamal SN, Singh TB, Tripathi SK. Sexestimation from the mastoid process among North Indians. *J Forensic Sci* 2012;57:434-9.
- Kemkes A, Göbel T. Metric assessment of the "mastoid triangle" for sex determination: A validation study. *J Forensic Sci* 2006;51:985-9.
- Nagaoka T, Shizushima A, Sawada J, Tomo S, Hoshino K, Sato H, et al. Sex determination using mastoid process measurements: Standards for Japanese human skeletons of the medieval and early modern periods. *Anthro Sci* 2008;116:105-13.
- Galdames IC, Matamala DA, Smith RL. Sex determination using mastoid process measurements in Brazilian skulls. *Int J Morphol* 2008;26:941e4.
- Manoonpol C, Plakornkul V. Sex determination using mastoid process measurement in Thais. *J Med Assoc Thailand* 2012;95:423.
- Gupta AD, Banerjee A, Kumar A, Rao SR, Jose J. Discriminant function analysis of mastoid measurements in sex determination. *J Life Sci* 2012;4:1-5.
- Allam FA, Allam MF. Sex discrimination of mastoid process by anthropometric measurements using multidetector computed tomography in Egyptian adult population. *Egypt J Forensic Sci* 2016;6:361-9.
- Devi S, Singh K. Risk factors, prevalence and diagnosis of Hutchinsonian gliford syndrome with special reference to case reports. *Int J Pharm Pharm Sci* 2017;9:1-5.
- Ibrahim A, Alias A, Nor FM, SwarhibM, Bakar AN, Das S. Study of sexual dimorphism of Malaysian crania: An important step in identification of the skeletal remains. *Anat Cell Biol* 2017;50:86-92.
- Patnaik VV, Phatak A. Determination of sex by mastoid process by discriminant functions analysis. *J Anat Soc India* 2010;59:222-8.
- Kanchan T, Gupta A, Krishan K. Estimation of sex from mastoid triangle-A craniometric analysis. *J Forensic Leg Med* 2013;20:855-60.
- Singh RP, Verma SK, Tyagi AK. Determination of sex by measurement of area of Mastoidtriangle in human skull. *Indian Internet J Forensic Med Toxic* 2008;6:29-43.