

HEPATOPROTECTIVE ACTIVITY OF *CORDIA OBLIQUA* AGAINST PARACETAMOL-INDUCED LIVER TOXICITY ON WISTAR RATS

SIVAKRISHNAN SIVAGNANAM, PRADEEPRAJ DEVARASU

Department of Pharmacy, Annamalai University, Chidambaram, Tamil Nadu, India. Email: sivacdm82@gmail.com

Received: 18 April 2019, Revised and Accepted: 15 May 2019

ABSTRACT

Objective: The ethanolic extract of *Cordia obliqua* (EECO) Willd. leaves was evaluated for hepatoprotective activity in Wistar rats by inducing hepatic damage with paracetamol.

Methods: The leaves of *C. obliqua* were dried under shade, segregated, pulverized by a mechanical grinder and passed through a 40 mesh sieve. The powdered plant materials were stored in an air-tight container. The above-powdered materials were successively extracted with ethanol by hot continuous percolation method in Soxhlet apparatus for 24 h. The extract was concentrated using a rotary evaporator and subjected to freeze drying in a lyophilizer till dry powder was obtained.

Results: Treatment with EECO at 200 and 400 mg/kg showed significant decrease in serum glutamate-pyruvate transaminase, serum glutamic oxaloacetic transaminase, alkaline phosphatase, and total bilirubin levels and a significant elevation in the total protein, albumin, and globulin levels in serum when compared with paracetamol treated rats. In histological study of liver, the hepatocytes show moderate cytoplasm and moderately enlarged pleomorphic and hyperchromatic nuclei. The portal triads show mild periportal inflammation composed of lymphocytes, and central veins are normal.

Conclusion: On the basis of results, we can conclude that the EECO leaves showed potential hepatoprotective activity in rats.

Keywords: Histopathology, Silymarin, Paracetamol, *Cordia obliqua*, Hepatoprotective

© 2019 The Authors. Published by Innovare Academic Sciences Pvt Ltd. This is an open access article under the CC BY license (<http://creativecommons.org/licenses/by/4.0/>) DOI: <http://dx.doi.org/10.22159/ajpcr.2019.v12i7.33665>

INTRODUCTION

Liver disease accounts for approximately 2 million deaths per year worldwide, 1 million due to complications of cirrhosis, and 1 million due to viral hepatitis and hepatocellular carcinoma [1,2]. Unfortunately, treatments of choice for liver diseases are controversial because conventional or synthetic drugs for the treatment of these diseases are insufficient and sometimes cause serious side effects [3]. Hundreds of plants have been so far examined to be taken for a wide spectrum of liver diseases [4,5]. Natural products, including herbal extracts [6], could significantly contribute to recovery processes of the intoxicated liver. The *Cordia obliqua* Willd. also called as clammy cherry is a flowering plant species in the genus *Cordia* belonging to the family *Boraginaceae*. Conventionally, *C. obliqua* is used for cooling effects, anthelmintic, expectorant, and diuretic. It lessens thirst and scalding of urine, removes pains in the joints, and it is used as treatment of diseases of spleen and leprosy. Stem bark [7] is used as a mild tonic, kernels are a remedy in treatment in ringworm, and leaves are used to treat ulcers and headache externally. Seeds are used as anti-inflammatory [8] and antimicrobial agent [9]. The Javanese use the bark in the treatment of fevers [10]. Our literature survey revealed that the hepatoprotective activity of ethanolic extract of *C. obliqua* was not investigated. Hence these activities have been investigated in the present study.

METHODS

Collection and identification of *Cordia obliqua*

C. obliqua [11,12] was collected from B. Maduvankarai, Chidambaram Taluk, Cuddalore, Tamil Nadu, India. Taxonomic identification was made from Botanical Survey of Medicinal Plants Unit Siddha, Government of India, Palayamkottai.

Extraction and isolation of *Cordia obliqua*

C. obliqua leaves were collected and extract prepared from ethanol by hot continuous percolation method in Soxhlet apparatus for 24 h. The

leaves were dried under shade, segregated, pulverized by a mechanical grinder, and passed through a 40 mesh sieve. The powdered plant materials were stored in an air-tight container. The above-powdered materials were successively extracted with ethanol by hot continuous percolation method in Soxhlet apparatus for 24 h. The extract was concentrated using a rotary evaporator [13] and subjected to freeze drying in a lyophilizer [14] till dry powder was obtained.

Chemicals

All the drugs, chemicals, and reagents used for biochemical estimation were purchased from Sigma Aldrich, Mumbai.

Animals

Wistar rats weighing 150–200 g housed in standard environmental conditions were used. The protocol was approved by the Institutional Animal Ethics Committee, Annamalai University (approved number: AU-IAEC/1233/1/19). They were fed with standard rodent diet and water *ad libitum*.

Hepatoprotective activity

Experimental design

Rats were divided randomly into five groups of six animals each and treated for 1 week (7 days) as follows:

- Group-I: Animals served as normal control, treated with vehicle (0.5% carboxymethyl cellulose) 1 ml/kg once daily for 7 days orally
- Group-II: Animals served as toxic control will receive 1 ml vehicle for 7 days, and on the 5th day paracetamol 2 g/kg, body weight will be given per orally
- Group III: Animals received ethanolic extract of *C. obliqua* (EECO) Willd. 200 mg/kg body weight, orally daily for 7 days. A single dose of paracetamol 2 g/kg body weight will be administered per orally on the 5th day
- Group-IV: Received EECO Willd. 400 mg/kg body weight, by orally

daily for 7 days. A single dose of paracetamol 2 g/kg body weight will be administered per orally on the 5th day

- Group-V: Received silymarin 25 mg/kg body weight by orally daily for 7 days and a single dose of paracetamol 2 g/kg body weight will be administered per orally on the 5th day.

Biochemical analysis

Dissection and homogenization

On the 8th day, all animals were sacrificed by cervical dislocation. Blood sample was collected in previously labeled centrifuging tubes and allowed to clot for 45 min at room temperature [15]. Serum was separated by centrifugation at 2500 rpm for 15 min.

Biochemical estimation

Serum was separated and used for the estimation of biochemical parameters, namely serum glutamic oxaloacetic transaminase (SGOT), serum glutamate-pyruvate transaminase (SGPT), albumin [16], total bilirubin (TB) [17], alkaline phosphate [18,19], globulin, and total protein (TP) in autoanalyzer (Shimadzu, Japan).

Histopathological observation

The liver was excised from the animals and washed with the normal saline. The materials were fixed in 10% buffered neutral formalin, then washed, dehydrated in descending grades of isopropanol, and finally, rinsed with xylene. The tissues were then embedded in molten paraffin wax. Sections of 5 m thickness were taken using a microtome, processed in alcohol-xylene series and were stained with hematoxylin and eosin [20] and subjected to histopathological examination.

Statistical analysis

The values were expressed as mean \pm standard error of mean (n = 6). Statistical analysis were performed with one-way analysis of variance followed by Student's t-test using GraphPad InStat Software and were used to determine the statistical significance. *p<0.01, **p<0.05, and ***p<0.001, when compared with control and toxicant group as applicable.

RESULTS

Treatment with EECO at 200 and 400 mg/kg showed significant decrease in SGPT, SGOT, alkaline phosphatase (ALP), and TB levels are shown in Table 1, and a significant elevation in the TP, albumin, and

globulin levels are shown in Table 2 when compared with paracetamol-treated rats. Standard drug silymarin also exhibited similar results significantly.

HISTOPATHOLOGICAL RESULTS

The hepatoprotective effect of EECO was confirmed by histopathological examination of the liver tissue of control and treated animals: Fig. 1: Liver section of normal control rats (Group I) shows normal architecture. The central veins, sinusoids, and portal triads appear normal. The hepatocytes show moderate cytoplasm and round-to-oval nuclei. There is no periportal inflammation. Fig. 2: Toxic control (paracetamol 2 g/kg)-treated rats (Group II) show the architecture are partly effaced. The central veins, sinusoids, and portal triads appear congested. The hepatocytes show feathery degeneration and show moderate cytoplasm and round-to-oval nuclei. There is periportal inflammation. Fig. 3: Standard drug (silymarin 25 mg/kg)-treated rats (Group III) indicate that the hepatocytes have shown normal size with normal portal area. There is mild increase in fibrous connective tissues with minimal sign of hepatotoxicity. Regenerative activity is maximum. Fig. 4: EECO (200 mg/kg)-treated rats (Group IV) show liver with mild sign of hepatotoxicity, tissue with typical lobular arrangement, and minimal

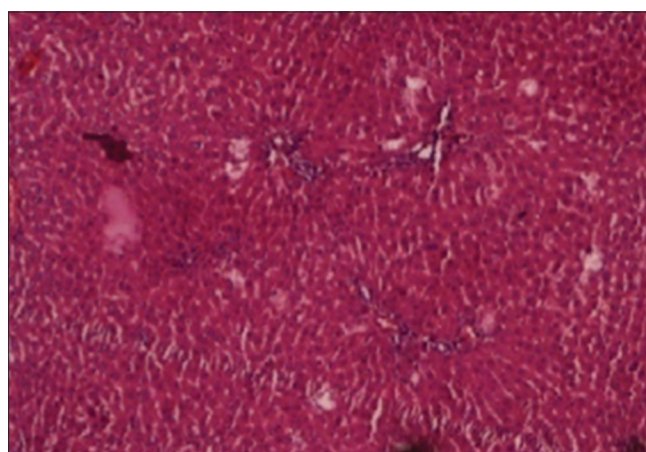


Fig. 1: Control rat liver

Table 1: Effect of ethanolic extract of leaves of *Cordia obliqua* on serum enzymes (serum glutamate-pyruvate transaminase, serum glutamic oxaloacetic transaminase, and total bilirubin) in paracetamol-treated rats

S.No.	Groups	SGOT (IU/L)	SGPT (IU/L)	TB (mg/dl)
1	Group I (control)	75.66 \pm 2.065	58.5 \pm 2.34	0.76 \pm 0.05
2	Group II (negative control)	97.66 \pm 2.87*	87.16 \pm 3.65**	1.03 \pm 0.05***
3	Group III (standard)	51.66 \pm 3.44*	49 \pm 3.74**	0.76 \pm 0.08*
4	Group IV (Test - I)	76.16 \pm 4.70**	82 \pm 1.788**	0.83 \pm 0.08*
5	Group V (Test - II)	67.83 \pm 6.04**	58.33 \pm 3.77**	0.71 \pm 0.12*

Data are expressed as mean \pm SEM, n=6 rats per group. P values, *p<0.01, **p<0.05, ***p<0.001 compared to negative control. One way ANOVA followed by student's t-test. a \rightarrow Group II compared to Group I; b \rightarrow Group II compared to Group III, IV and V. SGPT: Serum glutamate-pyruvate transaminase, SGOT: Serum glutamic oxaloacetic transaminase, TB: Total bilirubin, ANOVA: Analysis of variance, SEM: Standard error of mean

Table 2: Effect of ethanolic extract of leaves of *Cordia obliqua* on serum enzymes (albumin, alkaline phosphatase, globulin, and total protein) in paracetamol-treated rats

S.No.	Groups	Albumin (g/dl)	ALP (IU/L)	Globulin (g/dl)	TP (g/dl)
1	Group I (control)	2.63 \pm 0.33	115.16 \pm 4.30	3.033 \pm 0.21	6.96 \pm 0.44
2	Group II (negative control)	1.75 \pm 0.18*	279.66 \pm 6.53**	1.88 \pm 0.17*	5.31 \pm 0.31*
3	Group III (standard)	2.08 \pm 0.22*	167.5 \pm 8.21**	2.28 \pm 0.24*	6.93 \pm 0.26*
4	Group IV (Test - I)	2.36 \pm 0.216*	230.5 \pm 6.12**	2.66 \pm 0.19*	6.41 \pm 0.07*
5	Group V (Test - II)	2.13 \pm 0.23*	198 \pm 8.24**	2.13 \pm 0.44*	6.08 \pm 0.23*

Data are expressed as mean \pm SEM, n=6 rats per group. P values, *p<0.01, **p<0.05, ***p<0.001 compared to negative control. One way ANOVA followed by student's t-test. a \rightarrow Group II compared to Group I; b \rightarrow Group II compared to Group III, IV and V. TP: Total protein, ALP: Alkaline phosphatase, ANOVA: Analysis of variance, SEM: Standard error of mean

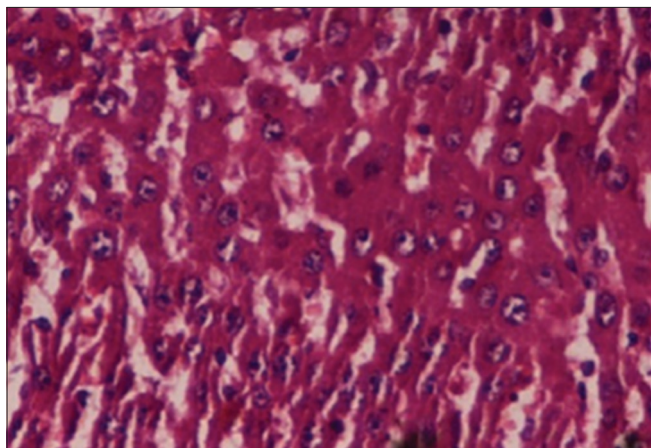


Fig. 2: Paracetamol (2 g/kg)-treated rat liver

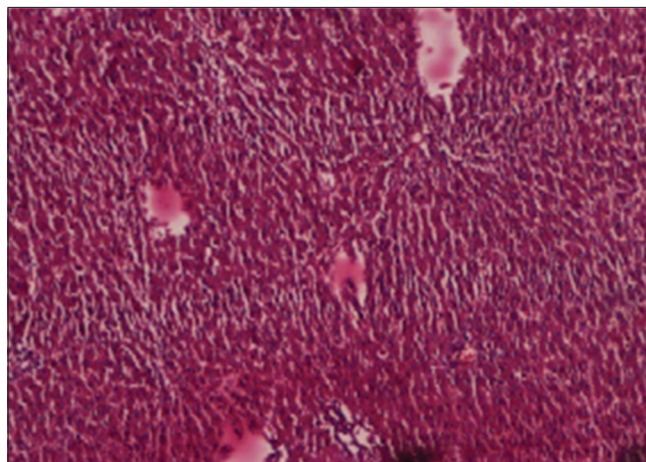


Fig. 4: Paracetamol (2 g/kg) +treated group 200 mg/kg of *Cordia obliqua*

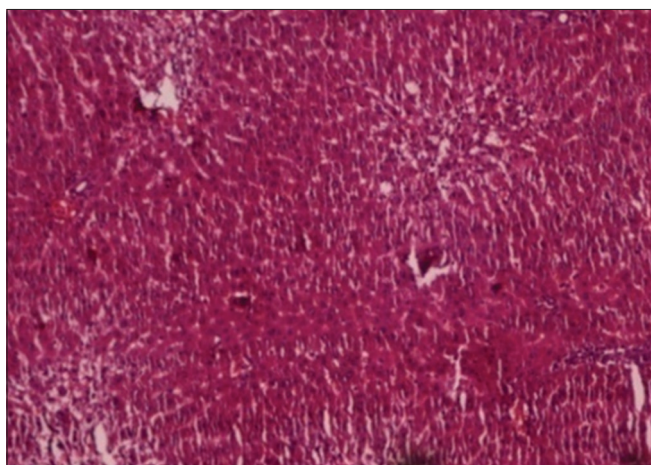


Fig. 3: Standard (silymarin 25 mg/kg) + paracetamol (2 g/kg) rat liver

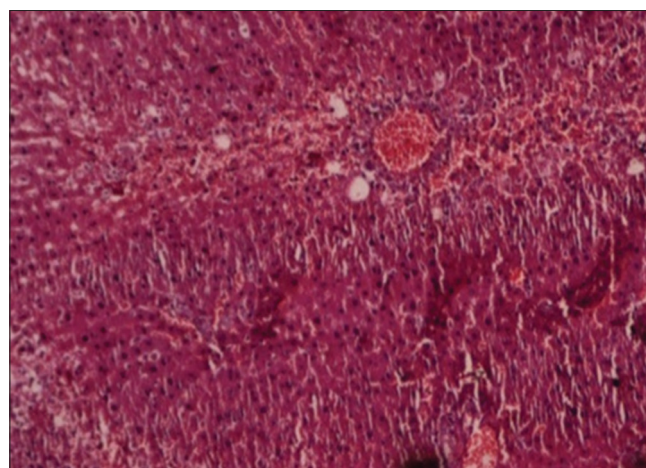


Fig. 5: Paracetamol (2 g/kg) +treated group 400 mg/kg of *Cordia obliqua*

centrilobular necrosis. The portal triads show mild periportal inflammation composed of lymphocytes. Fig. 5: EECO (400 mg/kg)-treated rats (Group V) hepatocytes show moderate cytoplasm and moderately enlarged pleomorphic and hyperchromatic nuclei. The portal triads show mild periportal inflammation composed of lymphocytes and central veins are normal.

CONCLUSION

In the present study, intoxication of Wistar rats with paracetamol when compared with control rats. Treatment with EECO at 200 and 400 mg/kg showed significant decrease in SGPT, SGOT, ALP, and TB levels and a significant elevation in the TP, albumin, and globulin levels in serum when compared with paracetamol-treated rats. Standard drug silymarin also exhibited similar results significantly. In histopathological study, the paracetamol-induced rats showed that the architecture is partly effaced. The central veins, sinusoids, and portal triads appear congested. The hepatocytes show feathery degeneration and show moderate cytoplasm and round-to-oval nuclei. There is periportal inflammation. Maximum dose (400 mg/kg) of EECO treated rats shows normal hepatocytes. The hepatocytes shows moderate cytoplasm, moderately enlarged pleomorphic and hyperchromatic nuclei. The portal triads show mild periportal inflammation composed of lymphocytes, and central veins are normal. Standard drug (silymarin 25 mg/kg)-treated rats indicate that the hepatocytes have shown normal size with normal portal area. There is mild increase in fibrous connective tissues with minimal sign of hepatotoxicity. Regenerative activity is maximum.

On the basis of results, we can conclude that the EECO leaves showed potential hepatoprotective activity in rats. Further studies are in progress to isolate the active constituents of *C. obliqua* and also to evaluate the exact mechanism of action for the hepatoprotective activity.

AUTHORS' CONTRIBUTION

All the authors contributed equally to the paper.

COMPETING INTEREST

The authors declare no conflict of interest.

REFERENCES

1. Mokdad AA, Lopez AD, Shahrzaz S, Lozano R, Mokdad AH, Stanaway J, et al. Liver cirrhosis mortality in 187 countries between 1980 and 2010: A systematic analysis. *BMC Med* 2014;12:145.
2. Asrani SK, Devarbhavi H, Eaton J, Kamath PS. Burden of liver diseases in the world. *J Hepatol* 2019;70 Suppl 1:151-71.
3. Kumar CH, Ramesh A, Kumar JS, Ishaq BM. A review on hepatoprotective activity of medicinal plants. *Int J Pharm Sci Res* 2011;2 Suppl 3:501-15.
4. Asadi-Samani M, Rafeian-Kopaei M, Azimi N. Gundelia: A systematic review of medicinal and molecular perspective. *Pak J Biol Sci* 2013;16 Suppl 21:1238-47.
5. Asadi-Samani M, Bahmani M, Rafeian-Kopaei M. The chemical composition, botanical characteristic and biological activities of *Borago officinalis*: A review. *Asian Pac J Trop Med* 2014;7S1:S22-8.

6. Asadi-Samani M, Kafash-Farkhad N, Azimi N, Fasihi A, Alinia-Ahandani E, Rafieian-Kopaei M. Medicinal plants with hepatoprotective activity in Iranian folk medicine. *Asian Pac J Trop Biomed* 2015;5 Suppl 2:146-57.
7. Tiwari K, Srivastava SD. Chemical investigation of the stem bark of *Cordia obliqua*. *Planta Med* 1979;36 Suppl 2:191-2.
8. Prakash NU, Bhuvanewari S, Balamurugan A, Radhika B. Studies on phytochemistry of 100 plants in Chennai, India. *Br J Pharm Res* 2013;3 Suppl 3:407-19.
9. Yadav R, Yadav S. Evaluation of antimicrobial activity of seeds and leaves of *Cordia obliqua* Willd against some oral pathogens. *Indo Am J Pharm Res* 2013;3:6035-43.
10. Thirupathi K, Kumar SS, Raju V, Ravikumar B, Krishna D, Mohan GK. A review of medicinal plants of the genus *Cordia*: Their chemistry and pharmacological uses. *J Nat Remedies* 2008;8 Suppl 1:1-10.
11. Parmar C, Kaushal MK. Wild Fruits of the Sub-Himalayan Region. Wild fruits of the Sub-Himalayan Region. New Delhi: Kalyani Publication; 1982. p. 136.
12. Gupta R, Gupta GD. A review on plant *Cordia obliqua* Willd.(Clammy cherry). *Pharmacogn Rev* 2015;9 Suppl 18:127-31.
13. Azmir J, Zaidul I, Rahman M, Sharif KM, Mohamed A, Sahena F, *et al*. Techniques for extraction of bioactive compounds from plant materials: A review. *J Food Eng* 2013;117 Suppl 4:426-36.
14. Sivakrishnan S, Kavitha J, Muthu AK. Antioxidant potential, total phenolic and flavonoids content of aerial parts of ethanolic extract of *Albizia procera* (Family: *Mimosoideae*). *Asian J Pharm Clin Res* 2013;6 Suppl 1:108-10.
15. Sivakrishnan S, Kottaimuthu A. Hepatoprotective activity of ethanolic extract of aerial parts of *Albizia Procera* Roxb (Benth.) against paracetamol induced liver toxicity on wistar rats. *Int J Pharm Pharm Sci* 2014;6 Suppl 1:233-8.
16. Dhivya JV, Santhy KS. Demystifying the ethnomedicinal plant *Morinda pubescens* with ethnopharmacological, phytochemical and pharmacotoxicological evidence. *J Crit Rev* 2018;5 Suppl 5:1-6.
17. Vijayanirmala R, Abinaya R, Velpandian V. Toxicological screening of a novel siddha polyherbal formulation "Siringipaerathi Chooranam". *Int J Curr Pharm Res* 2019;11 Suppl 2:18-24.
18. Sumalatha S, Padma D, Pai KS, Kotian SR, Kumar N, Bhat K. Hepatoprotective activity of aqueous extract of *Caesalpinia bonduc* against CCL4 induced chronic hepatotoxicity. *Int J Pharm Pharm Sci* 2016;8 Suppl 4:207-11.
19. Vasantharaja D, Ramalingam V. Neurotoxic effect of titanium dioxide nanoparticles: Biochemical and pathological approach in male wistar rats. *Int J Appl Pharm* 2018;10 Suppl 4:74-81.
20. Galigher AE, Kozloff EN. *Essentials of Practical Microtechnique*. Philadelphia, PA: Lea and Febiger; 1971.