

## POST-GLENOID FORAMEN: A RARE EMISSARY FORAMEN IN HUMAN SKULL

PRIYA G<sup>1\*</sup>, YASODAI R<sup>2</sup><sup>1</sup>Department of Anatomy, RVS Dental College and Hospital, Coimbatore, Tamil Nadu, India. <sup>2</sup>Department of Bharath University, Chennai, Tamil Nadu, India. Email: priyaganalan2006@yahoo.co.in

Received: 05 January 2019, Revised and Accepted: 30 January 2020

## ABSTRACT

**Objective:** The aim of the present study was to determine the presence of post-glenoid foramen in human skulls.**Methods:** The study was carried out in 100 adult dry human skulls with 200 temporal bones on each side (right and left) which were collected from the Department of Anatomy at RVS Dental College and Hospital, Coimbatore. The selected skulls were placed on a flat table and the considerable foramen was visually identified by two investigators. The foramen was examined by a probing method to find out its patency.**Results:** Of 100 skulls (200 temporal bones), only one skull showed a unilateral post-glenoid foramen on the mandibular fossa of the left side temporal bone (2% of 200).**Conclusion:** The emissary veins are considered as an important encephalic venous drainage that connects the intracranial and extracranial venous pathway through emissary foramen. If there is little variation, and rare occurrence of the emissary foramen may cause serious pathological condition. Thereby, the present study highlights one of the rare emissary foramen, the post-glenoid foramen. This anatomical study of post-glenoid foramen may help the surgeons while operating temporomandibular joint and inner ear malformation to avoid the risk of accidental bleeding during surgery.**Keywords:** Post-glenoid foramen, Petrosquamous sinus, Temporal bone, Glenoid fossa.© 2020 The Authors. Published by Innovare Academic Sciences Pvt Ltd. This is an open access article under the CC BY license (<http://creativecommons.org/licenses/by/4.0/>) DOI: <http://dx.doi.org/10.22159/ajpcr.2020.v13i4.36782>

## INTRODUCTION

The post-glenoid foramen is an emissary foramen which is rarely found in humans. It lies anterior to the external acoustic meatus in the line of fusion of the squamous and tympanic parts of the temporal bone [1]. It is also called as foramen jugulare spurium or foramen retroarticulare. If present, it transmits the petrosquamous sinus. The petrosquamous sinus is an emissary vein connecting the intra and extracranial venous networks. It arises from the dorsolateral portion of the transverse sinus, before the confluence of the transverse sinus with the superior petrosal sinus. Then, courses over the superolateral surface of the petrous bone, either within an osseous groove or a complete canal called a temporal canal of Vergi [2].

It has two drainage pathways: One anteroinferiorly into the retromandibular vein through the foramen retroarticulare and another one anteromedially into the pterygoid venous plexus through the foramen ovale. The petrosquamous sinus collects the middle and superficial temporal veins, the masseterine veins, and the internal maxillary veins and drains into the external jugular vein. It usually disappears during the development of adult venous patterns in the past 3 months of prenatal life in humans [3].

Although this drainage pathway is prominent in most mammals where it constitutes the major route of cerebral venous drainage, it is rarely of functional significance in humans, in which the internal jugular vein and vertebral venous system represent the major outflow pathways. With the evolution of primates, the foramen retroarticulare regressed as the pterygoid plexus increased its functional value [4]. In humans, the petrosquamous sinus, found during embryonic development, usually has disappeared by the time of birth. If this sinus persists, it passes through post-glenoid foramen. In the present study, a skull with post-glenoid foramen was found and discussed.

## METHODS

A total of 100 human adult dried skulls with 200 temporal bones on each side (right and left) which were collected from the Department

of Anatomy at RVS Dental College and Hospital, Coimbatore. The skulls were randomly selected of unknown age and sex. The broken or partly damaged skulls were excluded from the study, only clearly demarcated temporal bones of the skull were included in the study. The selected skulls were placed on a flat table in the dissection hall and the considerable foramen was visually identified by two investigators. The foramen was examined by inserting a probe. The probe is a steel wire measuring about 0.5 mm in diameter and is inserted into the foramen to find out the patency of the foramen. The wire is passed on to the foramen from exterior of the skull and removed it through the interior of the skull cavity to examine the communication between the foramen and the cranial cavity.

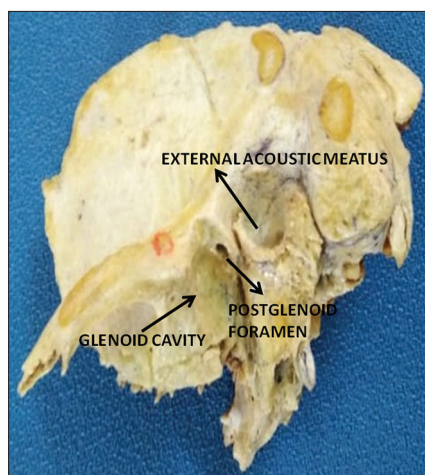
## RESULTS

Of 100 skulls (200 temporal bones), only one skull showed a unilateral post-glenoid foramen on the mandibular fossa of the left side temporal bone (2% of 200). The foramen was found backwards from the glenoid fossa of the temporal bone (Fig. 1). It lies anterior to the external acoustic meatus in the line of fusion of the squamous and tympanic part of the temporal bone. A needle was inserted to see the patency of the foramen. It was a patent opening. Since it was found in dry human skull, the structure passes through it was deemed to be persistent petrosquamous sinus.

## DISCUSSION

The petrosquamous sinus was first described by Knott in 1881 and was named a Knott sinus. It was found in fetal life and developed from a pro-otic group of veins, connecting deep temporal vein to transverse sinus. This sinus runs in the angle between petrous and squamous part of temporal bone and emerges out through post-glenoid foramen [5]. The post-glenoid foramen is an emissary foramen which involves in extracranial venous drainage of the dural venous sinus.

The course of the petrosquamous sinus is that it arises from the dorsolateral portion of the transverse sinus, before the confluence



**Fig. 1: Temporal bone shows post-glenoid foramen**

of the transverse sinus with the superior petrosal sinus. It runs over the lateral superior surface of the petrous bone. It drains either anteroinferiorly into the retromandibular vein through the foramen retroarticulare or anteromedially into the pterygoid venous plexus through the foramen ovale. Until now, its pathway has been described in animals, predominantly in quadrupedal gait. It was rare in humans and is reported only by anthropologists and anatomists. In the present study, a unilateral post-glenoid foramen was observed. Since it was found in adult dry human skull, the structure passes through it may be persistent of petrosquamous sinus.

Conroy observed post-glenoid foramen in about 10% of human cadaver dissections, most often unilaterally. Through this foramen, the petrosquamous sinus is directed into the retromandibular vein and then into the external jugular vein [6]. Boyd observed a post-glenoid foramen in 0.6% of 1400 human skulls examined most of them <1 mm in size, with only one measuring 1.5 mm [7]. Wysocki detected this structure in 3.5% of the human skull with 0.97 mm<sup>2</sup> as mean area [8]. These findings corroborate with the findings of the present study.

Marsot-Dupuch *et al.* reported a radiological description of the petrosquamous sinus associated with a post-glenoid foramen in four cases, using high-resolution computed tomography (CT), complemented by magnetic resonance (MR) venography. These authors suggested that a petrosquamous sinus was most frequently found in patients with congenital malformation of the skull base associated with venous and middle ear anomalies. The surgical procedures in the middle ear cavity or translabyrinthine routes to the posterior fossa may injure the petrosquamous sinus will cause uncontrollable surgical bleeding or post-operative thrombosis of the sigmoid sinus. The surgeons should, therefore, be aware of this venous variant and advise the patient to undergo venous CT angiography or MR angiography in certain cases [9].

Giesemann *et al.* reported post-glenoid foramen measuring more than 5 mm in two cases [10]. Ruiz *et al.* demonstrated a CT angiogram with a post-glenoid foramen in a 7-year-old patient with severe headaches but no inner ear malformation [11]. These studies correlate with the present study that of 100 skulls (200 temporal bones), only one skull showed a unilateral post-glenoid foramen on the mandibular fossa of the left side temporal bone (2% of 200) which may transmit petrosquamous sinus.

## CONCLUSION

Post-glenoid foramen is relatively a rare anatomical variation in human skulls. Knowledge of such variation will be useful for the surgeons while operating middle ear anomalies and while operating posterior cranial fossa.

## AUTHORS' CONTRIBUTIONS

Dr. G. Priya conceptualized, designed, and drafted the manuscript. Mrs. R. Yesodai gathered the data with relevant photographs.

## CONFLICTS OF INTEREST

The authors declare that they have no conflicts of interest.

## AUTHORS' FUNDING

No funding.

## REFERENCES

1. Standring S. *Grays Anatomy. The Anatomical Basis of Clinical Practice.* 39<sup>th</sup> ed. London: Elsevier, Churchill Livingstone; 2006. p. 486-7.
2. Braga J. Emissary canals in the hominoidea and their phylogenetic significance. *Folia Primatol (Basel)* 1995;65:144-53.
3. Williams PC, Warwick R, Dyson M, Banister IH. *Gray's Anatomy.* 37<sup>th</sup> ed. Edinburgh: Churchill Livingstone; 1989. p. 225-6.
4. Reymond J, Charuta A, Wysocki J. The morphology and morphometry of the foramina of the greater wing of the human sphenoid bone. *Folia Morphol (Warsz)* 2005;64:188-93.
5. Alsherhri H, Alqahtani B, Alqahtani M. Dilated petrosquamosal sinus, mastoid emissary vein and external jugular vein: A rare cause of pulsatile tinnitus, vertigo and sensorineural hearing- Case report. *Indian J Otol* 2011;17:123-6.
6. Conroy G. The emissary foramina: Their value in platyrrhine systematic. *Am J Phys Anthropol* 1982;57:7-12.
7. Boyd GI. The emissary foramina of the cranium in man and the anthropoids. *J Anat* 1930;65:108-21.
8. Wysocki J. Morphology of the temporal canal and postglenoid foramen with reference to the size of the jugular foramen in man and selected species of animals. *Folia Morphol (Warsz)* 2002;61:199-208.
9. Marsot-Dupuch K, Gayet-Delacroix M, Elmaleh-Berges M, Bonneville F, Lasjaunias P. The petrosquamous sinus: CT and MR findings of a rare emissary vein. *AJNR Am J Neuroradiol* 2001;22:1186-93.
10. Giesemann AM, Goetz GF, Neuburger J, Ienarz T, Lanfermann H. Persistent petrosquamosal sinus: High incidence in cases of complete aplasia of the semicircular canals. *Radiology* 2011;259:825-53.
11. San Millán Ruiz D, Gailloud P, Yilmaz H, Perren F, Rathgeb JP, Rüfenacht DA, *et al.* The petrosquamosal sinus in humans. *J Anat* 2006;209:711-20.