

PERIARTICULAR REGIONAL ANALGESIA REDUCES PAIN AND HOSPITAL STAY AFTER TOTAL KNEE ARTHROPLASTY: A PROSPECTIVE, RANDOMIZED, AND DOUBLE-BLINDED CONTROLLED TRIAL

PULIN BIHARI DAS*, ANAND KUMAR SINGH, ARINDAM CHATTERJEE, ANURAG SINGH

Department of Orthopedics, Institute of Medical Sciences and SUM Hospital, Siksha 'O' Anusandhan University, Bhubaneswar, Odisha, India. Email: pulin_bdass@yahoo.ca

Received: 21 April 2020, Revised and Accepted: 30 May 2020

ABSTRACT

Objective: There are multiple post-operative pain protocols for patients who undergo total knee arthroplasty (TKA). Post-operative analgesia with opioids or epidural analgesia has its side effect. We compared the duration of hospital stay, pain score, and range of motion of a control group who had no local infiltration with a group who had local infiltration analgesia following TKA.

Methods: Randomization was done in 60 patients who underwent TKA in two groups, one who did not receive and the other who received a multimodal cocktail periarticular injection containing 30 ml of 0.5% bupivacaine, 1 ml of 30 mg ketorolac, 1 ml of 1 in 1000 adrenaline, 2 ml of 80 mg gentamycin, 5 ml of 750 mg cefuroxime, and rest 0.9% of normal saline. Visual analog score (VAS) for pain at rest was recorded and assessed preoperatively and postoperatively at 2, 6, 12, 24, 36 h, 2, 3, and 7 days and during an activity at 24 h, 36 h, 2, 3, and 7 days.

Results: The patient who had received the local injection used very few analgesics over the first 24 h of surgery. Moreover, patients, where local infiltration was used, showed lower VAS for pain (at rest and during activity). They also showed higher VAS for patients' satisfaction.

Conclusion: Due to the reduced post-operative pain with periarticular injection analgesia, it was observed that the pain and duration of hospital stay were significantly reduced.

Keywords: Total knee arthroplasty, Local infiltration, Epidural analgesia, Multimodal cocktail periarticular injection.

© 2020 The Authors. Published by Innovare Academic Sciences Pvt Ltd. This is an open access article under the CC BY license (<http://creativecommons.org/licenses/by/4.0/>) DOI: <http://dx.doi.org/10.22159/ajpcr.2020.v13i7.37933>

INTRODUCTION

Total knee arthroplasty (TKA) is regarded as the most successful operative treatment for advanced osteoarthritis of the knee joint improving quality of life [1]. Following TKA, severe post-operative pain in the first 24 h results in prolonged hospital stay [2]. Thus, adequate pain relief after TKA is one of the topmost priorities in the immediate post-operative period resulting in improvement of patient satisfaction, early rehabilitation and reducing hospital stay duration, and decreasing the risk of post-operative complications such as deep vein thrombosis and pneumonia [3-5].

At present, there are various methods of post-operative analgesia available, which include patient-controlled analgesia (PCA), continuous epidural pump, peripheral nerve block, local intra-articular analgesia, and continuous intra-articular infusion of analgesics, but each having its adverse effects [6-8]. The side effects of spinal/epidural anesthesia are intraoperative hypotension, post-operative headaches, neurogenic bladder, risk of infection of the spine, respiratory depression, and an increase in the total dosage of deep venous thrombosis prophylactic medicines [9]. Regional anesthesia (femoral nerve block/sciatic nerve block) is associated with infection, hematoma formation, risk of neurovascular damage, and narcotics which can lead to nausea, vomiting, respiratory depression, somnolence, urinary retention, and decreased gut motility [10-13]. Continuous intra-articular infusion of analgesics may cause considerable joint effusion and may be a source of infection. Preferably, a multimodal approach of analgesia protocol should be adopted, blocking pain at its origin to prevent complications and side effects while maintaining maximum muscle control for post-operative mobilization and physiotherapy. The use of multimodal cocktail periarticular injection (MCPI) has been reported to be effective in controlling pain, fewer adverse effects, cost-effective, and easy to

use and requires no special training when compared to femoral nerve blocks or epidural anesthesia. Multiple recent studies have documented the efficacy of local infiltration of analgesics for TKA [14,15].

In our study, we used a combination of a local analgesic solution consisting of a nonsteroidal anti-inflammatory drug (ketorolac), a long-acting local anesthetic (bupivacaine), and antibiotics (cefuroxime and gentamycin), with adrenaline, to determine the overall effect of this MCPI on immediate post-operative pain, joint range of motion (ROM), and length of hospital stay after primary TKA.

METHODS

A prospective, randomized, and double-blinded controlled trial was conducted between June 2018 and November 2019, during which 84 consecutive patients with tri-compartmental osteoarthritis were enrolled in the study. After our study had been approved by the Institutional Ethics Committee and patients who had signed an informed consent form were considered eligible for unilateral TKA. The patients were included between 50 and 75 years of age (mean age: 65.8 years) and the range of BMI was 18.5-42.1 kg/m² (mean: 30.2 kg/m²). Patients were excluded if they weighed more than 100 kg, which had a major psychological illness, dependence on alcohol, narcotics, or chronic users of opioids, history of allergy to morphine or any of the drugs being injected, previous history of stroke, uncontrolled angina with prolonged QT intervals or arrhythmia, renal impairment, abnormal coagulopathy, abnormal liver function, rheumatoid arthritis, diabetes mellitus, uncontrolled hypertension, neuromuscular deficit, acute or chronic knee infection, previous knee surgery, previous patellectomy, knee with severe varus and valgus deformity (> than 20°), fixed flexion deformity (>15°), and ROM (<90°) to avoid erroneous assessment of the ROM postoperatively.

Twenty-four patients did not meet the required criteria; hence, they were excluded from the study.

Study design (randomization and blinding)

Participants were randomized into two treatment groups: (A) Intervention group and (B) control group. SPSS Version 20.0 software (SPSS, Chicago, Illinois) was used to create a randomization table by a study coordinator (an independent hospital pharmacist), who prepared and provided the medication for periarticular injection in identical disposable syringes tagged with code numbers. He did not have any involvement in surgery or patient care. A simple random table was used for generating the cards which had a random number sequence and was in sealed envelopes. Odd/even numbers were used by the study coordinator for the allocation of the enrolled patients to Group A/B which was random and double-blinded. The surgeon, nurses, and pharmacists who collected post-operative patients' data were blinded to treatment group allocation. The release of the blinding codes was done subsequently in the data analysis stage.

Spinal anesthesia was given by an anesthetist to all the patients with morphine (0.3 mg) and 3 mL of 0.5% heavy bupivacaine. No epidural anesthesia was used in our patients. All patients were given preoperatively pregabalin 150 mg, intravenous infusion of magnesium at the rate of 50 mg/kg over 30 min (max 3 g) then 15 mg/kg/h till the end of the surgery, and 2 g IV of tranexamic acid as a bolus. Cefuroxime (1.5 g) was given for prophylaxis 30 min before starting the operation. Midazolam (1–2 mg) was given to anxious patients during the operation. A Foleys catheter and tourniquet were used in all our patients. A single surgeon performed all the operations. For all the surgeries, the approach was through an anterior midline incision and standard medial parapatellar arthrotomy. Cemented posterior stabilized total knee prostheses were used in both groups (Zimmer Nexgen: USA). The patella was resurfaced in all cases. Insertion of a non-suction drain was done before the closure of the wound and removal was done after 24 h. Removal of the Foleys catheter was done on post-operative day 1 along with the starting of isometric exercises and ROM. The ambulation of the patients was done with a walker as per their tolerance.

Intervention

Group A (local infiltration group)

A cocktail of 60 ml was prepared under aseptic measure using 30 ml of 0.5% bupivacaine, 1 ml of cefuroxime, and rest 0.9% of normal saline (Table 1).

After lavage of the surgical site, equal doses of the mixture were injected into each of the following eight sites (Fig. 1):

(1) The posterior capsule (Fig. 2), (2) the medial capsular incision (Fig. 3), (3) the lateral capsular incision (Fig. 4), (4) the subcutaneous tissue along both edges of the incision (Fig. 5), (5) the medial collateral ligament, (6) the lateral collateral ligament, (7) the retinacular tissues, and (8) the quadriceps mechanism.

Excessive infiltration was avoided in the area around the common peroneal nerve. Infiltration was done through an 18 gauges needle and was infiltrated before the tourniquet is released. The posterior capsule was injected after the bone cut was done and the remainder of capsular infiltration was done after the final component was implanted and while bone cement was polymerizing.

Group B (control group)

Infiltration of an equal amount of 0.9% normal saline solution was done in the control group as in the intervention group in the same areas and similar techniques.

Both the groups received as follows:

1. Injection amoxicillin (1.2 g) I.V. twice daily
2. Injection cefuroxime (1.5 g) I.V. twice daily

Table 1: Composition of multimodal cocktail injection

| S. No. | Drug | Dose (conc.) | Volume |
|--------|---------------|--------------|--------|
| 1. | Bupivacaine | 0.5% | 30 ml |
| 2. | Ketorolac | 30 mg | 1 ml |
| 3. | Adrenaline | 1:1000 | 1 ml |
| 4. | Gentamycin | 80 mg | 2 ml |
| 5. | Cefuroxime | 750 mg | 5 ml |
| 6. | Normal saline | 0.9% | 21 ml |
| Total | | | 60 ml |

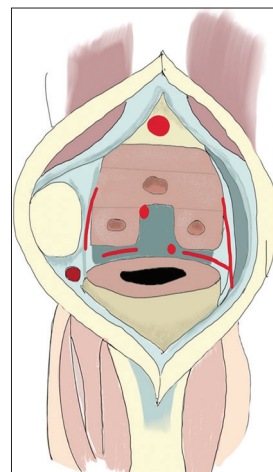


Fig. 1: The eight regions of the knee (marked in red) having increased pain receptors

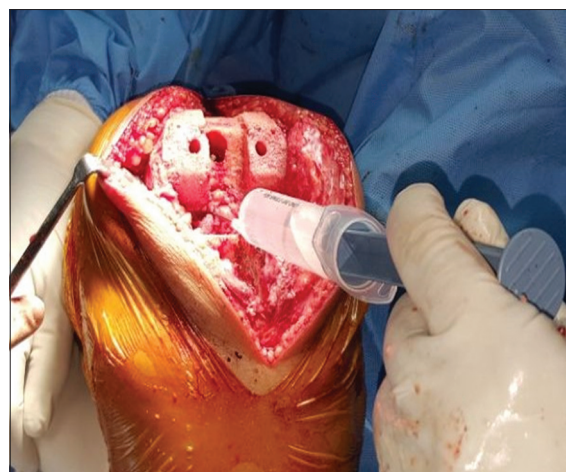


Fig. 2: Multimodal cocktail periarticular injection being infiltrated in the posterior capsule

3. Injection paracetamol (1 g) I.V. thrice daily
4. Injection diclofenac (75 mg) I.V. twice daily
5. Topical cold therapy was given thrice daily until the discharge of the patient
6. For the first 72 h, a sequential compression device was used
7. Low molecular weight heparin (0.3 ml–0.4 ml) was given subcutaneously daily until discharge for the prevention of deep vein thrombosis.

Outcome measures

The follow-up of the patients was done postoperatively and assessed daily during the hospital stay. The recording of the scores was done in a double-blind fashion to make the reviewer uninformed of the side of infiltration as also the patient.

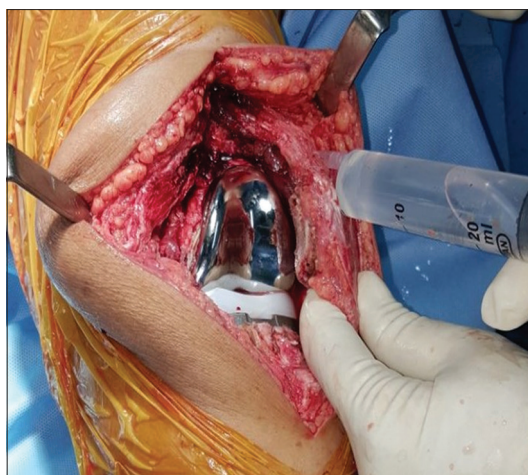


Fig. 3: Multimodal cocktail periarticular injection being infiltrated in the medial capsule

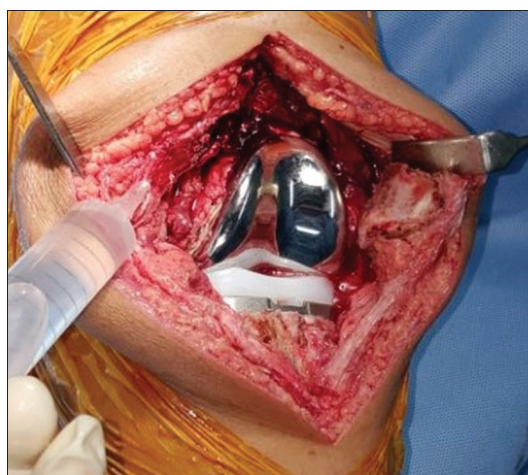


Fig. 4: Multimodal cocktail periarticular injection being infiltrated in the lateral capsule

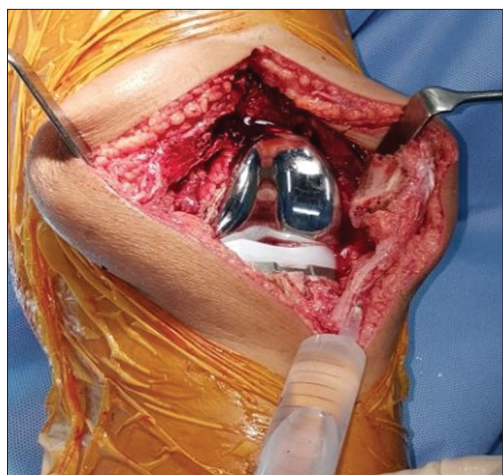


Fig. 5: Multimodal cocktail periarticular injection being infiltrated in the medial aspect of subcutaneous tissue

Primary outcome measure

Pain relief

The collection of data was done by the investigators who were familiar with the assessment methods and those who were not a participant in

the study. Visual analog score (VAS) was used to assess the severity of pre-operative pain both at rest and during activity. Assessment of post-operative pain was done through VAS at 2, 6, 12, 24, and 36 h and on 2nd, 3rd, and 7th days at rest and 24 h, 36 h, 2nd, 3rd, and 7th days during activity. Pre-operative and post-operative ROM was measured on 1st, 2nd, 3rd, and 7th days.

The total amount of paracetamol and diclofenac consumed was recorded for post-operative day 3. The monitoring of patients was done for the adverse effects of bupivacaine, for example, cardiac and central nervous system toxicity. The presence of nausea and vomiting, pruritus, or urinary retention, and somnolence were also determined. The complications which occurred during the trial were recorded, especially surgical site infections, wound condition, and opioid-related complications.

Secondary outcome measures

Duration of hospital stay

The calculation was done from the day of admission and discharge of the patient. Patients were discharged when they fulfilled the following discharge criteria:

- Mild pain (VAS < 3) controlled by oral analgesics
- Independent use of the toilets
- Weight-bearing with walker
- No surgical complications.

ROM

The ROM was assessed by the physiotherapist, who measured the post-operative knee flexion with the help of goniometer on 1st, 2nd, 3rd, and 7th days. Follow-up of all the patients was done on 1, 3, 6, and 12 months postoperatively. Pre-operative and post-operative knee scores were recorded at 1, 3, 6, and 12 months.

Statistical analysis

The mean \pm SD for continuous variables and the frequency and percentage for categorical variables was calculated. Processing of the data was done through SPSS statistical software (version 20.0) (SPSS Inc., USA). Univariate analysis was performed by Chi-square or Fisher's exact test to compare the distribution between categorical data. The Mann-Whitney U-test was done to correlate the non-parametric significant data between two independent samples. $p \leq 0.05$ was considered to be statistically significant.

RESULTS

In our study, we found that the pain score was significantly lower 1st post-operative day in the locally infiltrated group. There was a significant pain score difference on the 2nd and 3rd post-operative days. The decrease in the average maximum pain score in the intervention group was significant as compared to the control group (Figs. 6 and 7). There was no significant difference in the wound complication rate between these groups. There was a significant difference in the ROM until post-operative day 7 and in the mean duration of hospital stay (Figs. 8 and 9).

DISCUSSION

Post-operative pain following TKA is a major problem. The pain is usually due to trauma to soft tissues or bone or hyperperfusion after tourniquet release. Adequate pain relief is essential for early rehabilitation postoperatively. Surgical trauma causes peripheral and central sensitization due to a rise in the excitability of spinal neurons. This causes hypersensitivity and decreases the pain threshold at the operative site. Adrenaline helps in keeping the infiltrated drugs locally and prevents drug toxicity through its vasoconstriction properties. Bupivacaine blocks afferent peripheral nociceptive activity [4,14]. Ketorolac blocks inflammatory cytokines and reduces peripheral sensitization of neurons. Tranexamic acid reduces post-operative bleeding, and pregabalin reduces post-operative pain by binding to $\alpha_2\delta$ unit of presynaptic Ca channel, reducing the release of substance P, 5HT,

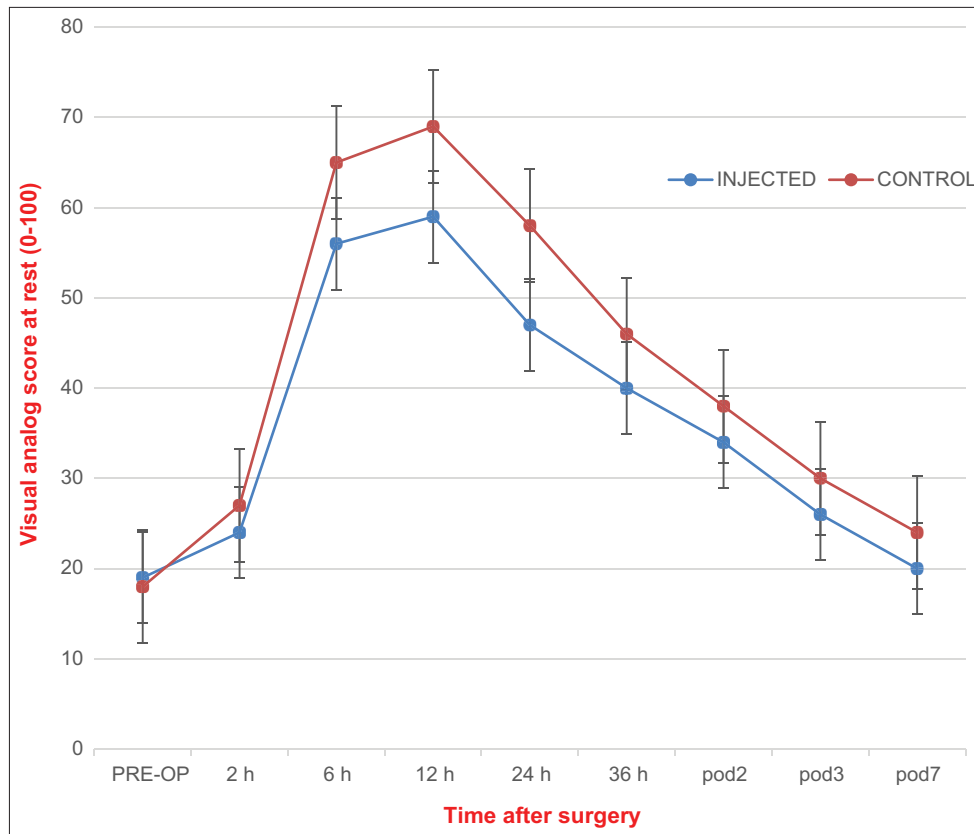


Fig. 6: Pain at rest as measured by a visual analog score in patients who received multimodal cocktail periarticular analgesia (30 patients in the injected group) as compared to (30 patients in the control group). Pre-op: Pre-operative, POD: Post-operative day

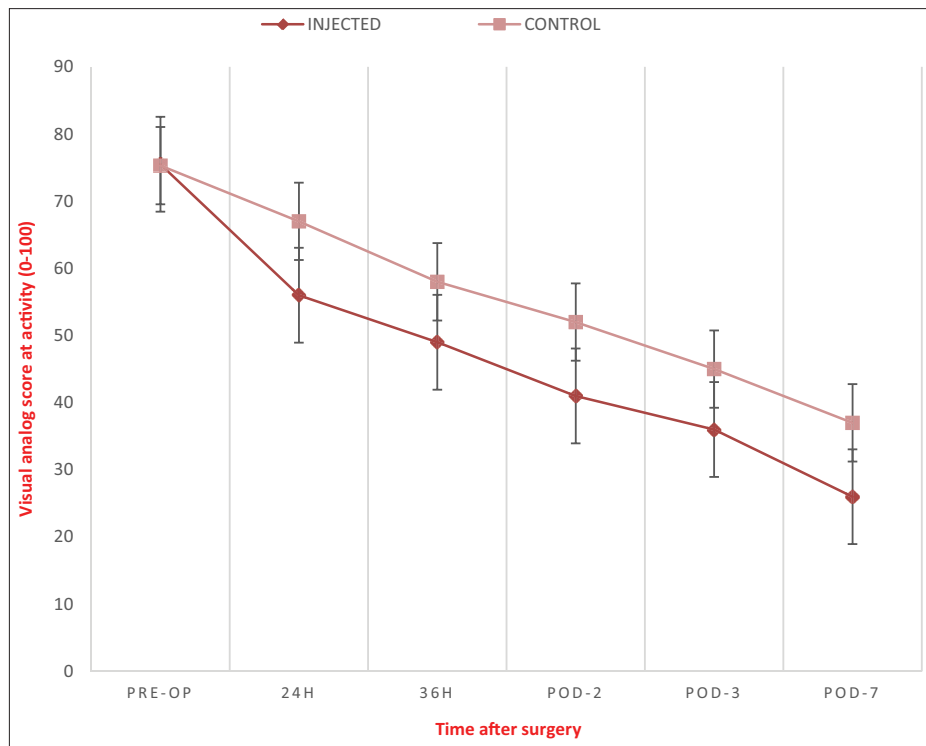


Fig. 7: Pain during activity as measured by a visual analog score in patients who received multimodal cocktail periarticular analgesia (30 patients in the injected group) as compared to (30 patients in the control group). Pre-op: Pre-operative, POD: Post-operative day

noradrenaline, dopamine, and by attenuating postsynaptic excitability. Magnesium reduces post-operative pain by its properties of N-methyl-

d-aspartate (NMDA) receptor antagonist and calcium channel blocker. Magnesium also prevents the induction of central sensitization due to

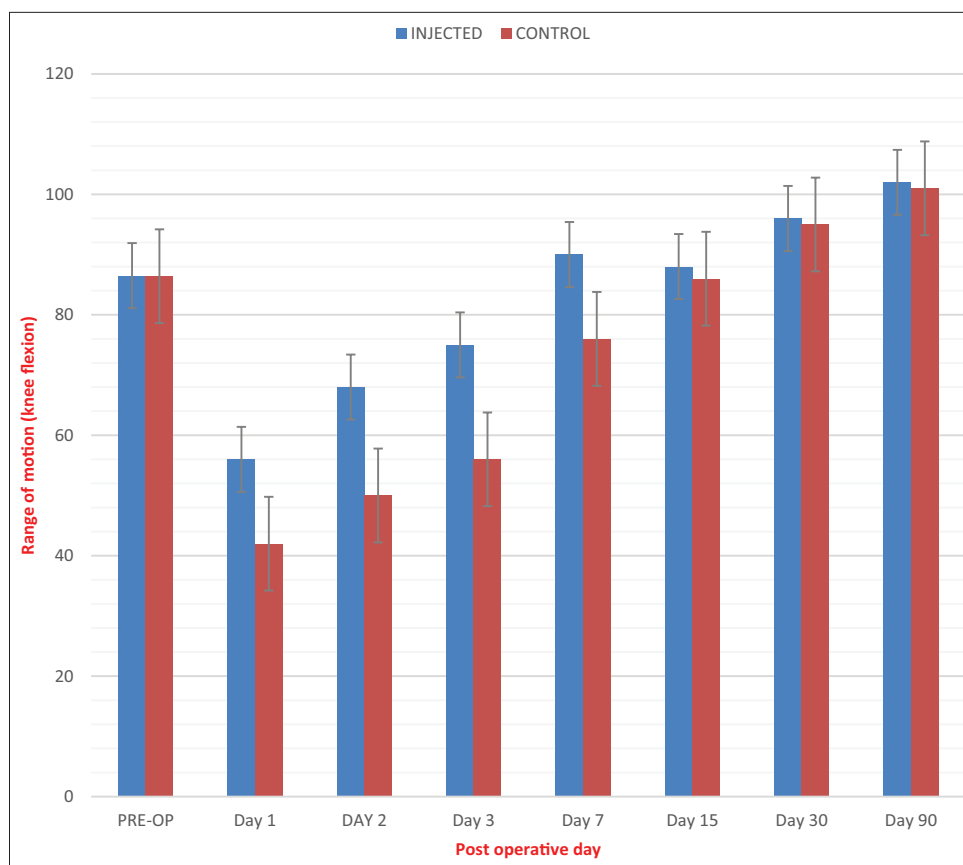


Fig. 8: Range of motion (knee flexion) in patients who received multimodal periarticular analgesia (30 patients in the injected group) as compared to (30 patients in the control group). Pre-op: Pre-operative

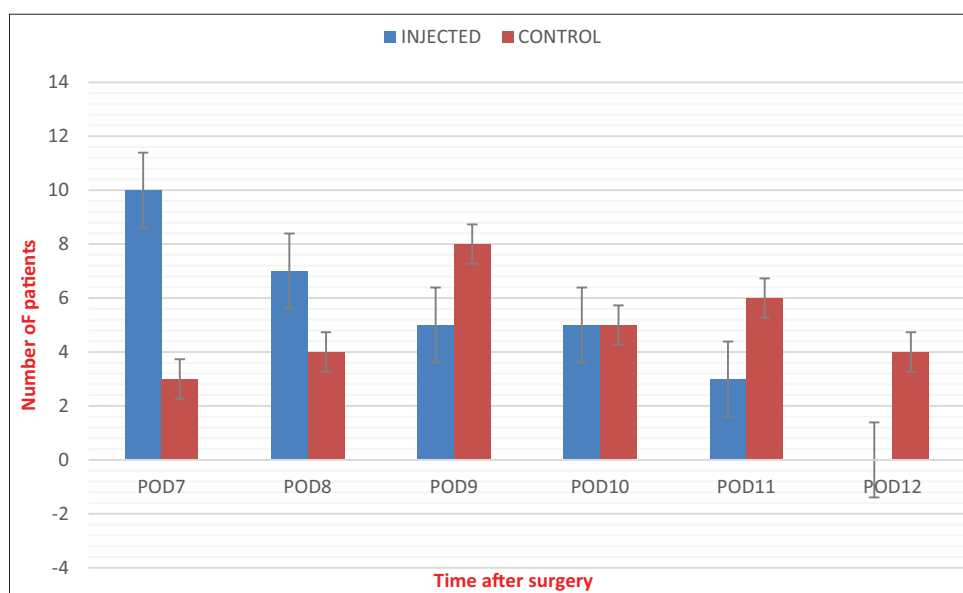


Fig. 9: Duration of hospital stay in patients who received multimodal periarticular analgesia (30 patients in the injected group) as compared to 30 patients in the control group. POD: Post-operative day

peripheral nociceptive stimulation and abolishes hypersensitivity by its antagonism of the NMDA receptor [16,17].

Busch *et al.* studied the efficacy of local perioperative injection with ropivacaine, ketorolac, epinephrine, epimorphine, and normal saline in TKA patients which resulted in a lower pain score and less consumption of analgesics at 12 h after the operation as compared to a control

group [14]. Badner *et al.*, in their study of the effects of intraoperative intra-articular bupivacaine-epinephrine injection in TKA patients, showed a decrease in the consumption of post-operative analgesics with an increase in ROM at discharge in the infiltrated patients, but no significant relief of pain was noted on the addition of morphine to a bupivacaine injection [18]. Vendittoli *et al.* showed a decrease in the use of PCA at 48 h with negligible adverse effects in patients who

underwent intraoperative periarticular infiltration with adrenaline, ketorolac, ropivacaine, and ropivacaine injection (150 mg) on day 1 post-surgery [19]. Parvataneni *et al.* reported that local perioperative infiltration with a cocktail of epinephrine, morphine sulfate, 0.5% bupivacaine, cefuroxime, methylprednisolone acetate, and 0.9% normal saline in joint replacement surgeries resulted in increased satisfaction scores, decreased pain score at 72 h, and reduced hospital stay [20]. Pang *et al.* showed the inclusion of triamcinolone acetonide to the periarticular injection after TKA resulted in immediate and short-term benefits in pain relief and rehabilitation. There was no increase in the risk of infection in this study [21]. Lamplot *et al.* reported a decrease in the duration of hospital stay in the infiltrated group in comparison to the PCA group [22]. Lombardi *et al.* studied the efficacy of soft tissue and intra-articular bupivacaine, morphine, and epinephrine injection in patients who underwent primary TKAs and reported a reduction in the need for rescue doses of narcotic medicines as well as significant pain relief, but nothing significant improvement was found in terms of length of hospital stay and ROM [23]. Mullaji *et al.* studied the effects of an intra-articular analgesic cocktail containing bupivacaine, methylprednisolone, fentanyl, and cefuroxime in patients undergoing bilateral computer-assisted TKA showing significant improvement in pain scores and active flexion up to 4 weeks with quadriceps recovery up to 2 weeks [24].

In our study, the mean VAS in the injected group at rest was 38.25 ± 14.78 and during activity was 41.62 ± 11.59 suggesting significant pain reliefs as compared to the mean VAS of 44.62 ± 17.62 at rest and 51.8 ± 11.56 during activity in the control group. The mean ROM in our study was 82.14 ± 16.41 in the injected group, whereas 72.29 ± 23.17 in the control group. Hence, faster rehabilitation was seen in the injected group. There was a substantial reduction in the duration of hospital stay in the injected group in comparison to the control group in our study.

CONCLUSION

Intraoperative periarticular analgesic injection significantly reduces post-operative pain and reduces the requirement of post-operative analgesics with no apparent risk, following TKA. We observed a lesser length of hospital stay in local analgesia injected group than those who were not injected. The local analgesia infiltrated groups were able to bear weight much earlier than the non-infiltrated group.

AUTHORS' CONTRIBUTIONS

PBD conducted the clinical study, AKS and AC helped PBD in the data analysis and writing the draft copy of the paper. All authors approved the manuscript.

CONFLICTS OF INTEREST

The author declares that there are no conflicts of interest.

AUTHORS' FUNDING

The author received no specific funding for this work.

REFERENCES

- Ng FY, Ng JK, Chiu KY, Yan CH, Chan CW. Multimodal periarticular injection vs continuous femoral nerve block after total knee arthroplasty: A prospective, crossover, randomized clinical trial. *J Arthroplasty* 2012;27:11234-8.
- Wylde V, Rooker J, Halliday L, Blom A. Acute postoperative pain at rest after hip and knee arthroplasty: Severity, sensory qualities and impact on sleep. *Orthop Traumatol Surg Res* 2011;97:139-44.
- Peters CL, Shirley B, Erickson J. The effect of a new multimodal perioperative anesthetic regimen on postoperative pain, side effects, rehabilitation, and length of hospital stay after total joint arthroplasty. *J Arthroplasty* 2006;21:132-8.
- Horlocker TT, Kopp SL, Pagnano MW, Hebl JR. Analgesia for total hip and knee arthroplasty: A multimodal pathway featuring peripheral nerve block. *J Am Acad Orthop Surg* 2006;14:126-35.
- Parvataneni HK, Shah VP, Howard H, Cole N, Ranawat AS, Ranawat CS. Controlling pain after total hip and knee arthroplasty using a multimodal protocol with local periarticular injections: A prospective randomized study. *J Arthroplasty* 2007;22:33-8.
- Ilfeld BM, Mariano ER, Madison SJ, Loland VJ, Sandhu NS, Suresh PJ, *et al.* Continuous femoral versus posterior lumbar plexus nerve blocks for analgesia after hip arthroplasty: A randomized, controlled study. *Anesth Analg* 2011;113:897-903.
- Pagnano MW, Hebl J, Horlocker T. Assuring a painless total hip arthroplasty: A multimodal approach emphasizing peripheral nerve blocks. *J Arthroplasty* 2006;21:80-4.
- Shep D, Khanwelkar C, Gade P, Karad S. A randomized controlled trial of curcumin and diclofenac combination in knee osteoarthritis. *Int J Curr Pharm Sci* 2019;11:111-4.
- Venkatraman R, Sandhiya R. Evaluation of efficacy of epidural butorphanol tartrate for postoperative analgesia. *Int J Pharm Pharm Sci* 2014;7:52-4.
- Sharma S, Iorio R, Specht LM, Davies Lepie S, Healy WL. Complications of femoral nerve block for total knee arthroplasty. *Clin Orthop Relat Res* 2010;468:135-40.
- Horlocker TT, Cabanela ME, Wedel DJ. Does postoperative epidural analgesia increase the risk of peroneal nerve palsy after total knee arthroplasty? *Anesth Analg* 1994;79:495-500.
- Horlocker TT, Wedel DJ. Neuraxial block and low-molecular-weight heparin: Balancing perioperative analgesia and thromboprophylaxis. *Reg Anesth Pain Med* 1998;23:164-77.
- Horlocker TT, Hebl JR, Kinney MA, Cabanela ME. Opioid-free analgesia following total knee arthroplasty--a multimodal approach using continuous lumbar plexus (psoas compartment) block, acetaminophen, and ketorolac. *Reg Anesth Pain Med* 2002;27:105-8.
- Busch CA, Shore BJ, Bhandari R, Ganapathy S, MacDonald SJ, Bourne RB, *et al.* Efficacy of periarticular multimodal drug injection in total knee arthroplasty. A randomized trial. *J Bone Joint Surg Am* 2006;88:959-63.
- Hebl JR, Kopp SL, Ali MH, Horlocker TT, Dilger JA, Lennon RL, *et al.* A comprehensive anesthesia protocol that emphasizes peripheral nerve blockade for total knee and total hip arthroplasty. *J Bone Joint Surg Am* 2005;87 Suppl 2:63-70.
- Vidya VS, Felicita AS. Efficacy of pharmacological agents in the treatment of temporomandibular joint disorder: A systematic review. *Int J Pharm Pharm Sci* 2015;7:54-8.
- Dubé L, Granry JC. The therapeutic use of magnesium in anesthesiology, intensive care and emergency medicine: A review. *Can J Anaesth* 2003;50:732-46.
- Badner NH, Bourne RB, Rorabeck CH, MacDonald SJ, Doyle JA. Intra-articular injection of bupivacaine in knee-replacement operations. Results of use for analgesia and for preemptive blockade. *J Bone Joint Surg Am* 1996;78:734-8.
- Vendittoli PA, Makinen P, Drolet P, Lavigne M, Fallaha M, Guertin MC, *et al.* A multimodal analgesia protocol for total knee arthroplasty. A randomized, controlled study. *J Bone Joint Surg Am* 2006;88:282-9.
- Parvataneni HK, Ranawat AS, Ranawat CS. The use of local periarticular injections in the management of postoperative pain after total hip and knee replacement: A multimodal approach. *Instr Course Lect* 2007;56:125-31.
- Pang HN, Lo NN, Yang KY, Chong HC, Yeo SJ. Peri-articular steroid injection improves the outcome after unicondylar knee replacement: A prospective, randomised controlled trial with a two-year follow-up. *J Bone Joint Surg Br* 2008;90:738-44.
- Lamplot JD, Wagner ER, Manning DW. Multimodal pain management in total knee arthroplasty: A prospective randomized controlled trial. *J Arthroplasty* 2014;29:329-34.
- Lombardi AV Jr., Berend KR, Mallory TH, Dodds KL, Adams JB. Soft tissue and intra-articular injection of bupivacaine, epinephrine, and morphine has a beneficial effect after total knee arthroplasty. *Clin Orthop* 2004;428:125-30.
- Mullaji A, Kanna R, Shetty GM, Chavda V, Singh DP. Efficacy of periarticular injection of bupivacaine, fentanyl, and methylprednisolone in total knee arthroplasty: A prospective, randomized trial. *J Arthroplasty* 2010;25:851-7.