

CORONAVIRUS DISEASE 2019 AND MUCORMYCOSIS A GLOBAL THREAT: A SYSTEMIC REVIEW**BIKASH BISWAS^{1*}, INDRANI PRAMANIK², SANJUKTA MANDAL³, POULAMY SINGHA ROY³**

¹Department of Case Taking and Repertory, Mahesh Bhattacharyya Homoeopathic Medical College and Hospital, Howrah, West Bengal, India. ²Department of Physiology and Biochemistry, Mahesh Bhattacharyya Homoeopathic Medical College and Hospital, Howrah, West Bengal, India. ³Department of Materia Medica, Mahesh Bhattacharyya Homoeopathic Medical College and Hospital, Howrah, West Bengal, India. Email: bikash21592@gmail.com

Received: 01 June 2021, Revised and Accepted: 10 July 2021

ABSTRACT

Objectives: According to the recent studies, it is seen that coronavirus disease 2019 (COVID-19) infection is associated with many bacterial and fungal infections. In case of COVID-19 patients, diabetes mellitus (DM) and hypertension (HTN) are the prime risk factors and during the course of treatment, patients develop secondary fungal infections like mucormycosis. We conducted a systemic review of the present scenario and tried to evaluate the association of mucormycosis with COVID-19.

Methods: We searched articles related to the COVID-19 associated mucormycosis, in PubMed, IndMed, and Cochrane Library. We conducted a meta-analysis on the basis of systemically reviewed all articles which reported COVID-19 associated with mucormycosis. We analyzed comorbidity, treatment, and outcome of patients in association with COVID-19 and mucormycosis.

Results: We found a total of 196 articles based on mucormycosis, out of which only 25 were selected on the basis of our inclusion and exclusion criteria. 71 cases were found and most of the cases were from India and USA. We also found that it was more prevalent among male patients and patients with DM, and in association with HTN.

Conclusion: It is seen from the studies that patients already suffering from DM and HTN when infected with coronavirus are most likely to develop mucormycosis. Treatment of latent DM, prediabetic patients, conversely, that efforts to diagnose, detect, and treat DM may have a beneficial influence in the treatment of secondary fungal infections like mucormycosis. Finding out all the cases of DM and treatment of DM can carry out an advantageous effect in all patients suffering from COVID-19.

Keywords: Coronavirus disease 2019, Mucormycosis, Comorbidities, Diabetes mellitus.

© 2021 The Authors. Published by Innovare Academic Sciences Pvt Ltd. This is an open access article under the CC BY license (<http://creativecommons.org/licenses/by/4.0/>) DOI: <http://dx.doi.org/10.22159/ajpcr.2021v14i8.42262>. Journal homepage: <https://innovareacademics.in/journals/index.php/ajpcr>

INTRODUCTION

The pandemic coronavirus disease 2019 (COVID-19) has spread vastly on a global scale [1,2]. There is no definitive treatment of the disease till now. However, prevention and symptomatic management is the prime choice. COVID-19 patients suffer from various secondary infections such as pneumonia, severe respiratory disease, and heart complication but super-infections and co-infections in COVID-19 pneumonia are still under exploration [3]. Secondary infections are more common in severely ill COVID-19 patients, fungal infections being 10 times more common [3]. Severe complication of coronavirus disease with secondary infection with fungus is very dangerous and life threatening to patients. This is the black fungus disease that is known as mucormycosis. Steroids and other immunosuppressive drugs are being used in the treatment of COVID-19 which is resulting into further complications. The side effects include increased secondary infections, immune modulation, manifestation of latent diabetes mellitus (DM), dizziness, weight gain, mood changes, insomnia, and muscle weakness [4]. The incidence rate of mucormycosis globally is 0.005–1.7 per million [5]. In Indian population, its prevalence is 0.14 per 1000, which is about 80% higher than other developed countries [6]. The fatality rate of mucormycosis is 46% worldwide [7]. Mucormycosis is also known as Zygomycosis and now it's called black fungus disease [8]. It's a serious fungal infection disease which is a secondary complication of coronavirus disease. It mostly infects sinuses, brain causing headache, epistaxis, fever, etc. [9]. Patient who is already suffering from diabetes, blood disorders, AIDS, or has history long-term use of steroids are prone to be affected with secondary infection of mucormycosis [10].

The objective of systemic review and meta-analysis on mucormycosis associated with COVID-19 disease this study to provide better understanding and evaluation of mucormycosis or zygomycosis. It will help in the better treatment of such fungal infections.

METHODS

This systemic review has been done to know the possible total cases of mucormycosis associated with novel coronavirus disease all around the world and specially India. The search of literature was done by the electronic database of PubMed, Cochrane library, IndMed from the 2019 to 2021, using the search word- COVID-19 and mucormycosis. We conducted the meta-analysis on the basis of screening and recuperate all the papers for title and abstract, after that primary selection then full texts of the conversant studies was perused for the study. The eligibility criteria were:

- Studies on COVID-19 associated with mucormycosis
- Studies that were published all over the world in related to study keyword
- Studies dealing with patients of mucormycosis
- Studies were published after 2019 (after attack of COVID-19).

We exclude the:

- Review articles on mucormycosis
- Narrative article
- Literature review
- Study with less data.

These were the criteria for selection the studies which were included in the meta-analysis for better quality. All the data were extracted for

eligible study - author, year of publication, state or country, patient reported with mucormycosis, number of patient suffering from mucormycosis, co-morbidity or history of any kind of disease, COVID positive, management, discussion, and extracted in Tables 1 and 2. Data

Table 1: Summary of studies

Author	Year of publication	Country/state	Patient reported with mucormycosis	No of patients who suffering from mucormycosis	Co morbidity/ past history of any kind of disease	COVID-19 Positive
Maini et al. [11]	2021	India (Mumbai)	COVID associated with orbital mucormycosis	38-year-old male patient	No significant past history	Yes
Johnson et al. [12]	2021	USA	COVID associated with pulmonary aspergillosis is and possible mucormycosis	79-year-old male patient	history of diabetes and hypertension (HTN) on	Yes
Pasero et al. [13]	December 2020	Italy	COVID associated with pulmonary mucormycosis and multiple organ dysfunction syndrome with sequential organ failure assessment t (SOFA)	66-year-old male patient	history of HTN on and urinary tract infection	yes
Mehta and Pandey [14]	September 2020	India	COVID with rhino orbital mucormycosis	60-year-old male patient	Patient was diabetic	yes
Garg et al. [15]	February 2021	Chandigarh, India	COVID associated with pulmonary Mucormycosis	55-year-old male	long standing diabetes with HTN with ischemic heart condition and end stage of renal disease	Yes
Monte Junior et al. [16]	September 2020	Saopaulo, Brazil	COVID associated with gastrointestinal mucormycosis (n=23) were associated with mucormycosis (orbital, paranasal)	86-year-old male (n=23) 1.(n=15) male 2. (n=8) female	1. (n=21) patients were diabetic. (out of 21), (n=14) patients had history of HTN with DM and n=7 was purely diabetic) 2. (n=1) renal failure 3. (n=1) no history	yes
Sharma et al. [17]	2021	Jaipur, India				All patients were positive
Alekseyev et al. [18]	2021	USA	COVID with cerebral mucormycosis	41-year-old male patient	Diabetic	yes
Revannavar et al. [19]	April 2021	India	COVID positive associated with rhino orbital mucormycosis	Middle aged female	DM	Yes
Saldanha et al. [20]	April 2021	Karnataka, India	COVID positive associated with Paranasal Mucormycosis	32-years-old female	Uncontrolled diabetes mellitus	yes
Werthman-Ehrenreich [7]	2020	USA	COVID associated orbital mucormycosis	33-years-old female	History of HTN on and asthma	Yes
Aljehani et al. [21]	February, 2021	Saudi Arabia	COVID associated auricular mucormycosis	18-month-old girl child	Diabetic child	Yes
Veisi et al. [22]	March, 2021	Tehran, Iran	COVID associated rhino orbital mucormycosis	(n=2), 1.40-year-old female, 2.54-year-old male	(n=1) No particular history for the female subject. (n=1) For the male patient he was well controlled non-insulin dependent DM patient had a history of insulin dependent diabetes, asthma, HTN on, hyperlipidemia	Yes both
Mekonnen et al. [23]	2021	USA	COVID positive with rhino orbital mucormycosis	60-year-old male patient	Poorly controlled diabetes	Yes
Ahmadikia et al. [24]	2021	Tehran, Iran	Influenza with mucormycosis (suspected COVID-19 infection)	44-year-old female	hyperlipidemia	Suspected
Sen et al. [25]	February 2021	India	COVID associated with cerebral mucormycosis	(n=6) patients. (47- 74 years old). All male	1.All 6 patients had history of DM and HTN (n=6) 2. (n=1) purely DM	All positive.
Placik et al. [26]	October, 2020	India	COVID associated with pulmonary mucormycosis	49-year-old male	No particular history	yes
Sebastian et al. [27]	February 2021	India	COVID associated with sinuses (paranasal) mucormycosis	(n=3) patients 1.59-year-old male, 2.60-year-old male, 3.64-year-old male	1. (n=1) Well controlled DM 2. (n=1) DM 3. (n=1) DM with peptic ulcer	All positive
Bellanger et al. [28]	2021	France	COVID associated with pulmonary mucormycosis	55-year-old male	No significant history	Yes.

(Contd...)

Table 1: (Continued)

Author	Year of publication	Country/state	Patient reported with mucormycosis	No of patients who suffering from mucormycosis	Co morbidity/ past history of any kind of disease	COVID-19 Positive
Karimi-Galougahi <i>et al.</i> [29]	March 2021	Iran	COVID associated with paranasal mucormycosis	61-year-old women	No particular history	Yes
Zurl <i>et al.</i> [30]	January 2021	Austria	COVID associated with pulmonary mucormycosis (autopsy)	53-year-old male	Acute myeloid leukemia, obesity, depression	yes
Sargin <i>et al.</i> [31]	February 2021	Turkey	COVID associated with rhinocerebral mucormycosis	56-year-old female	A History of anxiety, hyperglycemia	Yes
Hatri <i>et al.</i> [32]	April 2021	USA	COVID associated with pulmonary mucormycosis	(n=8) 1.7 were male 2.One female	1. (n=1) Heart transplant, Stage 2 heart failure, DM, HTN, chronic kidney disease. 2. (n=1) DM 3. (n=1) HTN with asthma 4. (n=1) obesity with hypothyroidism 5. (n=1) HTN 6. (n=1) no history. 7. (n=1) DM, asthma, HTN 8. (n=1) HTN	Yes
Mishra <i>et al.</i> [33]	May 2021	India	COVID associated with rhino orbital mucormycosis	(n=10) patients, 1.9male 2.one female (The mean age was 55.8 years)	8 were diabetic 1. (n=3) DM 2. (n=1) DM with HTN and IHD. 3. (n=1) Diabetes with hypothyroidism. 4. (n=1) no past medical history. 5. (n=1) CKD, DM, HTN, hypothyroidism. 6. (n=1) DM with HTN 7. (n=1) CKD. 8. (n=1) DM with CLD. (n=1) Obesity	Yes
Waizel-Haiat <i>et al.</i> [34]	February 2021	Mexico	COVID associated with rhino orbital mucormycosis	24 year old female	(n=1) Obesity	

COVID-19: Coronavirus disease 2019, DM: Diabetes mellitus, HTN: Hypertension, CKD: Chronic kidney disease, CLD: Chronic liver disease.

of comorbidity are presented in Tables 3 and 4, country wise data are presented in Table 3. Outcomes have been showed in four categories in Table 5. Sex ration is shown in Table 6. All data were thoroughly checked by four reviewers (Figs. 1 and 2).

RESULTS

We have conducted the meta-analysis on 25 articles which were found to related studies from PubMed (n=23), IndMed (n=1), and Cochrane library (n=1). We have presented the search data, on the basis of inclusion, exclusion, title abstract screening, full test screening, and the finally selected articles included for the study. Our total search was 196, 25 were included in meta-analysis, which have mentioned our key search with COVID-19 and mucormycosis. There were total 71 cases found who had presented COVID-19 associated with mucormycosis. In India, there was most of cases were found (n=48) (67.60%), in USA (n=12) cases were found (16.90%), in Iran four cases were found (n=4) (5.63%), in Italy, France, Austria, Saudi Arabia, Mexico, turkey, and brazil each country found one case of COVID 19 associated with mucormycosis. Comorbidity with age variation also presented in schematic format, where only DM was mostly associated as pre disposing factor (29.57%) (n=21). HTN (n=3) (4.22%), HTN with DM (n=21) (29.57%), HTN with asthma (n=2) (2.81%), obesity (n=1) (1.40%), anxiety, and depression (n=1) (1.42%) were also associated as pre disposing factor. There was (n=8) (11.26%) patients who had

no medical history. There were almost all cases associated with DM (n=10) with other systemic cause. There was male predominance seen in this study (n=52) (73.29%), female was (n=19) (26.76%). Moreover, the final outcome of each study has been divided in four categories, improvement (n=36) (51.42%), no improvement (n=8) (11.26%), died (n=24) (33.80%), raise complication (n=2) (2.81), and lost follow-up (n=1) (1.40%).

DISCUSSION

Our meta-analysis shows that DM increases the risk of mucormycosis associated with COVID-19, regardless of different study designs, background mucormycosis associated with COVID-19 incidence, or geographic region of the study. The studies reveal that compared with people who do not have diabetes those also were affected by mucormycosis. (29.57%) (n=21). HTN (n=3) (4.22%), HTN with DM (n=21) (29.57%) HTN with asthma (n=2) (2.81%), obesity (n=1) (1.40%), anxiety, and depression (n=1) (1.42%) were also associated as pre disposing factor. There was (n=8) (11.26%) patients who had no medical history. There were almost all cases associated with DM (n=10) with other systemic cause. People with diabetes have an increased risk of developing active mucormycosis associated with COVID-19. Higher increases in risk were seen among male, in populations with high background mucormycosis associated with COVID-19, and in Indian population populations. The mortality rate was (33.80%)

Table 2: Summary treatment and outcome

Author	Mucormycosis positive	Treatment	Inference
Maini et al. [11]	yes (MRI brain)	FESS was done followed by surgical debridement	Patient was discharged after 38 days with satisfied improvement
Johnson et al. [12]	yes (BAL)	Antifungal treatment, undergone tracheostomy and percutaneous endoscopic gastrostomy	Patient was discharged after 36 th day
Pasero et al. [13]	yes (BAL)	Symptomatic antifungal treatment, surgical intervention was not done	Patient died after 62 th day after hospitalization
Mehta and Pandey [14]	yes (computed tomography (CT) scan)	Symptomatic treatment, surgical intervention was not done	Patient died on 6 th day after hospitalization
Garg et al. [15]	yes (MALDI- TOF)	Symptomatic treatment, surgical intervention was not done	Patient was discharged after 54 th day
Monte Junior et al. [16]	yes (EGD)	There was no chance to treat the patient	Patient died 7 days following hospitalization
Sharma et al. [17]	yes (tomography scan of paranasal sinuses)	Observational study (use steroids during the course of the treatment)	All patient were observed and managed
Alekseyev et al. [18]	yes (chest CT)	A wide maxillary antrostomy, sphenoidotomy, and	Patient was discharged after therapy
Revannavar et al. [19]	yes (histopathology followed by FESS)	FESS was done on emergency basis. Her sugars were well controlled after the initiation of insulin therapy. However, there was no resolution of ophthalmoplegia or ptosis until she was discharged	Patient was discharged after 17 days
Saldanha et al. [20]	yes (MRI brain)	Endoscopic sinus surgery without debridement	Her COVID test was positive after 14 days. She was discharged as per her request, follow- up taken on phone, and she reported that she was improving her facial pain and but no improvement of vision
Werthman-Ehrenreich [7]	yes (CT scan of face)	Symptomatic treatment, surgical intervention was not done	Patient passed away after 27 days
Aljehani et al. [21]	yes (MRI brain)	Extensive surgical debridement	Monthly follow-ups showed improvement
Veisi et al. [22]	yes (orbital CT scan) for both patients	Endoscopic debridement was done for case 1. endoscopic sinus surgery and removal of necrotic tissue from paranasal sinus for case 2	For case 1 patient died after 3 months in spite of regular follow-up. For case 2, 7 months follow-up was done with no active infections
Mekonnen et al. [23]	yes (histopathological)	Endoscopic surgical debridement was done	Patient was died on 31 th day on hospital
Ahmadikia et al. [24]	yes (CT scan of paranasal sinuses)	Symptomatic treatment	After 8 months follow-up the patient showed no evidence of mucormycosis
Sen et al. [25]	Yes (culture and histopathology)	Endoscopic sinuses surgery was done in all patients	All patients were stable after 0–1.9 months of treatment
Placik et al. [26]	Yes (CT scan of chest)	Cardiothoracic surgery was done, followed by right middle thoracotomy for repairing fistula	After 33 days in hospital patient get worse and had respiratory failure and septic shock. Rhizopus was still positive
Sebastian et al. [27]	Yes (KOH and CT of paranasal sinus) both cases	Case 1. symptomatic treatment Case 2. Antifungal treatment and symptomatic	Case1. Died due to cardiac arrhythmia and myocarditis. Case 2. 10 th day patient died due to massive peptic ulcer disease and developed shock
Bellanger et al. [28]	Yes (BAL)	Symptomatic treatment	Patient died at day 40 th day of hospitalization
Karimi-Galougahi et al. [29]	Yes (noncontract CT of paranasal sinuses)	Extensive endonasal endoscopic debridement was done	Right eye exenteration. stable
Zurl et al. [30]	Yes (BAL- GM)	Autopsy	After 24 th day
Sargin et al. [31]	Yes (culture study)	Tracheostomy done on 3 rd day, followed by symptomatic antifungal treatment was done	Patient died on 10 th day of hospitalization
Hatri et al. [32]	Yes (culture, biopsy)	Symptomatic treatment	8 patients were died
Mishra et al. [33]	Yes (FESS)	FESS followed local debridement – 8	4 were died
		One case handled with symptomatic treatment	5 ere improved
		One case undergone endoscopic maxillectomy	One case lost to follow-up
Waizel-Haiat et al. [34]	Yes (contrast enhanced CT of head and chest)	Symptomatic treatment and surgical debridement	Died due to metabolic acidosis, pulmonary insult, intravascular coagulopathy and finally multi organ failure

patients with mucormycosis. Heterogeneity of strengths of association may reflect true geographic/ethnic differences in severity of DM,

transmission dynamics of mucormycosis associated with COVID-19, and the distribution of effect modifiers such as country, or it may be

Table 3: Country wise studies

Country	Patient Population	Percentage	Total patients
India	n=48	67.60	n=71
USA	n=12	16.90	
Iran	n=4	5.63	
France	n=1	1.40	
Saudi Arabia	n=1	1.40	
Austria	n=1	1.40	
Mexico	n=1	1.40	
Italy	n=1	1.40	
Turkey	n=1	1.40	
Brazil	n=1	1.40	

Table 4: Co morbidity and age ratio

Co morbidity and features	Patient population	Percentage	Total patients
only DM	n=21	29.57	n=71
only HTN	n=3	4.22	
diabetes with HTN	n=21	29.57	
HTN UTI	n=1	1.40	
HTN with asthma	n=2	2.81	
renal failure	n=1	1.40	
DM, HTN, asthma and hyperlipidaemia	n=1	1.40	
DM with peptic ulcer	n=1	1.40	
AML, obesity and depression	n=1	1.40	
no particular history	n=8	11.26	
anxiety with DM	n=1	1.40	
HTN, CKD, DM, heart failure	n=1	1.40	
obesity with hypothyroidism	n=1	1.40	
DM, HTN, asthma	n=1	1.40	
DM, HTN, IHD	n=1	1.40	
DM with hypothyroidism	n=1	1.40	
CKD, DM, HTN, and hypothyroidism	n=1	1.40	
CKD	n=1	1.40	
DM with CLD	n=1	1.40	
obesity	n=1	1.40	
DM, HTN, IHD, and renal disease	n=1	1.40	

DM: Diabetes mellitus, HTN: Hypertension, CKD: Chronic kidney disease, CLD: Chronic liver disease.

Table 5: Outcome

Category	Patient Population	Percentage	Total Patients
No improvement	n=8	11.26	n=71
Died	n=24	33.80	
Complication occurs	n=2	2.85	
Improvement	n=36	50.70	
Lost follow-up	n=1	1.40	

Table 6: Male and female population

Male	n=52	73.29%
Female	n=19	26.76%
Total population	n=71	

due to differences in study methodology or rigor. Our systematic review identified five additional studies that were HTN, HTN with asthma, and other systemic disease (CKD, CLD, obesity, hypothyroidism, anxiety, and renal failure), that had examined the association of DM and mucormycosis associated with COVID-19 and determined important sources of heterogeneity through rigorous sensitivity analyses.

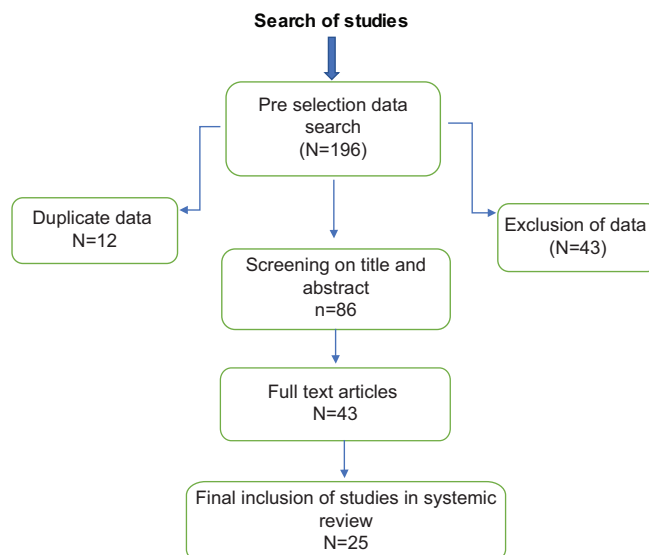


Fig. 1: Study selection schema

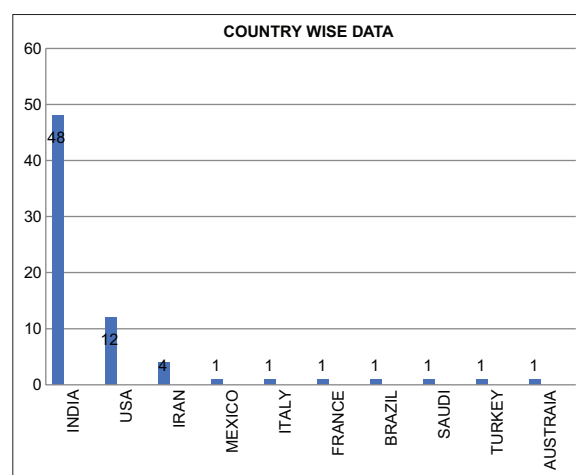


Fig. 2: Country wise chart

CONCLUSION

In summary, we found consistent evidence for an increased risk of mucormycosis associated with COVID-19 among people with diabetes despite heterogeneity in study design, geographic area, underlying burden of mucormycosis, assessment of exposure and outcome, and control of potential confounders. Data from these human studies are consistent with emerging information on the biological mechanisms by which hyperglycemia may affect the host immune response to mucormycosis associated with COVID-19. Our findings suggest that fungal controls programs should consider targeting patients with diabetes with COVID-19 for interventions such as active case finding and the treatment of latent DM and, conversely, that efforts to diagnose, detect, and treat DM may have a beneficial impact on fungal control. We also recommend further studies investigating how comorbidity risk varies by type, duration, and severity of mucormycosis associated with COVID-19, for a more thorough understanding of the association that could be translated to a clear public health message.

ACKNOWLEDGMENTS

None.

AUTHOR'S CONTRIBUTION

Dr. Bikash Biswas: Concept, Study design, collection of data, Statistical analysis, original manuscript writing, writing-review and editing.

Dr. Indrani Pramanik: Statistical drift and writing-review and editing and all over guidance. Dr. Sanjukta Mandal: Data collection. Chart analysis and writingreview and editing. Dr. Poulamy Singha Roy: Data collection. writing-review and editing.

CONFLICT OF INTEREST

There is no conflict of interest.

FUNDING

No funding received for this study.

REFERENCES

- Jayaweera M, Perera H, Gunawardana B, Manatunge J. Transmission of COVID19 virus by droplets and aerosols: A critical review on the unresolved dichotomy. *Environ Res* 2020;188:109819.
- Modes of Transmission of Virus Causing COVID-19: Implications for IPC Precaution Recommendations. Available from: <https://www.who.int/news-room/commentaries/detail/modes-of-transmission-of-virus-causing-covid-19-implications-for-ipc-precaution-recommendations>.
- Superinfections and Coinfections in COVID-19 MedPage Today. Available from: <https://www.medpagetoday.com/infectiousdisease/covid19/86192>.
- Methylprednisolone for Patients with COVID-19 Severe Acute Respiratory Syndrome-full Text View. Available from: https://www.clinicaltrials.gov/ct2/show/NC_T04323592.
- Jeong W, Keighley C, Wolfe R, Lee WL, Slavin MA, Kong DC, et al. The epidemiology and clinical manifestations of mucormycosis: A systematic review and meta-analysis of case reports. *Clin Microbiol Infect* 2019;25:26-34.
- Chander J, Kaur M, Singla N, Punia R, Singhal S, Attri A, et al. Mucormycosis: Battle with the deadly enemy over a five-year period in India. *J Fungi* 2018;4:46.
- Werthman-Ehrenreich A. Mucormycosis with orbital compartment syndrome in a patient with COVID-19. *Am J Emerg Med* 2020;42:264.e5-8.
- National Organization for Rare Disorders. Available from: <https://rarediseases.org/rare-diseases/mucormycosis/>. [Last accessed on 2021 May 25].
- Grossman ME, Fox LP, Kovarik C, Rosenbach M. Subcutaneous and deep mycoses: Zygomycosis/mucormycosis. In: *Cutaneous Manifestations of Infection in the Immunocompromised Host*. 2nd ed. Germany: Springer; 2012. p. 51-8. Available from: <http://www.wikipedia>.
- Maini A, Tomar G, Khanna D, Kini Y, Mehta H, Bhagyasree V. Sino-orbital mucormycosis in a COVID-19 patient: A case report. *Int J Surg Case Rep* 2021;82:105957.
- Johnson AK, Ghazarian Z, Cendrowski KD, Persichino JG. Pulmonary aspergillosis and mucormycosis in a patient with COVID-19. *Med Mycol Case Rep* 2021;32:64-7.
- Pasero D, Sanna S, Liperi C, Piredda D, Branca GP, Casadio L, et al. A challenging complication following SARS-CoV-2 infection: A case of pulmonary mucormycosis. *Infection* 2020;2020:1-6.
- Mehta S, Pandey A. Rhino-orbital mucormycosis associated with COVID-19. *Cureus* 2020;2020:10726.
- Garg D, Muthu V, Sehgal IS, Ramachandran R, Kaur H, Bhalla A, et al. Coronavirus disease (Covid-19) associated mucormycosis (CAM): Case report and systematic review of literature. *Mycopathologia*. 2021;186:289-98.
- Monte Junior ES, Santos ME, Ribeiro IB, Luz GO, Baba ER, Hirsch BS, et al. Rare and fatal gastrointestinal mucormycosis (zygomycosis) in a COVID-19 patient: A case report. *Clin Endosc* 2020;53:746-9.
- Sharma S, Grover M, Bhargava S, Samdani S, Kataria T. Post coronavirus disease mucormycosis: A deadly addition to the pandemic spectrum. *J Laryngol Otol* 2021;2021:1-6.
- Alekseyev K, Didenko L, Chaudhry B. Rhinocerebral mucormycosis and COVID-19 pneumonia. *J Med Cases* 2021;12:85-9.
- Revannavar SM, Supriya PS, Samaga L, Vineeth VK. COVID-19 triggering mucormycosis in a susceptible patient: A new phenomenon in the developing world? *BMJ Case Rep* 2021;14:e241663.
- Saldanha M, Reddy R, Vincent MJ. Paranasal mucormycosis in COVID-19 patient. *Indian J Otolaryngol Head Neck Surg* 2021; 2021:1-4.
- Aljehani M, Alahmadi H, Alshamani M, A case report of complete resolution of auricular mucormycosis in an 18-month-old diabetic child. *Case Rep Otolaryngol* 2021;2021:6618191.
- Veisi A, Bagheri A, Eshaghi M, Rikhtehgar HM, Kanavi RM, Farjad R. Rhino-orbital mucormycosis during steroid therapy in COVID-19 patients: A case report. *Eur J Ophthalmol* 2021.
- Mekonnen ZK, Ashraf DC, Jankowski T, Grob SR, Vagefi MR, Kersten RC, et al. Acute invasive rhino-orbital mucormycosis in a patient with COVID-19-associated acute respiratory distress syndrome. *Ophthalmic Plast Reconstr Surg* 2021;37:e40-80.
- Ahmadikia K, Hashemi SJ, Khodavaisy S, Getso MI, Alijani N, Badali H, et al. The double-edged sword of systemic corticosteroid therapy in viral pneumonia: A case report and comparative review of influenza-associated mucormycosis versus COVID-19 associated mucormycosis. *Mycoses* 2021;64:798-808.
- Sen M, Lahane S, Lahane TP, Parekh R, Honavar SG. Mucor in a viral land: A tale of two pathogens. *Indian J Ophthalmol* 2021;69:244-52.
- Placik DA, Taylor WL, Wnuk NM. Bronchopleural fistula development in the setting of novel therapies for acute respiratory distress syndrome in SARS-CoV-2 pneumonia. *Radiol Case Rep* 2020;15:2378-81.
- Sebastian SK, Kumar VB, Gupta M, Sharma Y. Covid associated invasive fungal sinusitis. *Indian J Otolaryngol Head Neck Surg* 2021;2021:1-4.
- Bellanger AP, Navellou JC, Lepiller Q, Brion A, Brunel AS, Millon L, et al. Mixed mold infection with *Aspergillus fumigatus* and *Rhizopus microsporus* in a severe acute respiratory syndrome Coronavirus 2 (SARS-CoV-2) patient. *Infect Dis Now* 2021.
- Karimi-Galougahi M, Arastou S, Haseli S. Fulminant mucormycosis complicating coronavirus disease 2019 (COVID-19). *Int Forum Allergy Rhinol* 2021;11:1029-30.
- Zurl C, Hoenigl M, Schulz E, Hatzl S, Gorkiewicz G, Krause R, et al. Autopsy proven pulmonary mucormycosis due to *Rhizopus microsporus* in a critically ill COVID-19 patient with underlying hematological malignancy. *J Fungi* 2021;7:88.
- Sargin F, Akbulut M, Karaduman S, Sungurtekin H. Severe rhinocerebral mucormycosis case developed after COVID 19. *J Bacteriol Parasitol* 2021;12:386.
- Hatri A, Chang KM, Berlinrut I, Wallach F. Mucormycosis after Coronavirus disease 2019 infection in a heart transplant recipient-case report and review of literature. *J Mycol Med* 2021;31:101125.
- Mishra N, Mutya VS, Thomas A, Rai G, Reddy B, Mohanan AA, et al. A case series of invasive mucormycosis in patients with COVID-19 infection. *Int J Otorhinolaryngol Head Neck Surg* 2021;15:102146.
- Waizel-Haiat S, Guerrero-Paz JA, Sanchez-Hurtado L, Calleja-Alarcon S, Romero-Gutierrez L. A case of fatal rhino-orbital mucormycosis associated with new onset diabetic ketoacidosis and COVID-19. *Cureus* 2021;13:e13163.