

A CASE OF ACUTE MESENTERIC ISCHEMIA: DIAGNOSTIC DILEMMA AND SURGICAL CHALLENGE

MOHIT MITTAL^{1*}, NIMISH GAUR², SANDHYA GHODKE³, RAVISHEKAR N HIREMATH⁴, SHARANJIT SINGH BASRA¹,
VISHAL VERMA¹¹Department of Surgery, AFMS, New Delhi. ²Department of Anaesthesiology, AFMS, New Delhi. ³Department of Anaesthesiology, Rainbow Children Hospital, Bengaluru, Karnataka. ⁴Department of Community Medicine, AFMS, New Delhi. Email: mittalmohit_5493@yahoo.com

Received: 29 January 2022, Revised and Accepted: 26 May 2022

ABSTRACT

Mesenteric ischemia is an uncommon condition, and we need to have a high index of suspicion to diagnose and manage this condition. Predisposing conditions such as myocardial infarction, portal hypertension, pancreatitis, inflammatory bowel disease, post-operative states, trauma, and hypercoagulable states such as DVT, pregnancy, and neoplasms should always be accounted for before diagnosing this condition. In emergency situations, surgical exploration is warranted. Here, we present a case of 57-year-old male, known case of DVT RT lower limb, on anticoagulants, presented with the complaints of epigastric pain, absolute constipation, and abdominal distention of 3 days duration. He was investigated and managed by exploratory laparotomy with peritoneal lavage and resection of gangrenous bowel with proximal jejunostomy and distal ileostomy.

Keywords: Bowel obstruction, Gangrenous bowel resection, Hemoperitoneum, Ileostomy, jejunostomy, Mesenteric ischemia.

© 2022 The Authors. Published by Innovare Academic Sciences Pvt Ltd. This is an open access article under the CC BY license (<http://creativecommons.org/licenses/by/4.0/>) DOI: <http://dx.doi.org/10.22159/ajpcr.2022v15i8.44276>. Journal homepage: <https://innovareacademics.in/journals/index.php/ajpcr>

INTRODUCTION

Mesenteric ischemia (MI) is an uncommon medical condition that accounts 0.1% of all hospital admissions, with high mortality rates ranging from 24 to 94% [1]. It includes inadequate blood supply, inflammatory injury, and eventually necrosis of the bowel wall. The disease can be divided into acute and chronic MI (CMI), with the acute being subdivided into four categories [2]. Therefore, acute MI (AMI) can occur as a result of arterial embolism, arterial thrombosis, mesenteric venous thrombosis, and non-occlusive causes resulting from hypoperfusion with secondary severe and prolonged visceral vasoconstriction [3]. Bowel damage is always in proportion to the mesenteric blood flow decrease. It may vary from minimum lesions, due to reversible ischemia, to transmural injury, with subsequent necrosis and perforation [4]. CMI is associated to diffuse atherosclerotic disease in more than 95% of cases, with all major mesenteric arteries presenting stenosis or occlusion. Because of a lack of specific signs or due to its sometime quiet presentation, this condition is frequently diagnosed only at an advanced stage [5]. Computed tomography (CT) imaging and CT angiography contribute to differential diagnosis and management of acute mesenteric ischemia. Angiography is also the criterion standard for CMI, with mesenteric duplex ultrasonography and magnetic resonance angiography also being of significant importance. Therapeutic approach of MI includes both medical and surgical treatments. Surgical procedures include restoration of the blood flow with arteriotomy, endarterectomy or anterograde bypass, and exploratory laparotomy with resection of necrotic bowel.

CASE REPORT

A 57-year-old male, known case of DVT RT lower limb, on anticoagulants, presented with the complaints of epigastric pain, absolute constipation, and abdominal distention of 3 days duration. Pain was insidious onset, gradually progressive, continuous, and severe intensity. It began in the epigastric region and then became generalized. The patient was initially managed conservatively at a peripheral hospital with IV fluids, antibiotics, and bowel rest and then air evacuated to our center. On examination, the patient was conscious, cooperative, and oriented. He had tachycardia, P-124/min, BP 124/70 mmHg, RR -18/min, and SpO₂ 99% at room air. Per abdomen examination, abdominal distention was present with epigastric

tenderness and absent bowel sounds. There was no guarding or rigidity. On digital rectal examination, stools were present. However, there was no blood or tenderness. Laboratory parameters revealed Hb of 8.1 g%, TLC - 6100/cumm, and P79L16. His INR was 1.88. His blood sugars, LFTs, and RFTs were within normal limits. Urgent CECT abdomen was done in view of acute intestinal obstruction. CT findings showed long segment, smooth, symmetrical circumferential bowel thickening, with edematous changes involving distal jejunum and proximal ileum. Mesentery of involved bowel showed reduced vascularity and inflammatory fat stranding and moderate ascites giving an impression of acute small bowel obstruction with bowel ischemia with hemoperitoneum (Fig. 1).

The patient was prepared for emergency exploratory laparotomy in view acute small bowel obstruction with bowel ischemia and hemoperitoneum. Pre-operative stabilization of the patient was done with transfusion of two units of PRBC and four units FFP. The consent was taken for high-risk surgery in view of anticipated large segment bowel resection due to bowel ischemia. Furthermore, the consent was taken for stoma formation. Exploratory laparotomy was performed with peritoneal lavage and resection of gangrenous bowel with proximal jejunostomy and distal ileostomy. The intraoperative findings showed around 2 L of hemoperitoneum, around 25 inches of gangrenous bowel segment from distal jejunum till mid ileum, thickened mesentery, and bowel wall edema (Fig. 2).

Intraoperatively, the patient was transfused two units PRBC and four units FFP. The patient was nursed in ICU on ventilator. Postoperatively, the patient was kept nil orally and managed conservatively with intravenous fluids, broad-spectrum intravenous antibiotics, and analgesics. Strict intake output monitoring was done to prevent dehydration or fluid overload. Pneumatic pumps were used in lower limbs to prevent DVT. Total parenteral nutrition was started from post-operative day 2 followed by enteral feeding from post-operative day 5. Refeeding of jejunostomy contents into the ileal stoma was done to prevent the loss of nutrients. Stoma care and dressings were done as required. Chest care was done in the form of chest physiotherapy, steam inhalation, and incentive spirometry to prevent basal atelectasis. Early ambulation was started from post-operative day 2. Bowel sounds returned on the 5th post-operative day and enteral feeding was started. Sutures were removed after 14 days. The

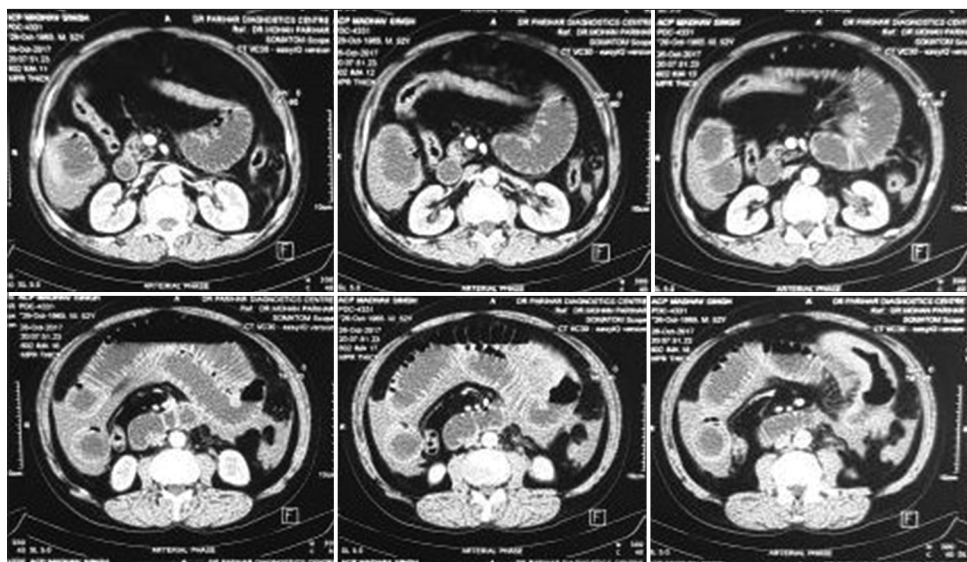


Fig. 1: Computed tomography scan findings of acute small bowel obstruction with bowel ischemia with hemoperitoneum

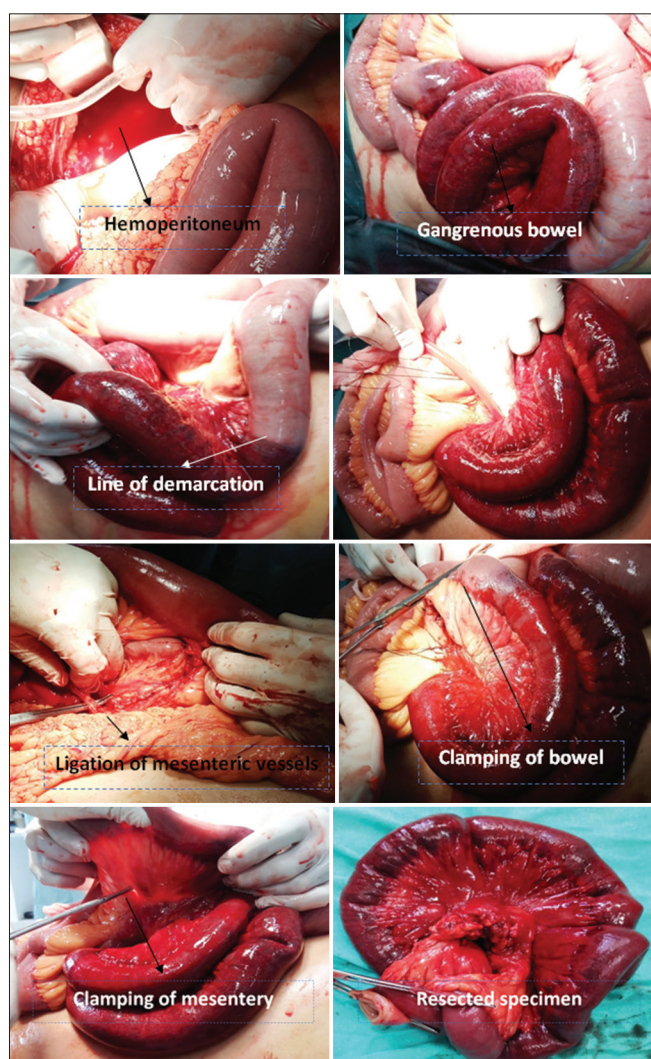


Fig. 2: Intraoperative findings of acute small bowel obstruction with bowel ischemia with hemoperitoneum

patient was referred to tertiary care center after suture removal for complete hematology work-up.

DISCUSSION

MI is an uncommon medical condition with high mortality rates. When acute occlusion of a major artery occurs, profound illness usually results, and survival is fortunate. Non-occlusive mesenteric insufficiency and mesenteric venous occlusion occur in the presence of severe concurrent illness of variable causes. Chronic intestinal ischemia often presents a diagnostic challenge, but results are gratifying with timely therapy. Because of a lack of specific signs or due to its sometime quiet presentation, this condition is frequently diagnosed only at an advanced stage. Therapeutic approach refers to both medical and surgical treatments.

In our case, the patient had a hypercoagulable state and was on oral anticoagulants for 2 years with irregular INR monitoring. The patient was transferred to our hospital 3 days after the initial presentation, and by the time, he was taken up for surgery, significant bowel ischemia had already set in. The patient underwent resection of sufficient length of small intestine. Postoperatively, the patient had an uneventful recovery and was subsequently referred to a tertiary center for complete hematology work-up. Bowel restoration was performed 3 months after the initial surgery.

Obada *et al.* [6] also described an interesting AMI case in a 45-year-old male, due to NBTE where in a patient with a history of smoking complained of pain abdomen and CT angiography showed SMA thrombus. Here, laparotomy was done with SMA thrombectomy and endarterectomy and small bowel resection. Wu *et al.* [7] also reported a case of male, 85-year-old with acute-onset progressive periumbilical cramping pain with elevated D-dimer. This was a case of acute SMA occlusion diagnosed on CT abdomen with massively ischemic small intestine with ascites filled with blood. Haghghi *et al.* [8] reported a pregnant lady with 28 years presenting with pain abdomen, mild degree with fever, and malaise. Initially, it was thought to be of influenza infection but when later on when abdominal pain was severe, and the patient looked toxic. Acute abdomen was diagnosed, and exploratory laparotomy was done to diagnose AMI. All the authors who reported AMI highlighted the importance of early diagnosis and timely action led to excellent outcomes [7,9].

CONCLUSION

MI is an uncommon condition, and we need to have a high index of suspicion to diagnose and manage this condition. Predisposing conditions such as myocardial infarction, portal hypertension, pancreatitis, inflammatory bowel disease, post-operative states, trauma, and hypercoagulable states such as DVT, pregnancy, and

neoplasms should always be accounted for before diagnosing this condition. In emergency situations, surgical exploration is warranted.

ACKNOWLEDGMENTS

I acknowledge and thank to all my coauthors, and study participants.

AUTHORS' CONTRIBUTIONS

All authors have contributed to the preparation of manuscript.

CONFLICTS OF INTEREST

Nil.

AUTHORS' FUNDING

Nil.

PATIENT CONSENT STATEMENT

Patient informed consent was taken to publish this case report.

REFERENCES

1. Roussel A, Castier Y, Nuzzo A, Pellenc Q, Sibert A, Panis Y, *et al.* Revascularization of acute mesenteric ischemia after creation of a dedicated multidisciplinary center. *J Vasc Surg* 2015;62:1251-6. doi: 10.1016/j.jvs.2015.06.204, PMID 26243208
2. Corcos O, Nuzzo A. Gastro-intestinal vascular emergencies. *Best Pract Res Clin Gastroenterol* 2013;27:709-25. doi: 10.1016/j.bpg.2013.08.006, PMID 24160929
3. Bobadilla JL. Mesenteric ischemia. *Surg Clin North Am* 2013;93:925-40. doi: 10.1016/j.suc.2013.04.002, PMID 23885938
4. van den Heijkant TC, Aerts BA, Tejjink JA, Buurman WA, Luyer MD. Challenges in diagnosing mesenteric ischemia. *World J Gastroenterol* 2013;19:1338-41. doi: 10.3748/wjg.v19.i9.1338, PMID 23538325
5. Pecoraro F, Rancic Z, Lachat M, Mayer D, Amann-Vesti B, Pfammatter T, *et al.* Chronic mesenteric ischemia: Critical review and guidelines for management. *Ann Vasc Surg* 2013;27:113-22. doi: 10.1016/j.avsg.2012.05.012, PMID 23088809
6. Obada T, Hamzeh AS, Omar AI, Solly C. An interesting case of acute mesenteric ischemia secondary to nonbacterial thrombotic endocarditis. *Am J Gastroenterol* 2017;112:S1346.
7. Wu MY, Lee LC, Chen YL, Chien YC, Ni BY, Hou YT, *et al.* Ischemic bowel disease due to superior mesenteric artery occlusion: A case report. *Reports* 2018;1:10. doi: 10.3390/reports1010010
8. Haghghi L, Hashemi N, Tahermanesh K, Najmi Z, Baba Heydariyan PB, Khaledi M. Mesenteric ischemia in pregnant woman: A case report. *J Obstet Gynaecol* 2019;39:1012-4. doi: 10.1080/01443615.2019.1572077, PMID 31161835
9. Boley SJ, Sprayregen S, Veith FJ, Siegelman SS. An aggressive roentgenologic and surgical approach to acute mesenteric ischemia. *Surg Annu* 1973;5:355-78. PMID 4602220