

PREVALENCE AND SPECTRUM OF OPHTHALMIC MANIFESTATIONS OF DENGUE: OUR EXPERIENCE IN A NORTH INDIAN TERTIARY CARE INSTITUTE

RAJINDER SINGH¹, SURINDER KAUR², JATIN THUKRAL³, HARBIR KAUR³

¹Department of Ophthalmology, Government Medical College, Patiala, Punjab, India. ²Department of Pedodontics, Government Dental College, Patiala, Punjab, India. ³MBBS Batch 2016, Government Medical College, Patiala, Punjab, India.
E-mail: rajindersingh76763@yahoo.in

Received: 06 March 2022, Revised and Accepted: 20 April 2022

ABSTRACT

Objective: This article puts forward various ocular findings and its prevalence in hospitalized patients with confirmed Dengue serology. The aim is to spread awareness about these findings and call for complete eye examination in patients of dengue fever so that the ocular findings are not missed.

Methods: This is a cross-sectional study, conducted on confirmed cases of 112 dengue patients in Dengue isolation ward in a tertiary care hospital, Government Medical College, Patiala, India, during and after the monsoon season.

Results: Various fundus findings in dengue fever seen in our study are Dot blot hemorrhages, cotton wool spots, macular hemorrhages, macular edema, Roth spots, vascular sheathing, hard exudates, and sub-conjunctival hemorrhage. Cumulative prevalence of these findings was 9.82% in hospitalized patients of dengue fever. Blurring of vision was also a common symptom.

Conclusion: Ocular findings do occur in dengue fever, along with other systemic manifestations such as fever, headache, myalgia, arthralgia, retro-orbital pain, hemorrhagic fever, and shock syndrome. Ocular examination should be undertaken in all patients with dengue fever so that these findings are not missed. Further studies are needed to ascertain its pathophysiology.

Keywords: Dengue fever, Ocular manifestations, Macular hemorrhage, Roth spots, Expanded Dengue syndrome.

© 2022 The Authors. Published by Innovare Academic Sciences Pvt Ltd. This is an open access article under the CC BY license (<http://creativecommons.org/licenses/by/4.0/>) DOI: <http://dx.doi.org/10.22159/ajpcr.2022v15i5.44592>. Journal homepage: <https://innovareacademics.in/journals/index.php/ajpcr>

INTRODUCTION

Dengue fever is a mosquito borne illness transmitted by female Aedes mosquito. Globally, the disease is now endemic in many countries of the regions of Africa, the Americas, the Eastern Mediterranean, South-East Asia, and the Western Pacific [1]. The global incidence of dengue has grown dramatically in recent decades [2]. One estimate indicates 390 Million dengue infections per year (95% credible interval 284–528 million), of which 96 million (67–136 million) manifest clinically (with any severity of disease) [1]. Much of the disease burden is missed due to asymptomatic nature or mild features of disease; or lack of proper diagnostics in resource-poor countries and regions.

In India, dengue has been reported from almost all the states, with the highest incidence in Tamil Nadu followed by Kerala, Karnataka, Punjab, and West Bengal [3]. During the past, dengue was mainly reported from urban areas. But now it has seen a trend of moving toward sub-urban and rural areas, where the chance of diagnosis and health infrastructure is less, so the cases are easily missed. The yearly incidence of reported cases in India varies between 150,000 and 200,000. Dengue fever has a seasonal variation, with incidence beginning to peak after the onset of monsoon from July to November each year. However, year-long transmission is also known in some regions of the world.

Dengue is transmitted by the bite of female Aedes mosquito [4] (majority by Aedes aegypti, minority by Aedes albopictus). Mosquitoes require standing water for laying eggs, such as flower pots, tyres, open tanks, and others. Therefore, removal of such sites is an important prevention strategy against dengue fever.

The dengue virus belongs to Flavivirus genus of the family Flaviviridae, and its members include the four antigenically related serotypes of dengue virus [5]. Flaviviruses are single-stranded and have genetic material made up of RNA. The four serotypes of dengue virus are DENV-1, DENV-2, DENV-3, and DENV-4. At present, DEN1 and DEN2 serotypes

are widespread in India [4]. Different serotypes of dengue can circulate in an endemic area and infection from a serotype provides lifelong protection against that particular serotype only. Subsequent infections with other serotypes are known to exhibit severe manifestations because of antibody dependent enhancement of disease [6].

The mechanism behind ocular involvement can either be due to inflammation or occlusion of the vessels. Low platelet counts and increased inflammatory cytokines can cause blood extravasation and fluid leakage, respectively. This is seen as dot-blot hemorrhages, macular hemorrhages, and macular edema on funduscopy. Pro-inflammatory cytokines hypothesized to be involved are IL-1, IL-6, TNF-ALPHA, and INTERFERON GAMMA. Further the severity of manifestations depends on susceptibility and individual variations which are thought to be genetic in origin. Severity can also vary with serotype.

Order of risk of severe manifestations is seen when (DENV1 Is followed by DENV2) > (DENV3 Followed by DENV2) > (DENV4 followed by DENV2) [3]. Pathophysiology can also be explained by an antibody basis, as the ocular manifestations peak on day 7, which is also the day when IgM antibody starts having the effect against the dengue virus.

The literature on eye findings in dengue fever was scarce in the past. However, some abstracts find its mention from the 1980s. Dengue virus infection can present as asymptomatic or symptomatic infection. The symptomatic infection is further classified into undifferentiated fever (viral syndrome), dengue fever (DF), dengue hemorrhagic fever, and expanded dengue syndrome. Undifferentiated fever refers to those patients infected with dengue virus, especially for the first time (i.e., primary infection) who develop a simple fever indistinguishable from other viral infection. Dengue fever includes fever with ≥ 2 of the following – Headache, Retro-orbital pain, Myalgia, Arthralgia, Rash, or Hemorrhagic manifestations. Laboratory findings such as leukopenia (WBCs <5000 cells/cu.mm), thrombocytopenia (Platelet count

<150,000 cells/cu.mm.), and rising hematocrit (5–10%) further raise clinical suspicion of dengue, which is confirmed with serology. Dengue fever may present without hemorrhage or with unusual hemorrhage. Dengue hemorrhagic fever (DHF) is divided into four grades. DHF Grade I follows above criteria of DF and hemorrhagic manifestations plus positive tourniquet test, evidence of plasma leakage. DHF Grade II includes above signs and symptoms plus some evidence of spontaneous bleeding in skin or other organ (black tarry stools, epistaxis, and bleeding from gums) and abdominal pain. DHF Grade III includes above signs and symptoms plus circulatory failure (weak rapid pulse, pulse pressure ≤ 20 mm Hg or high diastolic pressure, and hypotension with the presence of cold clammy skin and restlessness). DHF Grade IV includes signs as Grade III plus profound shock with undetectable blood pressure or pulse. DHF Grades III and IV are Dengue Shock Syndrome. Laboratory findings in DHF include Thrombocytopenia with platelet count $<100,000$ /cu.mm and increase in hematocrit by 20% or more [3].

The World Health Organization in 2011 coined the term expanded dengue syndrome for the cases which do not fall under dengue shock syndrome or dengue hemorrhagic fever and have atypical manifestations with multisystem involvement including the liver, heart, kidney, the central nervous system alerting the physicians to evaluate for dengue in the presence of atypical clinical features. Ophthalmic manifestations included in this entity were macular hemorrhage, impaired visual acuity, and optic neuritis [7-9].

Neuro-ophthalmic dengue is associated with papilledema, increased intracranial pressure, optic neuritis, CN VI palsy, ophthalmoplegia, neurogenic ptosis, and significant permanent visual deficits [10].

METHODS

A cross-sectional study was conducted at a tertiary care hospital, Patiala during monsoon season. The consent for an eye examination was taken from the medicine department and the admitted patients. Study was conducted on 112 confirmed dengue patients admitted in dengue isolation ward in peak season. The patients who presented within first 5 days of the onset of signs and symptoms of suspected dengue fever were confirmed by NS1 Antigen Kit (Non Structural protein-1 Antigen) and the patients who presented after 5 days of onset of signs and symptoms were confirmed by IgM antibody test. These tests were done at VDRL Lab, Government Medical College, Patiala, India.

Exclusion criteria

The following criteria were excluded from the study:

- History of(H/o) Diabetes mellitus.
- H/o Hypertension
- H/o hemoglobinopathies.
- H/o cancer
- H/o cardiac illnesses such as heart failure, arrhythmias, and subacute bacterial endocarditis.
- H/o trauma or intraocular surgery.
- H/o uveitis, glaucoma, corneal deposits, or cataract.
- H/o malaria by performing a simultaneous MP (Malarial Parasite) card test.
- Pregnancy.

All eyes included in our study were healthy eyes before the onset of dengue infection.

All patients were examined with Snellen's distant test types for visual acuity. Focused torch light was used to examine adnexa, conjunctiva, sclera, and cornea of the patients. Indirect ophthalmoscopy was used for fundus examination. Both the pupils of all patients were dilated with tropicamide (2%) and phenylephrine (5%) combination drops. Three instillations of one drop each were administered in conjunctival sac of both eyes at intervals of 10 min and hence, after approximately 30–35 min, when the pupil was fully dilated, fundus examination was done. Amsler's grid was also used for macula analysis. Patients were examined for a period of 8–10 days. Daily blood sampling was done

for CBC (Complete blood counts) and routine investigations which included liver function tests, renal function tests, random blood sugar, serum electrolytes, and others.

RESULTS

A total of 112 confirmed patients were examined. The patients examined were between the ages of 18 years and 60 years; among them 60 were males and 52 were females. Average age was 35 (± 15) years. The population had subjects hailing from different states: Punjab (59), Haryana (23), and migrant workers from U.P. and Bihar (30). 11 patients out of 112 (i.e., 9.82%) had ocular findings. Five out of 11 patients with ocular findings had bilateral involvement. Patients with bilateral ocular involvement had asymmetrical features in both eyes. Hence, a total of 16 eyes were affected. The common ocular manifestations were Dot blot hemorrhages (8), cotton wool spots (5), and macular hemorrhage (5).

Parameters	Number of eyes	% among eyes with ocular involvement (n=16)
Dot blot hemorrhages	8	~50.00
Cotton wool spots	5	31.25
Macular hemorrhage	5	31.25
Macular edema	4	25
Roth spots	3	18.75
Vascular sheathing	2	12.5
Hard exudates	1	6.25
Sub-hyaloid hemorrhage or vitreous hemorrhage	-	-
Disc edema	-	-
Sub-conjunctival hemorrhage	2	12.5

The most common ocular signs in terms of percentages were dot-blot hemorrhages (~50%) and macular hemorrhages (31.25%). The next common findings were cotton wool spots (31.25%), macular edema (25%), and Roth spots (18.75%). Other less common findings are vascular sheathing (12.5%) and hard exudates (6.25%) which were seen in two and one eye, respectively. Sub-conjunctival hemorrhage was seen in 2 eyes (12.5%).

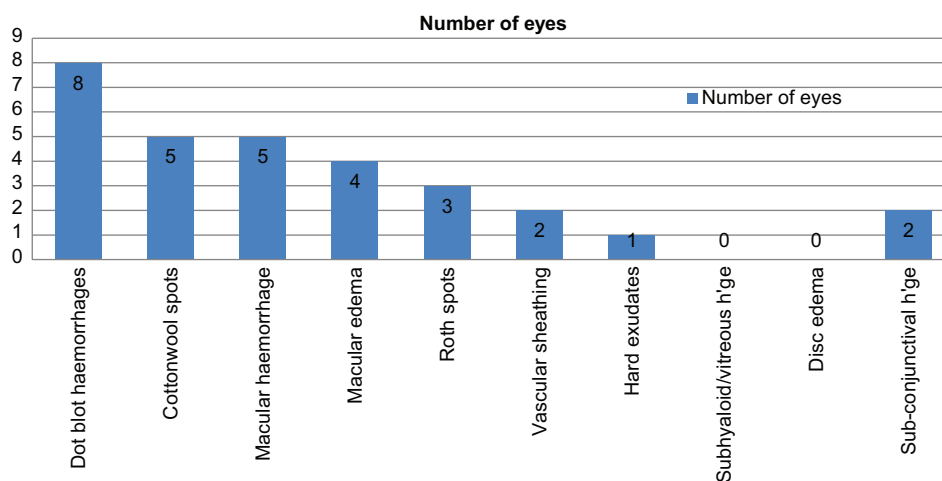
Mean interval between onset of visual symptoms ranged between 7 and 8 days of onset of symptoms of dengue fever. Decrease in visual acuity occurs due to involvement of macula be it by hemorrhage, edema, or vascular occlusion. The patients presented with symptoms such as: Visual blurring, scotomas, redness of eye, pain, and distortion of shape of objects.

Complete blood count was monitored daily for the entire duration of hospital stay. Peak of thrombocytopenia was observed on 7th day (with a range of 6th–8th day) of the onset of symptoms. Eight out of 11 patients presented with fundus findings on 7th day thus correlating thrombocytopenia with onset of visual signs and symptoms.

DISCUSSION

The patients chosen in our study were between the ages of 18 years and 60 years; among them 60 were males and 52 were females. Average age was 35(± 15) years. Similarly, a comparative study by Sujatha *et al.* [11] in 2015 in a total of 120 patients diagnosed with dengue fever; of which, 75 (62.5%) were men and 45 (37.5%) were women. Mean age was 32 years (20–60 years). Similarly, Teoh *et al.* [12] conducted a study on 50 patients with dengue fever. There were 34 males and 16 females with ages ranging between 20 and 69 years (mean 32 ± 11 years).

The prevalence of ocular findings in our study was 11 out of 112 (9.82%) confirmed dengue fever patients. A similar comparative study was conducted at Dr. BR Ambedkar Medical College and Hospital, Bengaluru, Karnataka, India by Sujatha *et al.* [11]. A total of 120 patients were diagnosed with dengue fever and posterior segment findings were seen in 16 patients (13.3%). CDC, Singapore, also suggests that incidence of



visually symptomatic ophthalmic complications range between 5 and 6% of all dengue cases [12].

Five out of 11 (45.45%) patients with ocular involvement in dengue fever had bilateral involvement in our study. Teoh *et al.* [12] Singapore, also reported similar findings. 15 out of 50 patients (30%) have bilateral ocular involvement in dengue fever. Vijitha *et al.* [9] in 2020 reported bilateral involvement in six out of 23 patients (26%).

The various ocular manifestations in our study were dot-blot hemorrhages (~50%) and macular hemorrhages (31.25%), cotton wool spots (31.25%), macular edema (25%), Roth spots (18.75%), sub-conjunctival hemorrhage (12.5%), vascular sheathing (12.5%), and hard exudates (6.25%).

A similar study given by Ng *et al.* [13] in 2016 which stated the various ocular manifestations were present as macular edema (76.9%), macular hemorrhage (69.2%), foveolitis (28-33.7%), vasculitis, or vascular occlusion. Teoh *et al.* [12] stated that the ocular findings were present as macular edema (76.9%), macular hemorrhage (69.2%), foveal elevation (33.8%), retinal vasculitis (23.1%), posterior vitreous cells (10.8%), disc swelling (3.1%), sub-conjunctival hemorrhage (4.6%), and others.

The ocular findings in patients observed had a self-limiting course with symptomatic management. The most common complaint was blurring of vision which was also seen in a similar study by Yip *et al.* [14]. Visual recovery usually corresponds with improving platelets levels [15]. Fluid leakage and extravasation of blood occur due to inflammatory cytokines and thrombocytopenia; hence, resolves on its own with normalization of blood counts and hematocrit.

Limitations

Patients could not be tested for anterior uveitis, because the patients were in an isolated ward and slit lamp examination was not possible there.

CONCLUSION

Dengue, a vector borne disease, which yearly affects millions of people can have several ocular manifestations. This cross-sectional study puts forward the ocular findings and their prevalence in 112 hospitalized patients with confirmed dengue serology. 11 patients had ocular findings, among them five patients had bilateral involvement. The prevalence of eye involvement was 9.82%.

Complete eye examination in dengue fever should be done so that these ocular findings are not missed and their timely reporting can prevent impairment in visual acuity and their long-term sequelae. Since our

study was done in hospitalized patients, further studies are needed to discuss whether routine eye examination is required or not in milder forms of dengue fever.

AUTHOR CONTRIBUTIONS

RS, SK, JT, and HK conducted research and drafted the manuscript. RS, JT, and HK contributed in identifying and management of the ophthalmic manifestations in patients of dengue fever. RS and SK also contributed in statistics. HK and JT contributed in diagnosis of dengue and medical management of patients. RS and SK revised the manuscript. All authors read and approved the final manuscript.

CONFLICT OF INTEREST

We declare that we have no conflict of interest.

FUNDING AND SPONSORSHIP

Not Applicable.

REFERENCES

- National Guidelines Dengue Case Management during COVID-19 Pandemic, By National Vector Borne Disease Control Programme. Directorate General of Health Services, MoHFW, GOI; 2020.
- Rahman A, Faridi J, Rahman S, Khondokar AI, Naz B, Hossain MM. Dengue: An emerging ocular problem. *Clin Ophthalmol* 2021;4:201-6.
- Park K. Park's Textbook of Preventive and Social Medicine.
- Guidelines for Clinical Management of Dengue Fever, Dengue Hemorrhagic Fever and Dengue Shock Syndrome. NVBDCP, DGHS, MoHFW, GOI; 2008.
- Latif N, Kowsigan M, Jyotirmay B, Dutta MP. Dengue-associated eye disease. *Nepal J Ophthalmol* 2019;11:115-21.
- Le T, Bhushan V, Sochat M. First AID for USMLE®. New York, NY: McGraw Hill; 2021.
- Yudhishdran J, Liyanage IK, Navinan MR, Herath S, Withange D, Jeyalakshmy S. The eye in dengue fever, a rarely appreciated aspect of dengue expanded syndrome: A case report. *J Med Case Rep* 2019;13:271.
- World Health Organization (WHO). Regional Office for South-East Asia. Comprehensive Guidelines for Prevention and Control of Dengue and Dengue Hemorrhagic Fever. Revised and Expanded Edition. Geneva: WHO; 2011.
- Dave TV, Murthy SI, Ali JM, Dave PV, Pappuru RR, Narayanan R. Commentary: Assessing the results of anophthalmic prostheses. *Indian J Ophthalmol* 2021;69:617-22.
- Karesh JW, Mazzoli RA, Heintz SK. Ocular manifestations of mosquito-transmitted diseases. *Mil Med* 2018;183:450-8.
- Sujatha R, Nousheen S, Nazlin A, Prakash S. Ocular manifestations of dengue fever. *Int J Med Sci Public Health* 2015;4:690-3.
- Teoh SC, Chan DP, Nah GK, Rajagopalan R, Laude A, Ang BS, *et al.* A re-look at ocular complications in dengue fever and dengue

- haemorrhagic fever. *Dengue Bull* 2006;30:184-93.
13. Ng CW, Tai PY, Mohamed SO. Dengue maculopathy associated with choroidopathy and pseudohypopyon: A case series. *Ocul Immunol Inflamm* 2016;26:1-5.
 14. Cherng-Hui YV, Srinivasan S, Tong KY. Ophthalmic complications of dengue fever: A systematic review. *Ophthalmol Ther* 2012;1:2.
 15. Jaafar J, Raja AM, Yaakub A, Tajudin LS. Dengue related maculopathy and foveolitis. *Asian Pac J Trop Biomed* 2012;2:755-6.