

XANTHOGRANULOMATOUS APPENDICITIS-A RARE HISTOLOGICAL VARIANTMOHIT MITTAL¹, RAVISHEKAR N HIREMATH², NIMISH GAUR³, VISHAL VERMA⁴, SANDHYA GHODKE¹

¹Department of Surgery, AFMS, New Delhi, India. ²Department of Community Medicine, AFMS, New Delhi, India. ³Department of Anaesthesia, AFMS, New Delhi, India. ⁴Department of Anaesthesia, Rainbow Children Hospital, Bengaluru, Karnataka, India.
 Email: drshekar80@gmail.com

Received: 04 December 2022, Revised and Accepted: 20 January 2023

ABSTRACT

Xanthogranulomatous inflammation (XGI) is a chronic inflammatory process most commonly described in the case of gall bladder and kidney. The same occurring in the case of the vermiform appendix is a rare occurrence. Here, we describe two cases of appendicitis in which postoperatively histopathological examination revealed typical features of XGI in the appendix.

Keywords: Appendectomy, Vermiform appendix, Xanthogranulomatous inflammation.

© 2023 The Authors. Published by Innovare Academic Sciences Pvt Ltd. This is an open access article under the CC BY license (<http://creativecommons.org/licenses/by/4.0/>) DOI: <http://dx.doi.org/10.22159/ajpcr.2023v16i5.46990>. Journal homepage: <https://innovareacademics.in/journals/index.php/ajpcr>

INTRODUCTION

Acute appendicitis is one of the most common surgical conditions, but very rarely do we see Xanthogranulomatous appendicitis on histopathological examination. It is a rare type of chronic inflammation leading to tissue destruction and localized proliferation of lipid-laden macrophages, which is the characteristic histological feature with only a few reported cases. Xanthogranulomatous appendicitis may mimic a locally advanced malignancy but has a benign course, and can be cured by surgical resection. Here, we report two cases of Xanthogranulomatous appendicitis presenting as acute appendicitis necessitating emergency appendectomy in one and interval appendectomy in another.

CASE REPORT: 01

A 37-year-old male patient, with no known previous comorbidities, presented to the emergency department with a history of pain in the right iliac fossa along with fever and vomiting of 1-day duration. Pain was insidious onset, gradually progressive, continuous, and moderate intensity. It began in the umbilical region and soon got localized to the right iliac fossa. On examination, the patient was conscious, cooperative, and oriented. He had tachycardia, P-110/min, blood pressure 124/70 mm Hg, RR-18/min, and SpO₂ 99% at room air. On per abdomen examination, marked tenderness and rebound tenderness were there in the right iliac fossa. There was no guarding or rigidity. On digital rectal exam (DRE), stools were present. However, there was no blood or tenderness. Laboratory parameters revealed Hb of 12.1 g%, TLC-12.100/cumm, P79L16. His blood sugars, liver function tests (LFTs), and renal function tests (RFTs) were WNL. Ultrasound scan of the abdomen revealed an appendix with a diameter of 08 mm with minimal periappendicular fluid collection with no fecolith. A computed tomography of the abdomen was not done in this case.

The patient was taken up for an emergency appendectomy. The intraoperative findings are as follows

- Enlarged, inflamed, turgid appendix
- Dense adhesions of the appendix with lateral peritoneal wall
- Thickened mesentery
- Minimal periappendiceal fluid collection
- No fecolith in the appendix.

The surgery of the patient was uneventful. Histopathological analysis of the appendix specimen showed the presence of numerous foamy histiocytes, neutrophils, plasma cells, and few nucleated giant cells. No parasites were seen. No dysplasia/evidence of malignancy was noted. Von kossa and Pearl's stain were also done to rule out malakoplakia.

His post-operative recovery was completely uneventful. The patient was discharged after suture removal. His subsequent outpatient department (OPD) visits after 2 week and 4 weeks were unremarkable.

CASE REPORT: 02

A 21-year-old male patient, with no known previous comorbidities, presented to the emergency department with a history of pain in the right iliac fossa along with fever and vomiting of 05 days duration. Pain was insidious onset, gradually progressive, continuous, and moderate intensity. It began in the umbilical region and soon got localized to the right iliac fossa. On examination, the patient was conscious, cooperative, and oriented. His vital parameters were within the normal limits. Per abdomen examination revealed tenderness and rebound tenderness with a palpable lump in the right iliac fossa. There was no guarding or rigidity. DRE was normal. Laboratory parameters revealed Hb of 15.1 g%, TLC-8.100/cumm, P62L16. His blood sugars, LFTs and RFTs were WNL. Ultrasound scan of the abdomen revealed an appendicular lump with thickened surrounding small bowel loops and minimal periappendicular fluid collection. A computed tomography of the abdomen was not done in this case. The patient was managed conservatively on the Ochsner-Sherren regime in view of the appendicular lump. The patient was taken up for interval appendectomy after 6 weeks.

The intraoperative findings are as follows:

- Minimally inflamed appendix
- Dense adhesions of the appendix with surrounding small bowel loops
- Thickened mesoappendix
- No fecolith in the appendix.

The surgery of the patient was uneventful. Histopathological analysis of the appendix specimen showed sheets and nodules of histiocytes with granular acidophilic cytoplasm beneath the surface epithelium. Occasional rounded, concentrically layered intracytoplasmic inclusions (calcospherites) were noted in few of these histiocytes. Foamy macrophages, giant cells admixed with plasma cells and lymphocytes were also seen in association with these histiocytes. No parasites were seen. No dysplasia/evidence of malignancy was noted. Von kossa and Pearl's stain were also done to rule out malakoplakia. His post-operative recovery was completely uneventful. The patient was discharged after 7 days. His subsequent OPD visits after 2 week and 4 weeks were unremarkable.

DISCUSSION

Xanthogranulomatous inflammation (XGI) is a unique pathologic entity with characteristic macroscopic and microscopic features. Typical

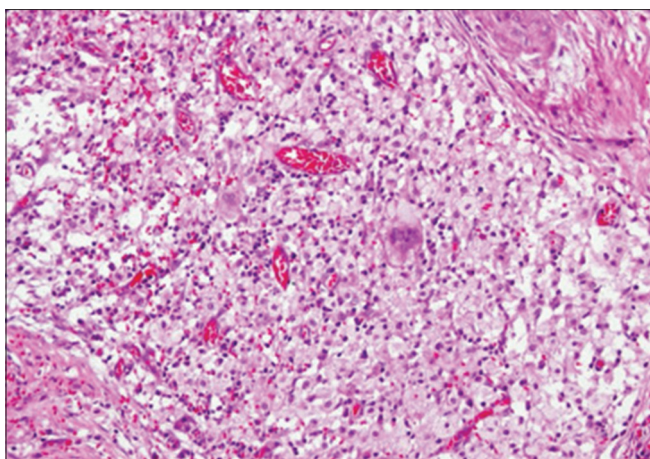


Fig. 1: Xanthogranulomatous appendicitis showing dense infiltrate of foamy histiocytes, and multinucleated giant cells [11]

findings include bright yellow or golden yellow mass-like ulcerated lesions on macroscopic examination associated with abscess cavities, micro-abscesses, and large numbers of lipid-laden macrophages, as well as a minor component of chronic and acute inflammatory cells on microscopic examination [5].

Other lesions containing foam cells should be distinguished from XGI, like Malacoplakia and Small localized xanthoma deposits [6]. Many a times, XGI mimics infiltrative cancer by presenting as a mass-like lesion with an extension of fibrosis and inflammation to the surrounding tissues [7,8]. The exact pathogenesis of XGI is not well understood but there are many hypotheses, including defective lipid transport, immunological disorders such as disturbed chemotaxis of polymorphonuclear cells and macrophages, a specific immune response toward *Proteus* and *Escherichia* infections, and lymphatic obstruction [2,4]. XGI probably represents a chronic inflammatory process in which host and microorganism interact that, leads to tissue destruction and localized proliferation of macrophages containing large amounts of lipid, which are the characteristic histological features of the disease [1].

XGI of the appendix is rare. Microscopic examination of XGI usually reveals a nodular or diffuse collection of foamy histiocytes, intermixed with varying amounts of other inflammatory cells, such as multinucleated giant cells, lymphocytes, plasma cells, and eosinophils, as well as fibrosis. Occasionally, cholesterol clefts, granulation tissue, and necrotic debris are observed with reactive lymphoid hyperplasia. Guo and Greenson [9] reviewed appendectomies over a period of 4 years. They found that XGI occurred in 8 out of 22 (36.4%) of interval appendectomies but did not occur in the emergency appendectomies group. They concluded that XGI is characteristically associated with chronic inflammation. These changes may mimic chronic inflammation associated with Crohn's disease. Kochhar *et al.* [10] reported a case of

appendicular lump which was initially managed conservatively and failed. The patient underwent right hemicolectomy after developing intestinal obstruction. Histopathological study showed features of Xanthogranulomatous appendicitis.

CONCLUSION

Aim of presenting these cases is to highlight the rarity of XGI of the appendix, presenting as acute appendicitis.

PATIENT CONSENT

Patients consent has been taken to present and publish this case series

CONFLICTS OF INTEREST

All authors have none to declare.

AUTHORS FUNDING

Nil.

REFERENCES

1. Kidney PRO. In: Peterson RO, editor. Urologic Pathology. Ch. 06. Philadelphia, PA: JB Lippincott Publishers; 1986. p. 40-6.
2. Antonakopoulos GN, Chapple CR, Newman J, Crocker J, Tudway DC, O'Brien JM, *et al.* Xanthogranulomatous pyelonephritis. A reappraisal and immunohistochemical study. *Arch Pathol Lab Med* 1988;112:275-81. PMID 3345125
3. Franco V, Aragona F, Genova G, Florena AM, Stella M, Campesi G. Xanthogranulomatous cholecystitis. Histopathological study and classification. *Pathol Res Pract* 1990;186:383-90. doi: 10.1016/S0344-0338(11)80297-9, PMID 2377572
4. Chuang YF, Cheng TI, Soong TC, Tsou MH. Xanthogranulomatous appendicitis. *J Formos Med Assoc* 2005;104:752-4. PMID 16385379
5. Cozzutto C, Carbone A. The xanthogranulomatous process. Xanthogranulomatous inflammation. *Pathol Res Pract* 1988;183:395-402. doi: 10.1016/S0344-0338(88)80085-2, PMID 3054826
6. Lo CY, Lorentz TG, Poon CS. Xanthogranulomatous inflammation of the sigmoid colon: A case report. *Aust N Z J Surg* 1996;66:643-4. doi: 10.1111/j.1445-2197.1996.tb00839.x, PMID 8859170
7. Maeda T, Shimada M, Matsumata T, Adachi E, Taketomi A, Tashiro Y, *et al.* Xanthogranulomatous cholecystitis masquerading as gallbladder carcinoma. *Am J Gastroenterol* 1994;89:628-30. PMID 8147372
8. Anadol AZ, Gonul II, Tezel E. Xanthogranulomatous inflammation of the colon: A rare cause of caecal mass with bleeding. *South Med J* 2009;102:196-9. doi: 10.1097/SMJ.0b013e318187cccc, PMID 19194269
9. Guo G, Greenson JK. Histopathology of interval (delayed) appendectomy specimens: Strong association with granulomatous and xanthogranulomatous appendicitis. *Am J Surg Pathol* 2003;27:1147-51. doi: 10.1097/00000478-200308000-00013, PMID 12883248
10. Kochhar G, Saha S, Andley M, Kumar A, Kumar A. Xanthogranulomatous appendicitis with a fulminant course: Report of a case. *J Clin Diagn Res* 2014;8:ND01-2. doi: 10.7860/JCDR/2014/8660.5230, PMID 25653988
11. Jusoh AC, Ghani SA. Xanthogranulomatous lesion in recurrent appendicitis. *Formos J Surg* 2016;49:114-8. doi: 10.1016/j.fjs.2016.01.001