

CHEILOSCOPY: STUDY OF PATTERN OF LIP PRINTS AMONG MBBS STUDENTS**MERRY PAL KAUR CHAWLA¹**, **KULDIP KUMAR¹**, **GAURAV AGNIHOTRI²**, **JASPINDER PRATAP SINGH¹**,
AASHISH SHARMA¹, **NEHA CHAUDHARY^{1*}**¹Department of Forensic Medicine and Toxicology, Government Medical College, Amritsar, Punjab, India. ²Department of Anatomy, Government Medical College, Amritsar, Punjab, India.*Corresponding author: Neha Chaudhary; Email: chaudharyneha197@gmail.com

Received: 09 March 2023, Revised and Accepted: 25 April 2023

ABSTRACT**Objective:** This study was conducted to classify and evaluate the patterns of lip prints and their variations in adult population.**Methods:** The study was conducted on 200 MBBS students of age group of 18–23 years at the Department of Forensic Medicine and Toxicology, Amritsar, including 100 males and 100 females. Lip color was applied on lips, and lip prints were taken using a strip of cellophane tape on its glued portion. Data thus obtained were compiled, scrutinized, and analyzed to find different patterns. Lip prints of each subject were divided into four quadrants and recognized as per Suzuki and Tsuchihashi's Classification.**Results:** The most common type of lip print pattern among 200 subjects was found to be Type III 28.37% cases, which was followed by Type I 19.75% cases, this was followed by Type I' and Type IV 16.25% cases each. Type II was in 14.87% cases. The least common type of lip print pattern was found to be Type V in 4.5% cases.**Conclusion:** The study concluded type III to be the most predominant pattern overall in the study population. There was no gender differentiation seen with respect to both sexes as the type III pattern was found most prevalent in both females and males.**Keyword:** Cheiloscopy, Lip prints, Identification.© 2023 The Authors. Published by Innovare Academic Sciences Pvt Ltd. This is an open access article under the CC BY license (<http://creativecommons.org/licenses/by/4.0/>) DOI: <http://dx.doi.org/10.22159/ajpcr.2023v16i9.47780>. Journal homepage: <https://innovareacademics.in/journals/index.php/ajpcr>**INTRODUCTION**

Identification plays a major role in any crime investigation. Cheiloscopy is a forensic investigation technique that deals with the identification of humans based on lip traces. "Cheiloscopy" is derived from the Greek words "cheilos" meaning "lips" and "eskopein" meaning "to see." In the past decades, lip print studies attracted the attention of many scientists as a new tool for human identification in both civil and criminal issues. Like finger prints, there are no two people with identical lip prints [1]. Lip prints are the normal lines and furrows in the form of wrinkles and grooves present in the human lip having certain individual characteristics. In 1902, anthropologist R. Fischer studied furrows on the human lips and introduced cheiloscopy. Cheiloscopy is the forensic investigation method dealing with personal identification based on the study of furrows and fissures on the lips, which are called "sulci labiorumruberorum." The labial mucosa, a part of the oral mucosa, is not smooth like the buccal mucosa or soft palate. It has many elevations and depressions, forming a characteristic pattern called lip print. The use of lip prints in identification was first noted in countries such as Poland and the USA [2]. Lip prints have unique features that can be used in situations where it is difficult to identify a dead person through fingerprints [3]. Lip prints can be identified as early as in the 6th week of intrauterine life and remain the same during the life of an individual. These prints recuperate even after trauma, inflammation, and diseases such as herpes and can be recognized without difficulty. The resemblance in the lip print patterns in members of the same family is seen supporting that hereditary factors also play a role in lip prints. It is an emerging and credible method of individual identification, based on the fact that the pattern of lines on the red part of lips is unique for each human being [4]. French criminologist Edmond Locard in the year 1932, proposed the use of lip prints for personal identification purposes.

Later on, many doctors from Japan classified the pattern of lip prints. Santos M, in the year 1967, was the first person who classified the pattern of grooves on the lips into four types that are Straight line, Curved line, Angled line, and Sine shaped curve. Suzuki and Tsuchihashi, in the year 1970, classified the lip prints into different types according to the shape and course of the grooves. Type I represents clear-cut grooves running vertically over the lips. Type I has partial length grooves of Type I variety. They do not cover the entire breadth of the lips. Type II represents the branched grooves, and Type III represents the intersected grooves. Type IV represents the reticular pattern, much like a wire mesh. Type V represents all other patterns. These are irregular non-classified patterns [5].

Aims and objectives

The aim of the study was to classify and evaluate the patterns of lip prints and their variations in adult population. The objectives of the study were to evaluate any difference in lip prints between the sexes and to evaluate if any peculiar pattern exists in relation to sex of an individual.

METHODS

This study was conducted at the Department of Forensic Medicine and Toxicology, Government Medical College, Amritsar, on 200 students of MBBS comprising 100 male and 100 female students. Written consent for willful participation in the study was taken from all the subjects. Lipstick was applied uniformly on the lips, starting at the midline and moving laterally (Figs. 1-4). Lip prints of both lips together were taken using a strip of cellophane tape on its glued portion. Then, these prints were stuck on white paper. The photographs of the prints were taken with a high-resolution camera and visualized on the computer. The lip prints of each subject were divided into four quadrants- upper right quadrant, upper left

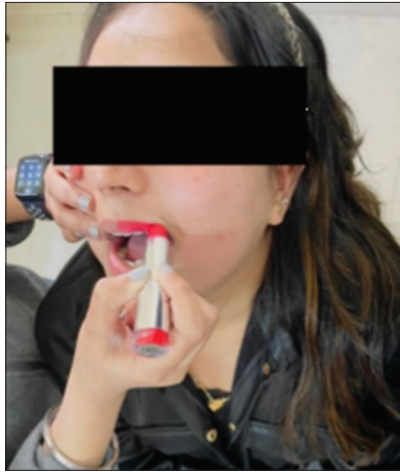

Fig. 1: Depicts method of application of lipstick from middle to left lateral end of the upper lip

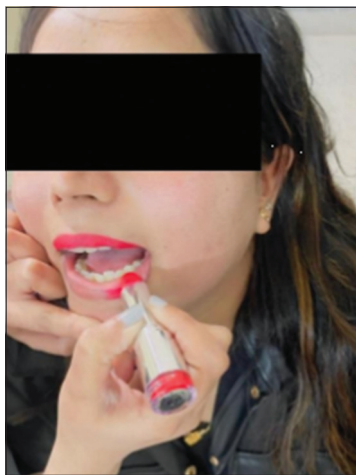

Fig. 2: Method of application of lipstick on lower lip starting from middle to left lateral end of lower lip



Fig. 3: Method of application of cellophane tape on lips



Fig. 4: Method of application of cellophane tape containing the lip print to the white paper



Fig. 5: The lip prints of each subject were divided into four quadrants upper right quadrant, upper left quadrant, lower right quadrant, and Lower left quadrant showing type I lip print

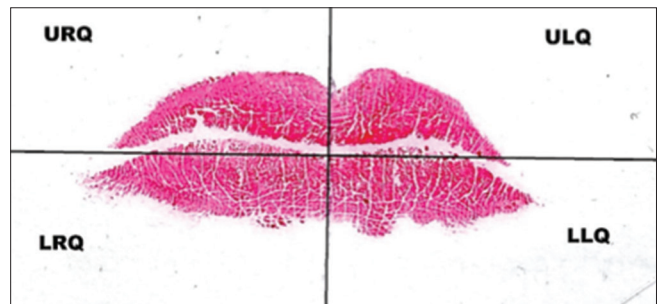


Fig. 6: The lip prints of each subject were divided into four quadrants upper right quadrant, upper left quadrant, lower right quadrant, and Lower left quadrant showing type III lip print

quadrant, lower right quadrant, and Lower left quadrant (Figs. 5-7). The lip prints collected were classified using the classification proposed by Suzuki and Tsuchihashi (1970). Data thus obtained were compiled, scrutinized, and analyzed to find different patterns in the region.

Exclusion criteria

Subjects with malformation, deformity, inflammation, trauma, surgical scars, or any other abnormalities of the lips were excluded because of their unsuitability for this study.

Ethical approval

The study was approved by the Institutional Ethics Committee, Government Medical College, Amritsar vide approval letter number 3357/D-26/2020 Batch dated January 21, 2022.

RESULTS

In the present study, there were total of 200 cases, which included 100 (50%) males and 100 (50%) female cases. Out of these, the majority

of cases 80 (40%) were found in the age group of 20 years. It was followed by the age group of 21 years with a total of 57 (28.5%) cases. In the age group of 19 years, there were 38 (19%) cases; this was followed by the age group of 22 years with total of 17 (8.5%) cases and total of 5 (2.5%) cases at the age of 18 years. The least frequency of cases, that is, 3 cases were present in the age group of 23 years. In this study, 148 (74%) cases belong to urban population, followed by 52 (26%) cases from the rural background. Out of total 200 cases, 129 (64.5%) belong to Hindu religion, followed by the Sikh religion with a total of 65 (32.5%) cases. There were 3 (1.5%) cases of Muslim religion. There were only 2 (1%) cases of Buddhism sect and only 1 (0.5%) case belonging to the Christianity. This study was in consistent with the demography of the Punjab state, in which

Hindus and Sikhs were major communities while Muslim, Christian, and Buddhism were minor communities with almost negligible population. Most of the cases, i.e., 177 (88.5%) belong to Punjab state. Only 23 (11.5%) cases belong to other states (Haryana, Chandigarh, Delhi, Rajasthan, Tamil Nadu, and Bihar). Out of total 200 cases, the most common blood group was B +ve with total of 68 (34%) cases, followed by O +ve with total of 49 (24.5%) cases. This was closely followed by A +ve blood group with 48(24%) cases. This was further followed by 19 (9.5%) cases with AB +ve blood group. The least common blood groups were A -ve, B -ve, and AB -ve with 9 (4.5%), 6 (3%), and 1 (0.5%) cases, respectively.

The most common type of lip print pattern in all the four quadrants of both upper and lower lips in all the 200 subjects was found to be Type III 28.37% cases, which was followed by Type I in 19.75% cases, this was followed by Type I' and Type IV in 16.25% cases each. Type II was found to be in 14.87% cases. The least common type of lip print pattern was found to be Type V in 4.5% cases.

The most common type of lip print pattern in 100 males was found to be Type III with 89 (22.25%) cases, which was followed by Type II with 81 (20.25%) cases. This was followed by Type I' and Type IV with 72 (18%) and 70 (17.5%) cases, respectively. This was followed by Type I with 69 (17.25%). The least common lip print pattern was found to be Type V with 19 (4.75%) (Table 1)

The most common type of lip print pattern in 100 females was found to be Type III with 138 (34.5%) cases, which was followed by Type I with 89 (22.25%) cases, followed by Type IV with 60 (15%) cases. Type I' was found to be 58 (14.5%) cases. This was followed by Type II with




Fig. 7: The lip prints of each subject were divided into four quadrants upper right quadrant, upper left quadrant, lower right quadrant, and Lower left quadrant showing type IV lip print

Table 1: Pattern of lip print in relation to all the quadrants among males

| Quadrants | Types | | | | | | Total No. (%) |
|---------------|-------------------|--------------------|--------------------|---------------------|--------------------|-------------------|---------------|
| | Type I No. (%) | Type I' No. (%) | Type II No. (%) | Type III No. (%) | Type IV No. (%) | Type V No. (%) | |
| URQ | 19 (4.75) | 19 (4.75) | 14 (3.5) | 24 (6) | 20 (5) | 4 (1) | 100 (25) |
| ULQ | 17 (4.25) | 22 (5.5) | 15 (3.75) | 25 (6.25) | 16 (4) | 5 (1.25) | 100 (25) |
| LRQ | 18 (4.5) | 13 (3.25) | 25 (6.25) | 20 (5) | 18 (4.5) | 6 (1.5) | 100 (25) |
| LLQ | 15 (3.75) | 18 (4.5) | 27 (6.75) | 20 (5) | 16 (4) | 4 (1) | 100 (25) |
| Total No. (%) | 69 (17.25) | 72 (18) | 81 (20.25) | 89 (22.25) | 70 (17.5) | 19 (4.75) | 400 (100) |

URQ: Upper right quadrant, ULQ: Upper left quadrant, LRQ: Lower right quadrant, LLQ: Lower left quadrant

Table 2: Pattern of lip print in relation to all the quadrants among females

| Quadrants | Types | | | | | | Total No. (%) |
|---------------|-------------------|--------------------|--------------------|---------------------|--------------------|-------------------|---------------|
| | Type I No. (%) | Type I' No. (%) | Type II No. (%) | Type III No. (%) | Type IV No. (%) | Type V No. (%) | |
| URQ | 23 (5.75) | 13 (3.25) | 8 (2) | 36 (9) | 17 (4.25) | 3 (0.75) | 100 (25) |
| ULQ | 23 (5.75) | 13 (3.25) | 10 (2.5) | 35 (8.75) | 16 (4) | 3 (0.75) | 100 (25) |
| LRQ | 22 (5.5) | 16 (4) | 10 (2.5) | 32 (8) | 14 (3.5) | 6 (1.5) | 100 (25) |
| LLQ | 21 (5.25) | 16 (4) | 10 (2.5) | 35 (8.75) | 13 (3.25) | 5 (1.25) | 100 (25) |
| Total No. (%) | 89 (22.25) | 58 (14.5) | 38 (9.5) | 138 (34.5) | 60 (15) | 17 (4.25) | 400 (100) |

URQ: Upper right quadrant, ULQ: Upper left quadrant, LRQ: Lower right quadrant, LLQ: Lower left quadrant

Table 3: Pattern of lip print in relation to all the quadrants in all the subjects both males and females

| Quadrants | Types | | | | | | Total No. (%) |
|---------------|-------------------|--------------------|--------------------|---------------------|--------------------|-------------------|---------------|
| | Type I No. (%) | Type I' No. (%) | Type II No. (%) | Type III No. (%) | Type IV No. (%) | Type V No. (%) | |
| URQ | 42 (5.25) | 32 (4) | 22 (2.75) | 60 (7.5) | 37 (4.625) | 7 (0.875) | 200 (25) |
| ULQ | 40 (5) | 35 (4.375) | 25 (3.125) | 60 (7.5) | 32 (4) | 8 (1) | 200 (25) |
| LRQ | 40 (5) | 29 (3.625) | 35 (4.375) | 52 (6.5) | 32 (4) | 12 (1.5) | 200 (25) |
| LLQ | 36 (4.5) | 34 (4.25) | 37 (4.625) | 55 (6.875) | 29 (3.625) | 9 (1.125) | 200 (25) |
| Total No. (%) | 158 (19.75) | 130 (16.25) | 119 (14.875) | 227 (28.375) | 130 (16.25) | 36 (4.5) | 800 (100) |

38 (9.5%) cases. The least common lip print pattern in females was Type V with 17 (4.25%) cases (Table 2).

Overall, the most common type of lip print pattern in all the four quadrants of both upper and lower lips in all the 200 subjects was found to be Type III, which was followed by Type I, this was followed by Type I' and Type IV with and then Type II. The least common type of lip print pattern was found to be Type V (Table 3).

DISCUSSION

In the present study, the most common age group was 18–23 years with a mean age of 20.26 years, which was similar to another study conducted by Varalakshmi and Cheiloscopy [5] where the students of the age group of 18–23 years were included in the study. Similar age groups from 18 to 25 years were taken by various authors that includes the studies conducted by Aparna *et al.* (2018) [6], Bai *et al.* (2018) [7], Karki (2012) [8], Sandhu *et al.* (2012) [9], Sharma *et al.* (2015) [10], Kapoor and Badiye (2017) [11], and Tarvadi and Goyal (2016) [12].

In the present study, most of the cases 177(88.5%) belonged to Punjab state and only 23 (11.5%) cases belong to other states (Haryana, Chandigarh, Delhi, Rajasthan, Tamil Nadu, and Bihar). The present study was conducted in the northern region of India. In this study, the most common lip print pattern in all the quadrants in both the upper and lower lips was Type III in 28.37% cases, which was followed by Type I in 19.75% of cases. In study conducted by Varalakshmi and Cheiloscopy (2019) [5] where the students for the study were from Mangalore region and the most common lip print pattern in both males and females was Type I. Yandava *et al.* [13] conducted a study on subjects from Hyderabad and found the most common lip print pattern in males and females was Type I'. Remya *et al.* [14] conducted a study in Kochi region and found the most common lip print pattern to be Type IV, whereas Kapoor and Badiye (2017) [11] conducted study in Maharashtra and found the most common lip print pattern was Type I in Marathi population. In another study conducted by Sharma *et al.* (2015) [10] on subjects taken from region of Rajasthan which showed the most common lip print pattern to be Type IV. Karki (2012) [8] conducted a study on Nepali population and found the most common lip print pattern in both males and females to be Type II. None of the abovementioned studies have shown pattern similar to the present study, probably due to different lineage/race factors.

In the present study, most common pattern seen in all the four quadrants in males was Type III and the least common lip print pattern was found to be Type V. The present study was similar to the study conducted by Tsuchihashi (1974) [15], Augustine *et al.* (2008) [16], Mishra *et al.* (2009) [17], Bajpai *et al.* (2011) [18], Sultana *et al.* (2014) [19], and Chimurkar *et al.* (2016) [4] who found out the Type III to be the most common lip print pattern in males. The similarity of the present study with the studies mentioned above can be due to the fact that this study was conducted in similar geographical areas. The similarity can also be proved by the same lineage of the study subjects with the present study. The findings of the present study was different from the study conducted by Sharma *et al.* (2009) [20], Telagi *et al.* (2011) [21], and Karki (2012) [8], who observed that the most common lip print pattern was Type IV, Type II, Type I, and Type I', respectively, in males.

In the present study, the highest percentage in females was Type III pattern in 138 (34.5%) cases and the least common lip print pattern was found to be Type V among 17 (4.25%) females. The findings in the present study were similar to the study conducted by Tsuchihashi (1974) [15], Augustine *et al.* (2008) [16], Mishra *et al.* (2009) [17], Kapoor and Badiye (2017) [11], Chimurkar *et al.* (2016) [4], and Tarvadi and Goyal (2016) [12] where the most common lip print pattern in females was Type III. The probable reason for the similarity between present study and these studies can be due to the same predecessors of the study population and the similarity in the lineage. The findings of the present study did not correlate with the findings of the study conducted by Sheikh *et al.* (2012) [22], Sandhu *et al.* (2012) [9], Sultana

et al. (2014) [19], and Sharma *et al.* (2015) [10] where the most common pattern in females was Type II, Type I, Type I, and Type IV, respectively. The variation with the findings of the present study could be due to reasons like differences in the race, geographical region, dietary habits, nourishment, and ethnicity of the study population.

Limitation of the study

The study being a subjective evaluation of the lip print patterns can yield errors. Further simpler and more accurate objective method of evaluation should be formulated. More studies need to be conducted to determine the predominant lip print types among the large number of racial and ethnic groups in our country. Parameters such as blood groups need to be studied with relation to lip print patterns that can help the establishment of identification further.

CONCLUSION

The most common type of lip print pattern among 200 subjects was Type III 28.37% cases and the least common was Type V in 4.5% of cases. There was no gender differentiation seen with respect to both sexes as the type III pattern was found most prevalent in both females and males.

AUTHOR'S CONTRIBUTION

Dr Merry Pal Kaur: data collection applying statistics, rechecking data and validation. Dr Kuldip Kumar: helping in preparing the manuscript. Dr Neha Chaudhary: literature search and help in preparing the manuscript.

CONFLICT OF INTEREST

None.

SOURCE OF FUNDING

Nil.

REFERENCES

- Kannan S, Muthu K, Muthusamy S, Sidhu P. Cheiloscopy - A vital tool in crime investigation. *Int J Forensic Sci Pathol* 2015;3:89-93.
- Harsha L. Correlation of lip print, finger print and blood groups in a Tamil Nadu based population. *J Pharm Sci Res* 2015;7:795-9.
- Gupta S, Gupta K, Gupta OP, Verma AK. Evaluation of the degree of agreement in identifying lip prints and palatal rugae by three independent observers and valuation of there dependability in sex determination. *Indian J Forensic Toxicol* 2014;8:214. doi: 10.5958/j.0973-9130.8.1.045
- Chimurkar VK, Ninave S, Sharma P, Ninave S. Cheiloscopy: A tool for personal and forensic identification. *J Indian Acad Forensic Med* 2016;38:15-7. doi: 10.5958/0974-0848.2016.00003.8
- Varalakshmi KL, Cheiloscopy SM. Study of lip prints in establishing identity of an individual. *Int J Anat Res* 2019;7:6751-5.
- Aparna B, Mujib BR, Shruthi NR, Patil K, Kumar NA. Evaluation and comparison of various methods of lip prints in gender determination and its stability over a period of time. *Int J Anat Res* 2018;6:5167-71.
- Bai JK, Prakash AR, Reddy AV, Rajinikanth M, Sreenath S, Reddy KV. Correlative study on lip prints, fingerprints, and mandibular intercanine distance for gender determination. *J Forensic Dent Sci* 2018;10:143-50.
- Karki RK. Lip prints-an identification aid. *Kathmandu Univ Med J (KUMJ)* 2012;10:55-7. doi: 10.3126/kumj.v10i2.7345, PMID 23132477
- Sandhu SV, Bansal H, Monga P, Bhandari R. Study of lip print pattern in a Punjabi population. *J Forensic Dent Sci* 2012;4:24-8. doi: 10.4103/0975-1475.99157, PMID 23087578
- Sharma R, Sharma K, Preethi N, Degra H. Cheiloscopy: A study of morphological patterns of lip prints in Rajasthani population. *J Res Med Dent Sci* 2015;3:35-8.
- Kapoor N, Badiye A. A study of distribution, sex differences and stability of lip print patterns in an Indian population. *Saudi J Biol Sci* 2017;24:1149-54. doi: 10.1016/j.sjbs.2015.01.014, PMID 28855806
- Tarvadi PV, Goyal AK. Cheiloscopy - role in forensic investigations. *J Pun Acad Forensic Toxicol* 2016;16:23.
- Yandava S, Babu VJ, Surendar J. Cheiloscopy-A tool of identification.

- Indian J Forensic Toxicol 2020;14:692-8.
14. Remya S, Priyadarshini T, Umadethan B, Gopalan M, Jeyaseelan N. Cheiloscopy-A study of lip prints for personal identification. J Dent Sci 2016;15:101-3.
 15. Tsuchihashi Y. Studies on personal identification by means of lip prints. Forensic Sci 1974;3:233-48. doi: 10.1016/0300-9432(74)90034-x, PMID 4858319
 16. Augustine J, Barpande SR, Tupkari JV. Cheiloscopy as an adjunct to forensic identification: A study of 600 individuals. J Forensic Odontostomatol 2008;26:44-52. PMID 22717789
 17. Mishra G, Ranganathan K, Saraswathi T, Mishra G, Ranganathan K, Saraswathi T. Study of lip prints. J Forensic Dent Sci 2009;1:28-31. doi: 10.4103/0974-2948.50885
 18. Bajpai M, Mishra N, Yadav P, Kumar S. Efficacy of lip prints for determination of sex and inter observer variability. Eur J Exp Biol 2011;1:81-6.
 19. Sultana Q, Shariff MH, Asif M, Avadhani R. Cheiloscopy: A scientific approach for personal identification. Int J Anat Res 2014;2:668-72. doi: 10.16965/ijar.2014.520
 20. Sharma P, Saxena S, Rathod V. Cheiloscopy. The study of lip prints in sex identification. J Forensic Dent Sci 2009;1:24-7.
 21. Telagi N, Mujib A, Spoorthi B, Naik R. Cheiloscopy and its patterns in comparison with ABO blood groups. J Forensic Dent Sci 2011;3:77-80. doi: 10.4103/0975-1475.92150, PMID 22408325
 22. Sheikh NA, Londhe PS. Cheiloscopy: A tool for solving crime and identification. Indian J Forensic Toxicol 2012;6:133-5.