

HISTOPATHOLOGICAL SPECTRUM OF THYROID LESIONS AT TERTIARY CARE HOSPITAL IN WESTERN RAJASTHAN

DIVYA GOYAL¹, S R NEGI¹, ABDUL SAJID², PARIDHI AHUJA^{3*}

¹Department of Pathology, Dr. S. N. Medical College, Jodhpur, Rajasthan, India. ²Department of Pathology, S. P. Medical College, Bikaner, Rajasthan, India. ³Department of Otorhino-laryngology, S. M. S. Medical College, Jaipur, Rajasthan, India.

*Correspondence author: Paridhi Ahuja; Email: paridhiahuja11@gmail.com

Received: 15 March 2023, Revised and Accepted: 11 May 2023

ABSTRACT

Objective: The objective of the study is to determine the proportion of different patterns (colloid goiter, colloid cyst, papillary carcinoma, etc.) of thyroid lesions among the patients who have undergone surgical treatment.

Methods: This was prospective and retrospective study to be conducted on 100 thyroidectomy specimens received in 5-year period (2016–2020) in Department of Pathology in Dr. S.N. Medical College, Jodhpur.

Results: Age ranged from 10 days to 85-year-old, Peak incidence of thyroid diseases was seen in the third to fifth decade, 78% non-neoplastic lesion, Adenomatous goiter was the most common non-neoplastic lesion (65%), Papillary carcinoma was the most common malignant lesion encountered.

Conclusion: Although non-invasive techniques like aspiration cytology provide a diagnosis in most, the ultimate answer often rests with histopathological examination of thyroidectomies, which forms the mainstay for a definitive diagnosis. Thorough gross and microscopic evaluation of thyroidectomies is mandatory even for non-neoplastic lesions as they sometimes harbor neoplasms.

Keywords: Thyroid neoplasm, Histomorphological, Criteria.

© 2023 The Authors. Published by Innovare Academic Sciences Pvt Ltd. This is an open access article under the CC BY license (<http://creativecommons.org/licenses/by/4.0/>) DOI: <http://dx.doi.org/10.22159/ajpcr.2023v16i10.47848>. Journal homepage: <https://innovareacademics.in/journals/index.php/ajpcr>

INTRODUCTION

The thyroid gland is present in the neck which is enclosed by the pretracheal fascia. The pretracheal fascia is a part of the deep cervical fascia. It is located in front of the 2nd, 3rd, and 4th tracheal rings and weighs around 20–25 g [1]. Thyroid glands have a variety of diseases that range from functional and immunological mediated enlargement to neoplastic lesions. Thyroid gland lesions vary in their incidence and histopathological patterns. They may also differ in terms of geographical area, age, sex, dietary, and environmental factors [2]. Around 42 million people are affected by thyroid diseases in India [3]. Clinically visible thyroid nodules are present around 4–5% of population [4].

Autoimmune thyroid disease is more common than iodine deficiency, as a cause of goiter in areas with sufficient iodine. Thyroid carcinoma closely resembles its benign counterpart in physical characteristics, measurable physiological parameters such as serum T3/T4 levels and ultrasonic characteristics. Therefore, the surgical excision of the nodule and its histological examination is the only way to differentiate between the more frequent benign and much less frequent malignant nodules. Fine needle aspiration cytology (FNAC) is an established technique for the investigation of thyroid lesions. Despite many advantages, FNAC has certain limitations which include specimen adequacy and cytological interpretation, as the sampling is variable and not always representative. Thus a specific diagnosis can only be arrived at after a histological examination [5].

Aim

The aim of the study is to determine the proportion of different patterns (colloid goiter, colloid cyst, papillary carcinoma, etc.) of thyroid lesions among the patients who have undergone surgical treatment.

METHODS

This was a prospective and retrospective study to be conducted on 100 thyroidectomy specimens received in 5-year period (2016–2020) in

Department of Pathology in Dr. S.N. Medical College, Jodhpur. Patient's clinical data including clinical details, personal history, and laboratory investigation reports were collected from medical records in surgically resected specimens. The specimen was fixed in 10% formalin and large specimens were cut serially (at 1 cm thickness) before fixing. After fixation, representative areas were selected for paraffin embedding. In case of encapsulated lesions, adequate representation from tumor capsule-thyroid interface was given. Section were cut at 4–5 microns thick and stained with hematoxylin and eosin and studied. Stained histopathology slides were studied in detail. Poor permeation of fixative into thyroid specimen was excluded from the study.

Sample size

It will be an observational study to be conducted on thyroidectomy specimens received in department of pathology, Jodhpur during the period of 5 years. Sample size was calculated at 95% confidence interval and 10% absolute allowable error using the formula for sample size for estimation of a single sample proportion

$$N = \frac{Z_{1-\alpha/2}^2 P(1-P)}{E^2}$$

Where,

$Z_{1-\alpha/2}$ = Standard normal deviate for 95% confidence interval (taken as 1.96)

P = expected proportion of neoplastic thyroid lesion (taken as 49% as per reference article)

E = allowable error (taken as 10%)

Sample size was calculated to be 96 thyroid lesions, which was enhanced and round to 100 subjects.

RESULTS

The present study is a retrospective study undertaken for a period of 5 years from 2016 to 2020. A total of 100 specimens of thyroidectomy received during this period were studied and analyzed. Thyroid lesions were seen in patients with age ranging from 10 days to 85 years. Peak incidence of thyroid lesions was seen in the third to sixth decade constituting 77 of cases. The youngest patient in our study group was a 10-day-old male, a case of thyroglossal cyst. The oldest patient was 85-year-old female, with a case of anaplastic carcinoma of thyroid (ATC). Females constituted 90% of the cases studied. The present study showed female: male ratio of 9:1 (Table 1).

Out of 100 cases, 78 cases (78%) were non-neoplastic and 22 (22%) cases were neoplastic. Among the neoplastic lesions, 11 (11%) were benign, borderline 1 (1%) and 10% (10%) were malignant.

The most common non-neoplastic lesion encountered in this study was adenomatous goiter which was present in 83.34% (65 cases) of non-neoplastic lesions. The next commonest non-neoplastic lesion encountered was thyroglossal cyst accounting for around 11.54% (9 cases). The least common were lymphocytic thyroiditis, Hashimoto's thyroiditis, and toxic multinodular goiter. Among neoplastic lesions, benign neoplasm accounted for 50% (11 cases) of cases studied, Borderline 4.54% (1 case), and 45.45% (10 cases) were malignant.

Papillary carcinoma was the most common malignant neoplasm, which was seen in 31.82% (7 cases) of malignant neoplasm. The next common malignant neoplastic lesion was follicular carcinoma, which accounted for 9.09% of cases (2 cases) followed by ATC, which was seen in 4.55% (1 case) of cases. The majority of the malignant neoplasms were seen 3rd to 5th decade constituting 71.42% of cases studied (Table 3). The youngest patient was 20-year-old female.

Papillary carcinoma was the most common malignant neoplasm in present study accounting for 63.64% (7 cases) of neoplastic lesions. The most common age of presentation was 3rd-5th decade (71.43%). The youngest patient was in the second decade (20 years) and oldest patient was a 75 years. All cases were female in the present study. Grossly, largest lesion measurement was 12 cm × 8 cm × 6 cm and

Table 1: Age and sex distribution of thyroid lesions

Age groups (in years)	Females	Males	Total
1-10	1	3	4
11-20	11	2	13
21-30	25	1	26
31-40	17	1	18
41-50	20	2	22
51-60	10	1	11
61-70	4	0	4
71-80	1	0	1
81-90	1	0	1
Total	90	10	100

Table 2: Histomorphological spectrum of thyroid lesions

Non-neoplastic lesion	Number of cases	Percentage
Adenomatous goiter	65	83.34
Thyroglossal cyst	9	11.54
Lymphocytic thyroiditis	2	2.56
Hashimoto's thyroiditis	1	1.28
Toxic multinodular goiter	1	1.28
Total	78	100
Neoplastic lesions		
Benign	11	50
Borderline	1	4.54
Malignant	10	45.45
Total	22	100

smallest lesion measurement was 3 cm × 2 cm × 1 cm. One case showed areas of cystic lesion.

DISCUSSION

A total of 100 consecutive thyroidectomy specimens received in the department of pathology of Dr. S. N. Medical college Jodhpur from 2016 to 2020 were collected and analyzed in this study. Of these, majority (90%) were female. Male accounted for 10%. A study conducted by Padmavathi and Raj [6] reviewed 211 thyroid cases of which 21 cases (9.95%) were male and 190 cases (90.04%) female.

In our study, it was observed that over 50% of cases were in age group 11-60 years. Thyroid disease was seen within age range of 9-72 years which is in concordance with Salama *et al.* [78, (n=845) who reported age range of 9-70 years. The peak incidence of thyroid diseases was seen in the third to sixth decades (21-60 years) constituting 77% of cases which was similar to the studies by Tsegaye and Ergete [7] and Ijomone *et al.* [8], who have reported 84.2%, 79.16%, 78.94% of the cases respectively in same age group.

In the present study, out of 100 cases, 78 (78%) cases were non-neoplastic and 22 (22%) cases were neoplastic. Similarly, in a study conducted by Ijomone *et al.* [7], non-neoplastic lesions constituted for 66.91%, whereas neoplastic lesion accounted for 31.57% of the cases. In another study by Padmavathi and Raj [6], 70.1% of the lesions were non-neoplastic and 29.9% were neoplastic lesions.

Non-neoplastic lesions

Adenomatous goiter was the most common non-neoplastic lesion in the present study, which accounted for 83.34% (65 cases) of non-neoplastic

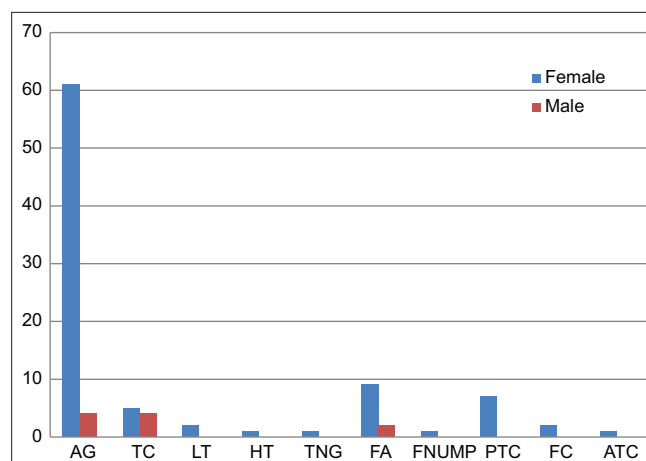


Fig. 1: Distribution of various thyroid lesions in relation to sex

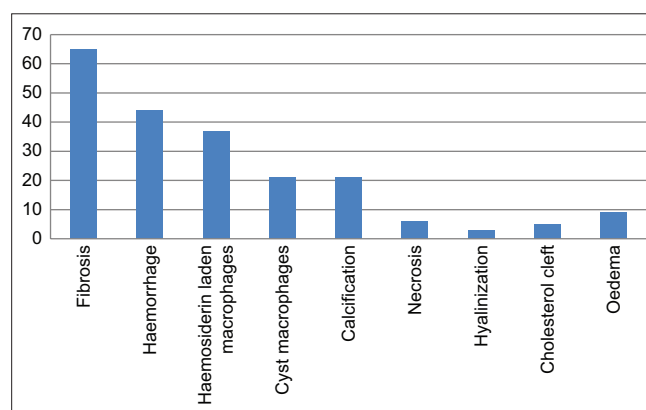


Fig. 2: Frequency of various stromal changes in adenomatous goiter

lesions and 65% of all the cases studied, followed by thyroglossal cyst 11.54% (9 cases). Other spectrum of lesions were Lymphocytic thyroiditis 2.56% (2 cases), Hashimoto's thyroiditis 1.28% (1 case), and toxic multinodular goiter 1.28% (1 case) in descending order.

Neoplastic lesions

Neoplastic lesions were 22% of the cases in present study. Among neoplastic lesions, 11 cases (50% of neoplastic lesion) were benign, 1 case (4.54% of neoplastic lesion) was borderline, and 10 cases (45.45% of neoplastic lesion) were malignant. Various studies showed prevalence of neoplastic lesions ranging from 16% to 32%.

Benign neoplastic lesions accounted for 11% (11 cases) of cases studied. In the present study, all benign lesions are follicular adenoma accounted for 100% (11 cases) of benign neoplasms. In a study conducted by Tsegaye and Ergete [7] adenoma constituted for 12.8% of the cases and 60.97% of neoplastic lesions, leading to the

2nd commonest lesion and most common neoplastic lesion. Padmavathi and Raj [6], all benign neoplasm were follicular adenoma (100% cases). Prabha and Bhuvanewari [9], 12% benign neoplasm were follicular adenoma (100% cases).

In the present study, one case was categorized as borderline neoplasm Follicular Neoplasm with Uncertain malignant potential (FNUMP) according to 2017 updates of the World Health Organization classification of thyroid tumors, which accounted for 4.54% of neoplastic lesions. Similarly, Koyuncuer *et al.* [10] have reported borderline neoplasms in 3.33% of the cases (Table 4).

In the present study, malignant neoplasms constituted 10% of the cases studied and 45.45% of neoplastic lesions. Similarly, Ijomone *et al.* [8] malignancy in 47.61% of neoplastic lesions. Tsegaye and Ergete [7] malignancy in 47.61% of neoplastic lesions. Table 4 shows comparison of neoplastic lesions in the present study with others.

Table 3: Spectrum of thyroid lesions in relation to age group

Nature of lesion	HP Diag.	Age group (in years)									Total	Percentage
		1-10	11-20	21-30	31-40	41-50	51-60	61-70	71-80	81-90		
Non-neoplastic (n=78)	AG	00	09	19	10	15	09	03	00	00	65	65
	TC	03	03	01	00	02	00	00	00	00	09	9
	LT	00	00	00	00	01	01	00	00	00	02	2
	HT	00	00	00	01	00	00	00	00	00	01	1
	TNG	00	00	00	00	00	01	00	00	00	01	1
Neoplastic; benign (n=11)	FA	01	00	04	04	02	00	00	00	00	11	11
Neoplastic; borderline (n=1)	FN UMP	00	00	01	00	00	00	00	00	00	01	1
Neoplastic; malignant (n=10)	PTC	00	01	01	03	01	00	00	01	00	07	7
	FC	00	00	00	00	01	00	01	00	00	02	2
	ATC	00	00	00	00	00	00	00	00	01	01	1
Total		04	13	26	18	22	11	04	01	01	100	100

ATC: Anaplastic carcinoma of thyroid

Table 4: Comparison of distribution of neoplastic and non-neoplastic lesions in the present study with various other studies

Study	Non-neoplastic (%)	Neoplastic (%)	Benign
			Borderline
			Malignant (%)
Tsegaye and Ergete[7] (n=780)	78.97	21.03	60.90 - 39.02
Ijomone <i>et al.</i> [8] (n=133)	66.91	31.57	52.38 - 47.61
Padmavathi and Raj[6] (n=211)	70.1	29.9	6.63 - 23.22
Prabha and Bhuvanewari[9] (n=100)	84	16	12 - 4
Koyuncuer <i>et al.</i> [10] (n=1149)	86.94	13.05	47.33 3.33 49.33
Present study (n=100)	78	22	50 4.55 45.45

Table 5: Comparison of malignant neoplastic lesions in various studies with the present study

Malignant neoplasm	Tsegaye and Ergete[7] (n=64) (%)	Prabha and Bhuvanewari[9] (n=100) (%)	Padamavathi <i>et al.</i> [6] (n=211) (%)	Present study (n=100) (%)
PTC	76.6	50	75.51	70
FC	15.6	-	4.08	20
AC	6.3	25	2.04	10

Among malignant neoplasms papillary carcinoma was the most common, which accounted for 60% of malignant lesions and 7% cases studied. Similar observation were reported by Bukhari and Sadiq [11] (n=998), where papillary carcinoma accounted for 90% of malignant neoplasms and 13.82% of cases studied. The second most common malignancy was follicular carcinoma, amounting for 2% of cases studied, followed by anaplastic carcinoma constituting 1% of the cases studied which is in concordance with Padmavathi and Raj [6], who have reported 4.08% and 2.04% of follicular carcinoma and anaplastic carcinoma respectively.

Majority of malignant neoplasm were seen from the 3rd to 5th decade of life, constituting 71.43% of the cases. Tsegaye and Ergete [7] have reported 65.62% of malignant cases in the same age group. The youngest patient was 20-year-old female who presented with papillary carcinoma. Females were more common to be affected by thyroid malignancy.

Adenomatous goiter

Adenomatous goiter was the most common entity encountered in the present study, which constituted 65% of the cases studied. Various studies by Tsegaye and Ergete [7], Qureshi *et al.* [12], Bukhari and Sadiq [11], and Albasri *et al.* [13] have reported 76.9%, 77.88%, 67.93%, and 58.2% of adenomatous goiter, respectively. Age of the patients ranged from 11 to 70 years, however, majority of the cases were seen in the age group of 21–50 years amounting to 69.23% of the cases. Tsegaye and Ergete [7] have reported 79% of the cases in this age group. The lesion was seen predominantly in females as compared to males, where females accounted for 61% (61 cases) of the cases and males constituted 4%. Tsegaye and Ergete [7] also found female preponderance where 82% of the patients were females and 18% were males.

Thyroglossal cyst

The thyroglossal cyst was the second most common entity encountered in the present study, which constituted 9% of the cases studied. Garcia *et al.* [14] have reported 7% of thyroglossal cyst. Age of patients ranged from 10 days to 45 years, however, majority of the cases were seen in the second decade.

Lymphocytic thyroiditis

Lymphocytic thyroiditis was the third most common entity encountered in the present study 2% of the cases studied. Ahmed *et al.* [15] the incidence of lymphocytic thyroiditis was 1%.

Hashimoto's thyroiditis

Hashimoto's thyroiditis was the fourth most common lesion encountered in the present study which accounted for 1% of cases studied and the patient was females which was similar to study by Qureshi *et al.* [12], who reported these lesions in 2.6% of cases with all being females, which was comparable with the present study.

Neoplastic lesions

Follicular adenoma

The benign tumors i.e., Follicular Adenomas were present in 11% of all the cases studied. In our study, follicular adenomas were the second most common lesions encountered preceded by adenomatous goiter. There was an overall female predominance with female to male ratio of 9:2. In the study conducted by Tsegaye and Ergete [7], adenomas were the second most common lesion encountered accounting for 12.8% of cases, preceded only by adenomatous goiter.

Borderline tumors

FNUMP: Present study observed 1 case of FNUMP, accounting for 1% of all the cases and 4.55% of neoplastic lesion. In the study conducted by Padmavathi and Raj [6], accounted for 3.2% (2 cases).

Malignant neoplasms

Papillary carcinoma

Papillary carcinoma was the most common malignant neoplasm encountered in the present study, which accounted for 31.82%

(7 cases) of neoplastic lesions and 70% of malignant neoplasm. The most common age of presentation was 3rd–5th decade (71.43%). The youngest patient was in the second decade (20 years). All patients were females (7 cases).

In a study conducted by Qureshi *et al.* [12], it accounted for 36.6% of the neoplastic lesion and 59.42% of malignant lesions. 75.6% of the cases presented in 3rd–4th decade with F: M ratio of 5.83:1. In another study by Bukhari and Sadiq [11], it accounted for 54.11% of the neoplastic lesions and 90.2% of malignant neoplasms, which was comparable to the present study. All these studies showed female preponderance.

Follicular carcinoma

Follicular carcinoma was the second most common malignant neoplasm of thyroid in the present study, which was seen in 2 cases, constituting 20% of malignant neoplasms. The age group in the present study ranged from 5th to 7th decade and all patients were females. Baloch and LiVolsi [16] have reported an incidence of approximately 5% among all thyroid malignancies in the USA. They have also stated that it is more prevalent (25–40%) in iodine-deficient regions; is more common in women; with wide age distribution, peaking in the fifth and sixth decades, which is in consistent with the present study. In a study conducted by Tsegaye and Ergete [7], it constituted for 15.6% of the malignant tumors (n=64).

Anaplastic carcinoma

Anaplastic carcinoma is highly aggressive thyroid malignancy composed of undifferentiated follicular thyroid cells. ATC is undifferentiated tumors of the thyroid follicular epithelium, accounting for <5% of thyroid tumors and usually presents in elderly patients. In the current study, there was one case (1%) of ATC, was an elderly female of 85 years old. Case was sarcomatoid variant histologically.

CONCLUSION

ACKNOWLEDGMENT

We are thankful to Mahatma Gandhi Hospital, Jaipur, for the encouragement and support throughout the study.

AUTHORS' CONTRIBUTION

All the authors have contributed equally.

CONFLICT OF INTEREST

The authors declare no conflicts of interest.

AUTHOR'S FUNDING

The authors hereby declare that no financial support was taken from anyone for this research, authorship, or publication of this article.

REFERENCES

- Shenoy R. Manipal Manual of Surgery with Clinical Methods. 2nd ed. Vol. 20. New Delhi: CBS Publishers and Distributors Pvt. Limited; 2010. p. 311.
- Sreedevi A, Sheela K. Histopathological spectrum of non-neoplastic and neoplastic lesions of thyroid-2 year study in a tertiary care teaching hospital. J Med Sci Clin Res 2018;6:514-9.
- Unnikrishnan AG, Menon UV. Thyroid disorders in India: An epidemiological perspective. Indian J Endocrinol Metab 2011;15:Suppl 2:S78-81. doi: 10.4103/2230-8210.83329, PMID 21966658
- Bamanikar S, Bamanikar A, Jadhav S, Jadhav P, Kumar H, Soraisham P. Cyto-histology and clinical correlation of thyroid gland lesions: A 3 year study in a tertiary hospital. Clin Cancer Investig J 2014;3:208-12. doi: 10.4103/2278-0513.132112

5. Bhargava S, Bansal R, Elhence P, Pandey S, Makkar N. Cyto-histological correlation of thyroid lesions with estrogen and progesterone receptor status on neoplastic lesions. *J Clin Diagn Res* 2012;6:811-5.
6. Padmavathi M, Raj JA. Histopathological spectrum of non-neoplastic and neoplastic lesions of thyroid: A 5-year prospective study in a tertiary care hospital. *Int J Med Sc* 2017;3:63-8.
7. Tsegaye B, Ergete W. Histopathologic pattern of thyroid disease. *East Afr Med J* 2003;80:525-8. doi: 10.4314/eamj.v80i10.8755, PMID 15250625
8. Ijomone EA, Duduyemi BM, Udoye E, Nwosu SO. Histopathological review of thyroid diseases in southern Nigeria-a ten year retrospective study. *J Med Med Sci* 2014;5:127-32.
9. Prabha V, Bhuvanewari MG. A study of histopathological spectrum of thyroid lesions: An observational study. *Int J Sci Stud* 2019;7:1-4.
10. Koyuncuer A, Bayraktar SG, ErenGürkan EG. Histopathologic examination of thyroidectomy specimens from 1149 nodular goiter patient. *Acta Med Mediterr* 2016;32:35-43.
11. Bukhari U, Sadiq S. Histopathological audit of goiter: A study of 998 thyroid lesions. *Pak J Med Sci* 2008;24:442-6.
12. Qureshi IA, Khabaz MN, Baig M, Begum B, Abdelrehaman AS, Hussain MB. Histopathological findings in goiter: A review of 624 thyroidectomies. *Neuro Endocrinol Lett* 2015;36:48-52. PMID 25789588
13. Albasri A, Sawaf Z, Hussainy AS, Alhujaily A. Histopathological patterns of thyroid disease in al-Madinah region of Saudi Arabia. *Asian Pac J Cancer Prev*. 2014;15:5565-70. doi: 10.7314/apjcp.2014.15.14.5565, PMID 25081665
14. Garcia E, Osterbauer B, Parham D, Koempel J. The incidence of microscopic thyroglossal duct tissue superior to the hyoid bone. *Laryngoscope* 2019;129:1215-7. doi: 10.1002/lary.27291. PMID 30194760
15. Ahmed Z, Chaudhary R, Umaru N. Study of prevalence of thyroid lesions in coastal region of Karnataka. *J Evol Med Dent Sci* 2013;2:6995-7002. doi: 10.14260/jemds/1245
16. Baloch ZW, LiVolsi VA. Our approach to follicular-patterned lesions of the thyroid. *J Clin Pathol* 2007;60:244-50. doi: 10.1136/jcp.2006.038604, PMID 16798933