

CLINICAL AND ANGIOGRAPHIC SPECTRUM AMONG CASES WITH LEFT MAIN CORONARY ARTERY DISEASE

BIJAY KUMAR DASH, NIRMAL KUMAR MOHANTY, PRAMOD KUMAR ROUT, SATYANARAYANROUTRAY,
RAHUL VASANTABARAI*

Department of Cardiology, SCB Medical College, Cuttack, Odisha, India. Email: drrahulbarai@gmail.com

Received: 04 March 2023, Revised and Accepted: 12 May 2023

ABSTRACT

Objective: Left main coronary artery disease (LMCA) is a significant threat factor for amplified morbidity and mortality in the analysis and treatment plan of coronary artery disease. Multivessel disease of other coronary arteries is seen in 80% of patients with left main disease. With drug-eluting stents and advances in percutaneous coronary intervention, the management of this disease is not purely surgical. Hence, angiographic profile of patients with left main coronary artery stenosis was evaluated.

Methods: A total of 700 cases of significant coronary arterial disease clinical and those underwent coronary angiography were studied and their coronary angiogram was analyzed with respect to pattern of involvement.

Results: Of these cases, 72 patients have LMCA disease of those 24 cases have obstructive and 48 cases have non-obstructive disease and among them, 63.9% were diabetic; 55.5% were hypertensive, 44.4% have dyslipidemia, and 48.6% were smokers. Mean age was 56.5 years and mode of presentation was non-ST-elevation myocardial infarction (STEMI) in 59.7%; CSA in 30.5%, and STEMI in 9.7% cases. Distal left main was most common involvement in 79.2% cases of which 61.1% have bifurcation and 18.1% have non-bifurcation lesions. Isolated ostial involvement is seen only in 6 patients. 93% had involvement of other coronary arteries, 9.7% had SVS; 22% had DVD; and 61% had TVD.

Conclusion: Overall, the incidence of LMCA disease was 10.2% and 3.4% had only significant obstructive lesion. Distal bifurcation was the most common form of involvement and TVD was reported to be the most common association.

Keywords: Left main coronary artery disease, Distal bifurcation, Coronary angiogram, Obstructive and non-obstructive disease, Diabetes, Hypertensive, Dyslipidemia.

© 2023 The Authors. Published by Innovare Academic Sciences Pvt Ltd. This is an open access article under the CC BY license (<http://creativecommons.org/licenses/by/4.0/>) DOI: <http://dx.doi.org/10.22159/ajpcr.2023v16i7.48168>. Journal homepage: <https://innovareacademics.in/journals/index.php/ajpcr>

INTRODUCTION

According to the World Health Organization statistics, the coronary artery disease predominance endures to increase in India with prompt epidemiological changeover. It has previously exceeded communicable disorders which were the chief source of mortality among India. The situation has been predictable between 1990 and 2020; they will reach 117% and 105% intensification in mortality due to coronary artery disease (CAD) in males and females correspondingly in India [1].

Left main coronary artery (LMCA) disease rests an imperative threat factor for augmented mortality and morbidity at overall phases of identification and management of coronary artery disease. Left main stem pathological explanation seems to be silent, with unpredictable demonstration: as such, it poses diagnostic, clinical management, and practical difficulties. With the arrival of drug-eluting stents, developments in percutaneous intervention, and aggressive interventional centers, the therapy of left main coronary disease is no stretched chastely surgical. Predominance of LMCA stenosis ranges among 2.5–10% [2,3]. In the present study, the clinical and angiographic profile of patients with left main coronary artery stenosis was analyzed.

METHODS

The present study is planned to perform a prospective observational research in the Department of Cardiology, SCB Medical College, Cuttack, between the duration November 2020 and November 2021. All cases with the history of coronary artery disease, i.e., elevation myocardial infarction (STEMI), non-ST-EMI, unstable angina, and chronic stable angina those undergone coronary angiography were encompassed in the present study.

Inclusion criterion

Overall, cases show the history of left main coronary artery disease whichever isolated or with additional coronary artery involvement will be encompassed in study.

Exclusion criterion

Cases exempted from this include cases with the history of valvular heart diseases, congenital heart diseases [CHDs], and cardiomyopathy.

Detailed clinical examination with standard blood tests including whole-blood count, plasma urea, serum creatinine, serum electrolytes, coagulation profile, electrocardiogram, chest X-ray, and echocardiogram by Philips HD7 machine will be done previously the technique. Coronary angiogram will be accomplished by consultant cardiologists from this department in the cath laboratory through Siemens machine with standard views. Quantitative coronary angiography will be accessed to estimate the diameter stenosis of coronary arteries. Cases showing left main coronary artery diseases (together obstructive and non-obstructive) in coronary angiogram were investigated for the subsequent variables including mode of presentation, signs and indications, threat influences, clinical characteristics, plasma examinations electrocardiogram, chest X-ray, coronary angiographic features, and in-hospital outcomes.

RESULTS

The present report studied approximately 700 coronary angiograms throughout the observational period and 72 patients (Table 1) with left main coronary artery disease which establishes around 10.2% total prevalence in the populace who underwent coronary angiogram.

Distribution of LMCA disease according to age

Mean age group of cases diagnosed with left main coronary artery disease seems to be 55.46 ± 7.02 years. Overall 72 study population, 46 number of cases seems to be between the age group of 50 and 60 years that establish 64% of all cases and 14 cases seem to be below the age of 50 years which constitute 19%; 12 patients seem to be the beyond the age of 60 years which constitute about 17% of overall cases (Table 2).

Distribution of LMCA disease according to sex

On the study population (Table 3), male cases was found to be 47 cases (65.28%) whereas female was found to be 25 cases (34.72%).

Among 47 male cases with LMCA diseases, 15 cases showed that obstructive coronary artery diseases seem to be 32%. The rest 32 cases showed non-obstructive LMCA diseases with 68% of overall cases (Fig. 1).

Among 22 female cases with LMCA diseases, 9 cases showed obstructive LMCA diseases of 36% of overall cases whereas 16 cases showed non-obstructive LMCA diseases of 64% of the overall cases of female population.

Mode of presentation

The mode of presentation of cases (Fig. 2) with LMCA diseases was evaluated among 72 cases. Non-ST-elevation myocardial infarction (NSTEMI) seems to have the mode of presentation among 43 cases with 59.7%. Stable angina found to be the mode of presentation among 22 cases with 30.5% of the cases with LMCA diseases. STEMI seems to be the mode of presentation for 7 cases with 9.7% of the cases with left main disease.

The severities of angina among the cases were demonstrated in Table 4. The severities were classified as Classes I, II, and III and number of patients and their percentage of distribution according to the severity class are tabulated.

The symptoms of LMCA among the cases were demonstrated in Table 5. The symptoms were categorized as chest pain, shortness of breath, palpitations, and pre-syncope and the number of patients affected with these individual symptoms along with their percentage of distribution according to the symptoms were tabulated.

Coronary angiogram: The distribution of lesions (Fig. 3), ostial lesions were found to be in 9 cases, with approximately as 8.3% and midshaft lesions were found to be in 9 patients, with approximately as 12.5% of overall study population. Distal left main lesions were found to be in 57 patients with approximately as of overall study population. Of the distal left main lesions, bifurcation lesions were found to be in 44 cases with 61.1% of the total lesions whereas non-bifurcation lesion of left main was observed in 13 patients with 18.1% of overall study cases.

istribution of lesions

In cases with distal bifurcation lesions (Table 6), ostial LAD involvement seems to be 58% of patients while ostial LCX involvement seems to be 29% of patients and ostial of LAD and LCX involvement is seen in 13% cases. In this study, 67 cases of the 72 cases with 93% had involvement of other coronary arteries. Coexistent single-vessel disease has 7 patients with 9.7% of overall study population. Coexistent double-vessel disease has 16 cases with 22% of overall study population. Coexistent triple-vessel disease has 44 cases with 61% of overall study population (Fig. 4).

In obstructive disease of left main disease (Table 7) in concern with the distribution of lesions, distal left main reported maximum among patients with 22 out of 24 cases happened which are about 91.66%. As far as risk factors are concerned, diabetes had highest incidence of obstructive LMCA diseases as associated with dyslipidemia, hypertension, and smoking. Concerning the distribution of lesions,

Table 1: Distribution of cases in left main coronary artery

LMCA lesion	Number of patients (%)
Obstructive	24 (3.4)
Non-obstructive	48 (6.9)

LMCA: Left main coronary artery

Table 2: Distribution of patients rendering to age groups

Age groups (years)	Number of patients (%)
30-50	14 (19)
51-60	46 (64)
61-80	12 (17)

Table 3: Distribution of sex among the cases

Sex	Obstructive, n (%)	Non-obstructive, n (%)	Total, n (%)
Male	15 (32)	32 (68)	47 (100)
Female	9 (36)	16 (64)	25 (100)
Total	24 (33.5)	48 (66.5)	72 (100)

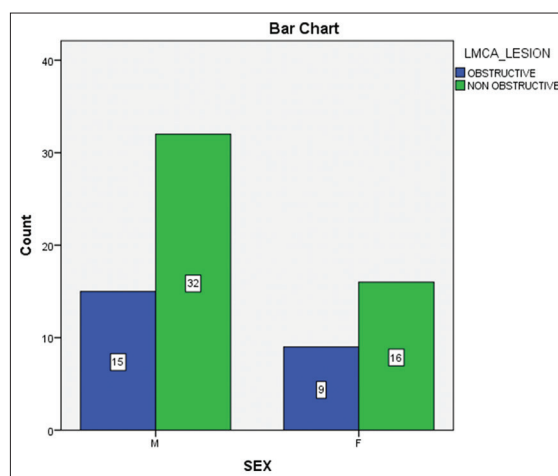


Fig. 1: Distribution of LMCA lesions

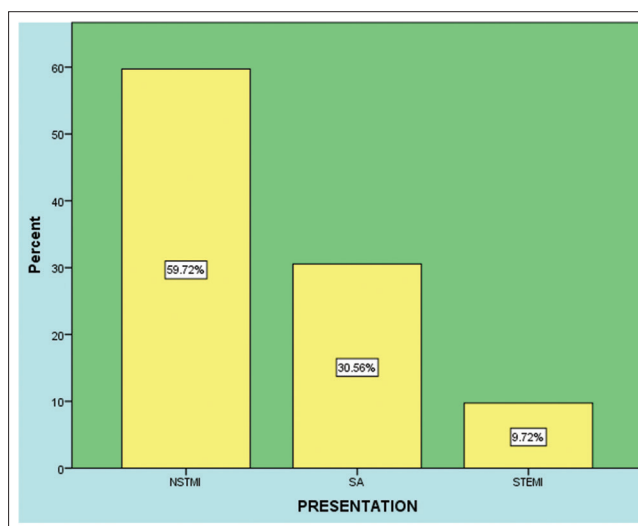


Fig. 2: Distribution of mode of presentation among patients

female cases showed more ostial involvement; out of 6 cases of ostial lesion, 5 patients were female.

Table 4: Distribution of patients by severity of angina

Severity of angina	Number of patients (%)
Class I	17 (24)
Class II	36 (50)
Class III	19 (26)

Table 5: Distribution of patients by symptoms

Symptoms	Number of patients (%)
Chest pain	67 (93)
Shortness of breath	20 (27.8)
Palpitations	4 (5.5)
Pre-syncope	0

Table 6: Pattern of involvement of other coronary arteries

Coronary artery	Number of patients (%)
LAD	66 (91.66)
LCX	45 (62.5)
RCA	53 (73.6)

LAD: Left anterior descending, LCX: Left circumflex, RCA: Right coronary artery

Table 7: Risk factors associated with left main coronary artery disease

Risk factors	Number of patients (%)
DM	46 (64)
HTN	40 (56)
Dyslipidemia	32 (44)
Smoking	35 (49)

DM: Diabetes mellitus, HTN: Hypertension

DISCUSSION

The observations revealed that 700 coronary angiograms were considered; among that, 72 cases seem to show left main coronary artery disorder, nearly 10.3% of overall study population. Similar results were found in studies by Ibrahim Shah *et al.*'s research which documented that the prevalence of LMCA disease was 10.4% [4].

The overall patients were grouped as obstructive with 20 cases of obstructive coronary artery disease and non-obstructive LMCA disease with 48 cases in that 72 cases which was about 3.4% and 6.9% of the total coronary angiogram. Comparable observations were recorded with another research documented by Ibrahim Shah *et al.* [4] and Muhammad Yousuf Shaikh *et al.* [5] which show the incidence of obstructive LMCA 3.4% and 4.5%, respectively.

This research revealed that LMCA seems to be greater in the prevalence among males with 65.3% as compared to females with 34.7%. However, in the present study, the occurrence of obstructive left main coronary disease was found to be advanced in female as associated to male populace. Frequency of obstructive LMCA in female is 36% while, in males, the incidence is 32%. This is in dissimilarity to further report supported by Muhammad Yousuf Shaikh *et al.* [5] that indicated a great prevalence of obstructive left main disease among male cases.

This study revealed that the average age presentation is 56.5 years. Of the 72 patients, 58 patients (81%) were over 50 years of age while 14 patients (19%) were below age of 50. Maximum numbers of patients were between 50 and 60 years of age (64%). A related verdict was also reported by the research documented by Muhammad Yousuf Shaikh [5]. Upon screening for investigations of threat factors, diabetes with 63.89%, HTN with 55.5%, dyslipidemia with 44.5%, and smoking with 48.61% have been observed in this current observation.

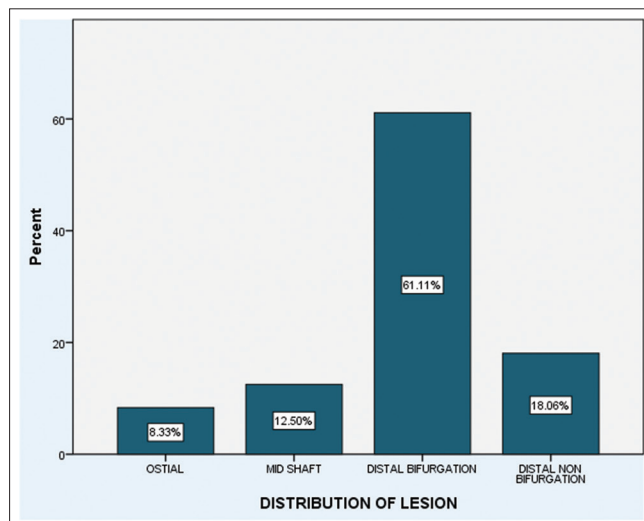


Fig. 3: Distribution of lesions among patients

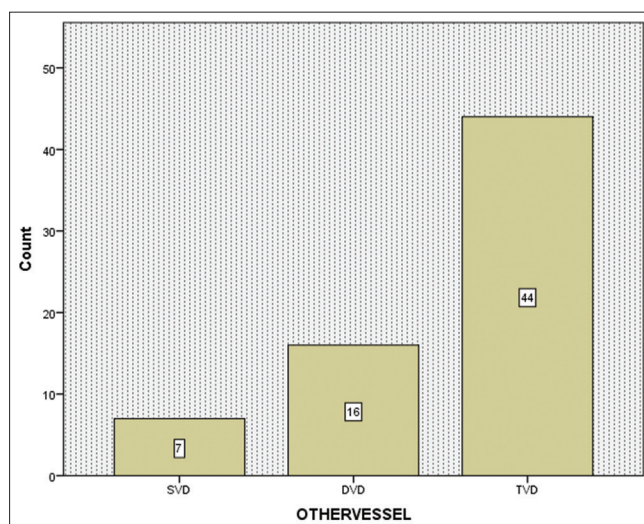


Fig. 4: Distribution of mode of presentation among patients

In case of mode of presentation in cases with obstructive left main disease, NSTEMI seems to be the common mode of presentation with 43 cases showing 59.7%, followed by stable angina as the second communal mode of presentation with 22 cases showing 30.6%; finally, STEMI was observed in 7 cases with 9.7% of total cases.

Coronary angiogram exhibited major distal LMCA lesion among 57 cases out of 72 cases, nearly 79% of overall LMCA disease patients. A research performed by Jönsson *et al.* revealed that there distal LMCA participation seems to be 65% of the 384 cases done coronary artery bypass operation [6].

In distal LMCA stenosis cases, the leading is distal bifurcation lesions including for approximately 61.1% of the overall cases, though non-bifurcating lesions showed only 18.1%. Another document researched by Ibrahim Shah *et al.* [4] showed the involvement of distal bifurcation disease to be 67%.

With respect to risk factors, obstructive distal LMCA disease is most commonly associated DM as compared to other risk factors.

In our study, ostial involvement is seen in 6 patients out of total 72 LMCA cases which is about 8.3%. Comparable consequence observed in the study performed by Jönsson *et al.* [6] documented with 9% ostial

participation. In this study, midshaft lesion involvement is found in 12.5% cases (9 patients out of 72) that in relation to the observations by Ibrahim Shah *et al.* showing 11.1% of midshaft lesion participation.

In our study, the incidence of isolated ostial LMCA stenosis between the cases those subjected to coronary angiogram seems to be 0.8%. An isolated coronary ostial disease occurs as an erratic disorder. The prevalence is found to range from 0.13% to 2.7% [7]. Among 2105 cases, Thompson *et al.* [8] described five cases with 0.2%; with 2898 cases, Yildirirturk *et al.* [9] stated 15 cases with 0.5% with isolated coronary ostial stenosis correspondingly having angiographical demarcated coronary diseases.

Out of total 6 patients with ostial stenosis, 5 ostial lesions were found in females, and reliable with additional statistics that revealed ostial lesions seems to be most communal among females and young-aged populations. Comparable outcomes were described by numerous researches, namely Sasaguri *et al.* [10], Yamanaka *et al.* [11], and Koh *et al.* [7]; Mahajan *et al.* [12] stated that isolated LMCA ostial disorders seem to be very communal among women and smoking populations.

Out of total 72 cases of LMCA disease, 67 patients have involvement of other coronary arteries which are about 93% of the total cases. In the study, Ahmad *et al.* [5] showed 94% involvement of other coronary arteries in addition to LMCA stenosis. Associated single-vessel disorders were found among 9.75% of cases, double-vessel disease was found in 22% of case, and associated triple-vessel disorder is most communal finding reported in 61.11% of patients. A document reported by Khalid *et al.* [5], the prevalence of SVD was 16%; incidence of DVD was 24.50%; and incidence of TVD was 57.40%; this change in current report is as of great percentage of individuals suffered with diabetes mellitus.

CONCLUSION

Total prevalence of left main coronary artery disease cases of persons done coronary angiogram surgery seems to be 10.2%. 3.4% was obtained in case of significant obstructive lesions patients. Fifty to sixty years form the major age group for these prevalence rates. The prevalence proportion seems to be greater in female patients than the male patients when the proportion of obstructive disease to non-obstructive disease is considered. Mode of presentation is frequently NSTEMI and stable angina occurs as the second further most presentation mode. In cases of obstructive left main diseased patients, ST elevation in avR occurs as the furthestmost communal ECG change. Isolated LMCA participation was observed very rarely but frequently establish in the ostial participation. Distal left main disease specifically bifurcation lesions seem to be the most communal lesions in coronary angiogram in cases suffered with left main disease. Two-thirds with distal left main diseased cases showed the connected triple-vessel disease.

AUTHORSHIP CONTRIBUTIONS

Dr. Bijay Kumar Dash, Dr. Nirmal Kumar Mohanty and Pramod Kumar Rout, author's involved design and data collection and editing the manuscript. Dr. Satyanarayan Routray and Dr. Rahul Vasanta Barai, authors involved in the analysis, manuscript writing, and submission.

CONFLICT OF INTEREST

Nil.

FUNDING

Nil.

REFERENCES

1. World Health Organization. World Health Statistics Annual. Switzerland: World Health Organization: 1998.
2. Kapadia SR, Ellis SG. Non-surgical management of left main coronary artery disease. *Indian Heart J* 1998;50 Suppl 1:67-73.
3. Samad A, Rasheed SZ, Ajmal H, Rehman M. Prevalence of left main coronar arctzy disease in 1000 consecutive patients undergoing coronary angiography. *Pak J Cardiol* 1592;2:70-6.
4. Shah I, Faheem M. Left main Coronary disease; clinical profile and angiographic characteristics. *J Rawalpindi Med Coll (JRMCC)* 2012;16:84-6.
5. Shaikh MY, Ahmad M, Rasheed A, Jan DM. Left main disease-patient profile. *Pak Heart J* 2007;40:19-23.
6. Jönsson A, Ivert T, Svane B, Liska J, Jakobsson K, Hammar N. Classification of left main coronary obstruction--feasibility of surgical angioplasty and survival after coronary artery bypass surgery. *Cardiovasc Surg* 2003;11:497-505. doi: 10.1016/S0967-2109(03)00111-X, PM 627973
7. Koh KK, Hwang HK, Kim PG, Lee SH, Cho SK, Kim SS, *et al.* Isolated left main coronary ostial stenosis in Oriental people: Operative, histopathologic and clinical findings in six patients. *J Am Coll Cardiol* 1993;21:369-73. doi: 10.1016/0735-1097(93)90677-s, PMID 8426000
8. Thompson R. Isolated coronary ostial stenosis in women. *J Am Coll Cardiol* 1986;7:997-1003. doi: 10.1016/s0735-1097(86)80217-0, PMID 3958382
9. Yildirirturk O, Cansel M, Erdim R, Ozen E, Demiroglu IC, Aytakin V. Coexistence of left main and right coronary artery ostial stenosis: Demographic and angiographic features. *Int J Angiol* 2011;20:33-8. doi: 10.1055/s-0031-1272550, PMID 22532768
10. Sasaguri S, Honda Y, Kanou T. Isolated coronary ostial stenosis compared with left main trunk disease. *Jpn Circ J* 1991;55:1187-91. doi: 10.1253/jcj.55.1187, PMID 1766080
11. Yamanaka O, Hobbs RE. Solitary ostial coronary artery stenosis. *Jpn Circ J* 1993;57:404-10. doi: 10.1253/jcj.57.404, PMID 8510311
12. Mahajan N, Hollander G, Malik B, Temple B, Thekkoot D, Abrol S, *et al.* Isolated and significant left main coronary artery disease: Demographics, hemodynamics and angiographic features. *Angiology* 2006;57:464-77. doi: 10.1177/0003319706290740, PMID 17022383