

THE ROLE OF AUTOLOGOUS HAMSTRING GRAFT IN IMPROVING FUNCTIONAL OUTCOME AFTER ARTHROSCOPIC ANTERIOR CRUCIATE LIGAMENT RECONSTRUCTION: PROSPECTIVE STUDY AT GGH, KURNOOL

PASUPULETI ARCHANA BABU¹, PRIYANKA^{2*}¹Department of Orthopaedics, GGH, Kurnool, Andhra Pradesh, India. ²Department of Orthopaedics, KMC, Kurnool, India.

*Corresponding author: Dr. Priyanka; E-mail: priyanka@gmail.com

Received: 12 May 2023, Revised and Accepted: 27 June 2023

ABSTRACT

Objectives: The prevalence of knee ligament injuries is on the rise due to increasing engagement in sports activities. Among the various ligaments present in the knee joint, the anterior cruciate ligament (ACL) is the most commonly injured. Several procedures have been described for the reconstruction of a torn ACL, ranging from open to arthroscopic techniques. In this particular study, we utilized an autograft from the hamstring muscle for ACL reconstruction. The graft was secured with an Endobutton on the femoral end and an interference screw at the tibial end. If necessary, cancellous screws or a suture wheel was used as well.

Methods: This is a 2-year prospective study conducted between April 2021 and March 2023 at GGH, Kurnool, which included 20 cases of complete ACL tear. All patients underwent arthroscopic ACL reconstruction using a hamstring graft. Following the procedure, all patients were assessed using the Lysholm knee scoring questionnaire and were monitored at specific intervals, including 3 months, 6 months, and 1 year, to evaluate their progress.

Results: After 1 year, the Lysholm knee scoring questionnaire was used to evaluate the results of the ACL reconstruction with the hamstring graft. The findings revealed that 30% (6 cases) of the cases reported excellent results, 50% (10 cases) of the cases showed good results, 15% (3 cases) of the cases showed fair results, and 5% (1 case) of the cases obtained poor results. In addition, 80% of patients achieved functional restoration to their pre-injury level. At 1-year follow-up, our study found that the average pre-operative Lysholm score was 63.24, while the average post-operative score was 91.98, which showed a statistically significant improvement in the post-operative Lysholm score compared to the pre-operative score ($p < 0.05$).

Conclusions: Our study suggests that the use of a hamstring graft for the reconstruction of a torn ACL can result in excellent to good outcomes. However, it should be noted that proper patient selection and physiotherapy play a significant role in achieving favorable results.

Keywords: Anterior cruciate ligament, Hamstring, Endobutton, Arthroscopy.

© 2023 The Authors. Published by Innovare Academic Sciences Pvt Ltd. This is an open access article under the CC BY license (<http://creativecommons.org/licenses/by/4.0/>) DOI: <http://dx.doi.org/10.22159/ajpcr.2023v16i11.48303>. Journal homepage: <https://innovareacademics.in/journals/index.php/ajpcr>

INTRODUCTION

The knee joint is among the most commonly injured joints, and the anterior cruciate ligament (ACL) is one of the ligaments frequently affected and may require surgical intervention [1]. The incidence of knee ligament injuries is on the rise due to increased participation in sports and road traffic accidents. The ACL, along with other knee structures, is crucial in stabilizing and maintaining the functional congruity of the knee joint [2,3]. It prevents femur posterior translation on the tibia and manages valgus and rotational forces on the knee joint [4]. Unfortunately, the capacity of the ACL to heal after it tears is minimal, making ACL reconstruction necessary to achieve a functionally stable knee joint in patients with ACL tears.

Previous studies, such as those conducted by Macaulay *et al.* [5] and Widner *et al.* [6], have demonstrated favorable outcomes for ACL reconstruction using both autografts and allografts. Various techniques, including open and arthroscopic approaches, have been developed for ACL reconstruction [7]. Historically, the most commonly used graft for ACL reconstruction was the bone-patellar tendon-bone (BPTB) graft [7]. However, this approach was associated with several complications, such as an inefficient extensor mechanism of the knee, loss of motion, patellar fractures, and continuous knee pain over the anterior aspect [8]. As a result, surgeons have sought out alternative sources of grafts for use in ACL reconstruction. The hamstring graft has emerged as a viable alternative, as it avoids jeopardizing the extensor apparatus as observed in the case of the BPTB graft [9].

Hamstring tendon grafts have demonstrated excellent outcomes in patients with ACL deficiency who undergo reconstruction with careful

patient selection. This may be due in part to the nourishment of the graft's cells by the surrounding synovial fluid, which may contribute to better survival of the quadrupled hamstring graft compared to the BPTB graft and ultimately leads to superior results [10].

Biau *et al.* conducted a meta-analysis in 2006 to compare the functional outcomes of ACL reconstruction using either BPTB or hamstring grafts. The study aimed to determine which graft provided a better functional knee joint, as determined by overall IKDC scoring and the restoration of daily and sports activities to pre-injury levels. The analysis did not reveal any significant differences in functional outcomes between the two graft types [11].

For the ACL reconstruction in our study, we utilized hamstring autografts that were secured with an Endobutton on the femoral end and an interference screw on the tibial end. If necessary, we also used cancellous screws or suture wheels in addition to these fixation methods.

The objective of our study was to investigate the effectiveness of autologous hamstring grafts in enhancing functional outcomes following arthroscopic ACL reconstruction.

METHODS

The present study was conducted in the Department of Orthopaedics, Government General Hospital, Kurnool, during the study period from May 2021 to April 2023. The study was approved by the institutional ethical review committee (IEC-KMC-GGH/9/3/2021), and written informed consent was obtained from all participants.

Our study comprised 20 patients, with 16 (88%) being male and 4 (12%) being female. Among the participants, 12 (60%) had sustained an injury on their right knee, while 8 (40%) had an injury on their left knee. The patients were observed for an average of 10.89 months, with the shortest follow-up being 6 months and the longest being 14 months.

When examining a knee injury, it is important to ask about the circumstances of the injury, such as non-contact or contact. Symptoms such as pain and instability are common, and hemarthrosis can aid in diagnosis. Tests are used to assess cruciate ligaments and menisci such as the anterior drawer test, Lachman test, pivot shift test, jerk test, Slocum's method, flexion rotation drawer test, valgus and varus laxity, McMurray's test, and Apley's grind test. X-rays and T2-weighted sequence in two to three orthogonal planes MRI scans can provide visualization of the ACL and other soft-tissue structures. Different imaging techniques can be used to detect fractures and other associated injuries. It is important to consider the patient's needs when designing treatment plans.

Surgical management

The ACL reconstruction in our study utilized specialized instruments, including a camera, light source, arthroscopy, shaver system, drill guide pins, cannula, tibial aiming guide, femoral entry point aimer, guide pins with suture eye, cannulated reamer for Endobutton passage, and sizing master board. Direct fixation devices such as interference screws and an Endobutton were used for the soft-tissue graft.

In our study, we emphasized the importance of the accurate placement of arthroscopic portals based on bone and soft-tissue landmarks to avoid joint injury or instrument damage. The four standard portals for accessing the knee joint include anterolateral, anteromedial, posteromedial, and super lateral, with optional portals such as poster lateral, proximal mid-patellar lateral and medial portals, accessory for medial and lateral portals, and central transpatellar tendon portal. Proper distension of the joint and marking of landmarks before and after distension were also highlighted for successful arthroscopy.

In our study, we followed a specific surgical technique to perform an ACL reconstruction. Initially, the patient was positioned supine, and the tendons were clipped and whipstitched together. We used a sizer to establish the proper tunnel size before inserting the composite graft through it. To locate the femoral tunnel anatomically, we used the anteromedial portal and secured the graft on the tibial and femoral sides of the bone using various techniques such as titanium interference screw, Endobutton, or both.

Before graft harvesting, we conducted a diagnostic arthroscopy by making an anterolateral portal with an 11 blade while flexing the knee at 90°. Sequentially examining the different parts of the knee joint allowed us to evaluate it thoroughly before graft harvesting.

During graft harvesting, we made a 3-cm oblique incision in the skin and identified the superior border of the pes anserine. We exposed the hamstring tendons by incising the fascia and located the semitendinosus tendon by feeling for the lowest tendon. We divided the sartorius fascia to expose it and tied the tendon ends with a double-loop knot to facilitate traction. Care was taken to preserve the deep layer containing the Medial Collateral Ligament, and we used the same incision for graft harvest and tibial tunnel drilling. Finally, we flexed the knee to 90°.

After the surgery, patients were fitted with a knee brace for 4–6 weeks. However, range of motion exercises was initiated right after the operation. The patients were permitted to bear full weight as long as they could tolerate it. Typically, patients were cleared to return to their normal level of activity approximately 3–6 months following the surgery.

In our study, we used the Lysholm scale to assess the patient's knee function and symptoms at 3 months, 6 months, and 1 year after surgery. The scale consists of eight questions, and each response is assigned

a score on a scale from 0 to 100, with higher scores indicating better outcomes and fewer symptoms or disabilities. Scores are categorized as excellent (95–100), good (84–94), fair (65–83), and poor (<65) based on the total score obtained.

RESULTS

Age incidence

The age of these patients ranged from 21 to 60 years with ACL injury being most common in 2nd and 3rd decades. In this series, 9 (45%) patients were between 21 and 30 years, 8 (40%) patients between 31 and 40 years, 2 (15%) between 41 and 50 years, and 1 (5%) patient between 51 and 60 years (Table 1).

Sex incidence

Out of 20 patients, 14 (70%) were male and 6 (30%) were female showing male preponderance (Fig. 1).

Side effects

In this study, 11 (55%) cases and 9 (45%) cases presented with ACL injury on the right and left side of the patient, respectively (Table 2).

Mode of injury

In our study, there were 10 (50%) patients with road traffic accidents, 7 (39%) sports injuries, and 3 (17%) patients with violence (Table 3).

Table 1: Age-wise distribution of study participants

Age	Frequency	Percentage
21–30	9	45
31–40	8	40
41–50	2	10
51–60	1	5

Table 2: Distribution of study participants with a side of injury

Side	Frequency	Percentage
Right	11	55
Left	9	45

Table 3: Distribution of study participants with the mode of injury

Mode of injury	Frequency	Percentage
RTA	10	50
Sports	7	35
Violence	3	15

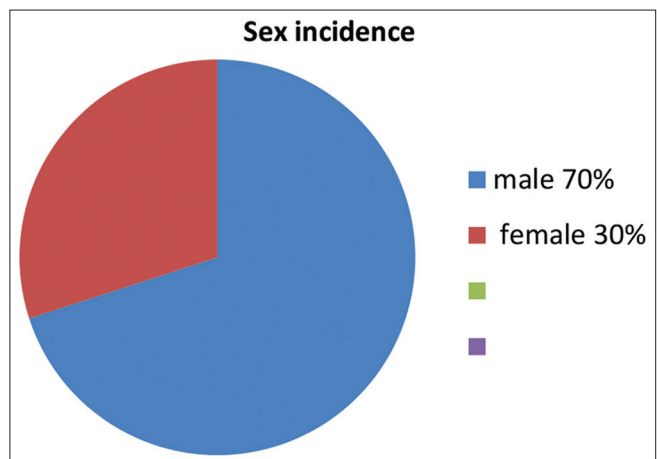


Fig. 1: Sex-wise distribution of study participants

Associated injuries

There was associated menisci injury in 17 (85%) of patients. The most injured was the lateral meniscus in 10 cases (50%), followed by injury to the medial meniscus in 6 patients (30%). Isolated ACL tear was present in 3 patients (15%) and combined in 1 case (5%) (Table 4).

Functional outcome

All patients who underwent the surgical procedure completed the Lysholm knee scoring questionnaire, which revealed that the surgical outcome was excellent in 30% (6) of the cases, good in 28% (10) of the cases, fair in 15% (3) of the cases, and poor in only 5% (1) of the cases, indicating no cases of failure (Table 5).

At 1 year follow-up, our study found that the average pre-operative Lysholm score was 63.24, while the average post-operative score was 91.98, which showed a statistically significant improvement in the post-operative Lysholm score compared to the pre-operative score ($p < 0.05$).

Complications

Two patients developed a superficial infection which resolved with further treatment.

DISCUSSION

The number of ACL reconstructions has increased due to the rising number of road accidents and sports injuries. Arthroscopic reconstruction is the preferred method and has been extensively studied. However, there is debate over the best graft option, including BPTP, hamstring auto-graft, quadriceps tendon, synthetic grafts, and allograft.

The objective of our study was to assess the functional outcome of arthroscopic ACL reconstruction using hamstring autograft. Our findings revealed that road traffic accidents were the most common cause of injury, followed by sport-related injuries. Among sport-related injuries, kabaddi, cricket, and badminton were the most common causes of ACL tears. The study showed a higher prevalence of ACL injuries in males, with 70% of patients being male and 30% being female. The majority of patients (85%) were between the ages of 20–40 years, and 55% of cases involved the right knee, while 45% involved the left knee. Notably, there was no significant difference in the lateralization of the injury.

Out of the 20 participants in our study, 14 were male and 6 were female, with the majority experiencing injury to their right knee. Interestingly, a study by Brown *et al.* [12] found that although females are more susceptible to ACL injuries, the higher incidence in males could be due to differences in exposure to injury-causing circumstances. The study

also concluded that the functional outcome of ACL reconstruction was not influenced by the side of the limb involved.

According to the Lysholm knee scoring scale used in our study, 30% of patients had an excellent outcome, 50% had a good outcome, 15% had a fair outcome, and 5% had a poor outcome. A similar study by Bourke *et al.* [13] that included 143 patients found that 94% of participants had a good or excellent Lysholm score at the 1-year follow-up. The study also reported that 67% of participants returned to their pre-injury level, while 33% did not.

The results of our study were similar to the findings of Khan *et al.* [14], which showed that ACL reconstruction using a hamstring graft can lead to favorable outcomes if the surgery is timed appropriately, an appropriate graft thickness is used, and an effective post-operative physiotherapy protocol is followed.

Kautzner *et al.* [15] conducted a study to compare the functional outcomes of ACL reconstruction using a hamstring graft versus a patellar tendon graft. The study found that both grafts led to significant improvements in the functional status and knee stability of patients who underwent ACL reconstruction. Furthermore, the study concluded that both grafts had similar results in terms of their effectiveness in improving patient outcomes.

In a study conducted by Laxdale *et al.* [16], a comparison was made between the use of a BPTB graft and a hamstring graft for ACL reconstruction. The study found that patients who underwent ACL reconstruction using a hamstring graft experienced less discomfort during the knee walking test and achieved excellent functional outcomes. These findings are consistent with the results of our study, which also found favorable outcomes for ACL reconstruction using hamstring autograft.

The study conducted by Williams *et al.* [17] reported a significant improvement in mean scoring post-operatively at the end of 2 years. The score improved from a pre-operative value of 55 to 92 post-operatively, which was statistically significant with a p-value. In comparison to our study, we also found favorable outcomes for ACL reconstruction using hamstring autograft.

Our study evaluated the functional outcome of arthroscopic ACL reconstruction using hamstring autograft, whereas the retrospective study conducted by Frank *et al.* [18] focused on the use of a 4-stranded hamstring graft for ACL reconstruction. Both studies assessed the efficacy of hamstring grafts in ACL reconstruction and reported favorable outcomes.

Gulick and Yoder [19] conducted a study on 57 patients and found that approximately 85% of the patients returned to a functional level comparable to their pre-injury status, which is similar to the results observed in our study.

CONCLUSION

Achieving favorable results in ACL reconstruction require proper case selection, accurate graft positioning and fixation, appropriate post-operative rehabilitation, and regular follow-up. The use of hamstring graft fixation with an Endobutton and interference screw has been shown to provide good functional outcomes. Arthroscopic ACL reconstruction with hamstring graft is a highly effective treatment option for ACL-deficient knees. In addition, aggressive rehabilitation therapy is recommended to regain the full range of motion and achieve better functional outcomes in a shorter period.

Limitations

The study's limitations are due to a short observation period and small sample size, as well as the fact that only a hamstring graft was used without a comparison group. These factors may affect the generalizability of the study's findings and limit its external validity.

Table 4: Distribution of study participants with associated injuries

Associated injuries	Frequency	Percentage
Lateral meniscus tear+ACL tear	10	50
Medial meniscus tear+ACL tear	6	30
Isolated ACL tear	3	15
ACL+medial meniscus+lateral meniscus tear combined	1	5

ACL: Anterior cruciate ligament

Table 5: Distribution of study participants with functional outcome

Outcome	Score	% of patients (cases no)
Excellent	Above 95	30 (6 cases)
Good	84–94	50 (10 cases)
Fair	65–83	15 (3 cases)
Poor	<65	5 (1 case)

ACKNOWLEDGMENT

We would like to express our gratitude to the Orthopaedic Department at the Government General Hospital, Kurnool, for their valuable support throughout the study.

AUTHORS CONTRIBUTION

All authors participated in every aspect of the study, including conceptualization, design, data collection, data analysis, interpretation, manuscript preparation, critical review, and approval of the final version to be published.

AUTHORS' FUNDING

This study did not receive any funding from public, commercial, or non-profit organizations.

CONFLICTS OF INTERESTS

The authors confirm that they have no conflicts of interest related to this research, authorship, and publication of this article.

REFERENCES

- Paschos NK, Howell SM. Anterior cruciate ligament reconstruction: Principles of treatment. *EFORT Open Rev* 2017;1:398-408. doi 10.1302/2058-5241.1.160032. PMID: 28461919; PMCID: PMC5367541
- Pardiwala DN, Rao NN, Anand K, Raut A. Knee dislocations in sports injuries. *Indian J Orthop* 2017;51:552-62. doi 10.4103/ortho. IJOrtho_229_17. PMID: 28966379; PMCID: PMC5609377
- Svantesson E, Senorski EH, Webster KE, Karlsson J, Diermeier T, Rothrauff BB, *et al.* Clinical outcomes after anterior cruciate ligament injury: Panther symposium ACL injury clinical outcomes consensus group. *Knee Surg Sports Traumatol Arthrosc* 2020;28:2415-34. doi: 10.1007/s00167-020-06061-x. PMID: 32767052; PMCID: PMC7429530
- Dargel J, Gotter M, Mader K, Pennig D, Koebeke J, Schmidt-Wiethoff R. Biomechanics of the anterior cruciate ligament and implications for surgical reconstruction. *Strategies Trauma Limb Reconstr* 2007;2:1-12. doi 10.1007/s11751-007-0016-6. PMID: 18427909; PMCID: PMC2321720
- Macaulay AA, Perfetti DC, Levine WN. Anterior cruciate ligament graft choices. *Sports Health* 2012;4:63-8. doi 10.1177/1941738111409890. PMID: 23016071; PMCID: PMC3435898
- Widner M, Dunleavy M, Lynch S. Outcomes following ACL reconstruction based on graft type: Are all grafts equivalent? *Curr Rev Musculoskelet Med* 2019;12:460-5. doi 10.1007/s12178-019-09588-w. PMID: 31734844; PMCID: PMC6942094
- Migliorini F, Torsiello E, Trivellas A, Eschweiler J, Hildebrand F, Maffulli N. Bone-patellar tendon-bone versus two-and four-strand hamstring tendon autografts for ACL reconstruction in young adults: A Bayesian network meta-analysis. *Sci Rep* 2023;13:6883. doi 10.1038/s41598-023-33899-1. PMID: 37106008; PMCID: PMC10140035
- Samitier G, Marcano AI, Alentorn-Geli E, Cugat R, Farmer KW, Moser MW. Failure of anterior cruciate ligament reconstruction. *Arch Bone Jt Surg* 2015;3:220-40. PMID: 26550585; PMCID: PMC4628627
- Arida C, Tsirikas CG, Mastrokalos DS, Panagopoulos A, Vlamis J, Triantafyllopoulos IK. Comparison of bone-patella tendon-bone and four-strand hamstring tendon grafts for anterior cruciate ligament reconstruction: A prospective study. *Cureus* 2021;13:e19197. doi: 10.7759/cureus.19197. PMID: 34877191; PMCID: PMC8642134
- Hadi H, Bagherifar A, Tayebi F, Ansaria M, Shahsavari-pour A, Qomashi I, Jabalameli M. Anterior cruciate ligament reconstruction with hamstring tendons has no deleterious effect on hip extension strength. *Arch Bone Jt Surg* 2019;7:278-83. PMID: 31312687; PMCID: PMC6578478
- Biau DJ, Tournoux C, Katsahian S, Schranz PJ, Nizard RS. Bone-patellar tendon-bone autografts versus hamstring autografts for reconstruction of anterior cruciate ligament: A meta-analysis. *BMJ* 2006;332:995-1001. doi 10.1136/bmj.38784.384109.2F. PMID: 16603564; PMCID: PMC1450040
- Brown TN, Palmieri-Smith RM, McLean SG. Sex and limb differences in hip and knee kinematics and kinetics during anticipated and unanticipated jump landings: Implications for anterior cruciate ligament injury. *Br J Sports Med* 2009;43:1049-56. doi: 10.1136/bjism.2008.055954. PMID: 19372596
- Bourke HE, Gordon DJ, Salmon LJ, Waller A, Linklater J, Pinczewski LA. The outcome at 15 years of endoscopic anterior cruciate ligament reconstruction using hamstring tendon autograft for 'isolated' anterior cruciate ligament rupture. *J Bone Joint Surg Br* 2012;94:630-7. doi 10.1302/0301-620X.94B5.28675. PMID: 22529082
- Khan I, Ullah S, Khattak SK, Khan Z, Ahmad I, Khan A. Functional outcome of arthroscopic anterior cruciate ligament reconstruction using hamstring autograft with fixation using endobutton at femoral end and bioabsorbable screw at tibial end. *Mymensingh Med J* 2022;31:1142-7. PMID: 36189564
- Kautzner J, Kos P, Hanus M, Trc T, Havlas V. A comparison of ACL reconstruction using patellar tendon versus hamstring autograft in female patients: A prospective randomized study. *Int Orthop* 2015;39:125-30. doi 10.1007/s00264-014-2495-7. PMID: 25128968
- Laxdale G, Kartus J, Hansson L, Heidvall M, Ejerhed L, Karlsson J. A prospective randomized comparison of bone-patellar tendon-bone and hamstring grafts for anterior cruciate ligament reconstruction. *Arthroscopy* 2005;21:34-42. doi 10.1016/j.arthro.2004.09.014. PMID: 15650664
- Williams RJ 3rd, Hyman J, Petrigliano F, Rozental T, Wickiewicz TL. Anterior cruciate ligament reconstruction with a four-strand hamstring tendon autograft. *J Bone Joint Surg Am* 2004;86:225-32. doi 10.2106/00004623-200402000-00003. PMID: 14960665
- Frank RM, Hamamoto JT, Bernardoni E, Cvetanovich G, Bach BR Jr., Verma NN, Bush-Joseph CA. ACL reconstruction basics: Quadruple (4-strand) hamstring autograft harvest. *Arthrosc Tech* 2017;6:e1309-13. doi 10.1016/j.eats.2017.05.024. PMID: 29354434; PMCID: PMC5622412
- Gulick DT, Yoder HN. Anterior cruciate ligament reconstruction: Clinical outcomes of the patella tendon and hamstring tendon grafts. *J Sports Sci Med* 2002;1:63-71. PMID: 24701126; PMCID: PMC3967431