

A CASE REPORT ON *STENOTROPHOMONAS MALTOPHILIA*VIJETA SHARMA<sup>1\*</sup>, SATENDRA SARASWAT<sup>2</sup>, VIJAYLAXMI SHARMA<sup>3</sup>, PREETI CHAUHAN<sup>4</sup><sup>1</sup>Department of Microbiology, Mahaveer Institute of Medical sciences, Bhopal, Madhya Pradesh, India. <sup>2</sup>Department of Microbiology, Sarojini Naidu Medical College, Agra, Uttar Pradesh, India. <sup>3</sup>Department of Anatomy, SMS Medical College, Jaipur, India. <sup>4</sup>Technologist, Scientific Pathology, Agra, Uttar Pradesh, India.

\*Corresponding author: Dr. Vijeta Sharma; Email: 88vijeta@gmail.com

Received: 16 October 2023, Revised and Accepted: 31 January 2024

## ABSTRACT

*Stenotrophomonas maltophilia* is stated as the Gram-negative bacterium that is often resistant to multiple antibiotics. It is among the most common cause of community-acquired pneumonia in patients with underlying medical conditions, such as diabetes and hypertension. In this case, the patient's pneumonia did not respond to empiric antibiotic treatment with ceftriaxone and azithromycin. However, his symptoms resolved after treatment with levofloxacin. This case report highlights the importance of considering *S. maltophilia* in the differential diagnosis of community-acquired pneumonia in patients with underlying medical conditions. Sputum culture with an antibiogram is essential for making the diagnosis and selecting appropriate antibiotic treatment.

**Keywords:** Gram-negative bacilli, Community-acquired pneumonia, Empiric antibiotic treatment.

© 2024 The Authors. Published by Innovare Academic Sciences Pvt Ltd. This is an open access article under the CC BY license (<http://creativecommons.org/licenses/by/4.0/>) DOI: <http://dx.doi.org/10.22159/ajpcr.2024v17i5.49632>. Journal homepage: <https://innovareacademics.in/journals/index.php/ajpcr>

## INTRODUCTION

*Stenotrophomonas maltophilia* is a Gram-negative, non-fermentative, aerobic bacteria which is formerly known as *Pseudomonas maltophilia* or *Xanthomonophilia*. It has gained significance as a notable nosocomial pathogen within clinical settings [1]. This bacterium is accountable for various infectious diseases and has been linked to fatalities among hospitalized patients, particularly those who are immunosuppressed, immunocompromised, or have medical implants [2-6]. Despite being considered a commensal organism with relatively low virulence, *S. maltophilia* exhibits opportunistic pathogenic qualities [7]. The frequent presence of this bacterium in hospital fluids, irrigation solutions, and invasive medical devices could potentially serve as a means to bypass the body's natural defenses and induce human infections [8]. *S. maltophilia* commonly leads to respiratory tract infections and can also involve areas such as eyes, biliary system, bones, joints, and urinary system [9].

## CASE REPORT

Informed consent was obtained from the patient. He was then requested to attend a question-and-answer session. After obtaining his consent, we proceeded to write this case report which was as follows: A male patient, aged 60, with underlying health conditions, has been experiencing a persistent and productive cough for the past 6 months, along with three instances of the chills and also the fever within this time frame. Along with this duration, the patient was prescribed cefotaxime sodium IP 1 mg (branded as Taxim), Amikacin sodium IP 500 mg, Ambroxol 30 mg/mL + Levosulbutamol 1 mg/5 mL + Guaifenesin 50 mg/5 mL (marketed as CapexLS Syrup), and Septran DS 800 mg. Following a 15-day treatment, a blood test and chest CT scan were conducted, showing elevated C-reactive protein, increased leucocytes, and reduced lymphocytes. In addition, a thoracic CT scan (Fig. 1) was performed, showing a large left-sided hydropneumothorax with air-fluid level. It was seen causing partial atelectasis of the left lung. Mid right-sided trachea mediastinal and cardiac shift was seen. Multiple air loculi were seen within the pleural fluid making air-fluid level, likely representing multiple septations. Thick-walled cavitation was seen in apicoposterior segment of the left upper lobe measuring 5.9 × 4.6 cm. Surrounding air space consolidation was seen. A few scattered macronodular infiltrates were seen in

posterior segments of the right lower lobe and antero-medio-basal segments of lower lobe. Fibrotic lesions and bands were seen in the left lower lobe. Multiple soft-tissue attenuation pre-vascular (15 × 11 mm), subcranial (10 × 9 mm), and right hilar (12 × 9 mm) lymph nodes were seen. An automated culture vitek-2 system was employed to conduct a sputum culture and sensitivity test. The test revealed the presence of the organism *S. maltophilia*, which exhibited sensitivity to levofloxacin, minocycline, and sulfamethoxazole/trimethoprim. Subsequently, the patient underwent a treatment regimen involving levofloxacin (500 mg/day for 15 days), leading to the successful resolution of the cough.

## DISCUSSION AND CONCLUSION

*S. maltophilia*, characterized as an opportunistic and multidrug-resistant pathogen, has a tendency to infect individuals with compromised immune systems. Its prevalence is on the rise, as evidenced by a recent surveillance report ranking it as the 5<sup>th</sup> most frequently encountered Gram-negative bacterial isolate in nosocomial settings [10]. Chronic respiratory disorders (particularly cystic fibrosis), hemodialysis patients, HIV infection, organ transplant recipients, hematologic malignancies, and chemotherapy-induced neutropenia are risk factors for this infection [11]. Notably, conventional broad-spectrum antimicrobials, including carbapenems, often fail to effectively target this specific pathogen. Although no specific dominance was observed in favor of carbapenems over other of the antimicrobials [1]. The risk stemming from antibiotic exposure exhibits a direct correlation with both the duration and quantity of antimicrobials administered [12].

Administration of targeted antibiotics becomes necessary once conclusive evidence of a *S. maltophilia* infection is confirmed, or in cases of severely ill patients with identified *S. maltophilia* growth, pending additional data. Guidelines for treatment primarily stem from *in vitro* investigations, retrospective analyses, non-randomized clinical trials, and expert insights [13].

Trimethoprim-sulfamethoxazole is the recommended initial treatment against *S. maltophilia*. It has been the primary empirical therapy for a considerable time. Higher doses (15 mg/kg or more of trimethoprim) are suggested due to its bacteriostatic effectiveness as indicated by *in vitro* studies [14], similar to its usage in severe *Pneumocystis jirovecii* pneumonia cases [15]. This antibiotic has demonstrated efficacy against

over 90% of the assessed isolates in most studies conducted thus far. However, it is worth noting that resistance rates have exhibited an increasing trend, reaching up to 22–38% in certain studies conducted in the 21<sup>st</sup> century [14].

In cases where alternative treatments are required, bactericidal fluoroquinolones present as viable options, boasting susceptibility rates of approximately 80–90%. These fluoroquinolones are advantageous due to their specific biofilm-targeting attributes and their elevated concentration in pulmonary tissues [14,15]. This group includes levofloxacin, moxifloxacin, ciprofloxacin, and rifloxacin, with the latter two showing enhanced efficacy. Other options include gatifloxacin, trovafloxacin, grepafloxacin, and sparfloracin [16]. Recent research has observed fluoroquinolone susceptibilities as low as 73% [14]. Overall, multiple studies have shown similar effectiveness to trimethoprim/sulfamethoxazole, with fluoroquinolones such as levofloxacin and moxifloxacin having a more favorable adverse effects profile [17].

As a second-line course of action, minocycline and tigecycline have demonstrated promising effectiveness against numerous isolates, exhibiting susceptibility rates ranging from around 80% to around 100%, even among isolates resistant to the trimethoprim-sulfamethoxazole [18]. In addition, the efficacy of ticarcillin-clavulanic acid has been extensively explored, establishing it as a viable treatment choice for *S. maltophilia* infections. Its susceptibility rate spans from below 50% in certain cases to surpassing 80% in others [13].

Ceftazidime is also considered an option, but reports vary with some indicating intrinsic resistance and a rise in resistance rates over time. Colistin is another favorable consideration, showing an approximate susceptibility rate of 72–77% [19]. An alternative effective agent, although less commonly employed, is chloramphenicol, which exhibits a varied spectrum of susceptibility reports [9].

Eravacycline, omadacycline, and delafloxacin have demonstrated significant *in vitro* effectiveness against *S. maltophilia* infections. In

contrast, recent reports show that newly developed antimicrobials such as “ceftazidime/avibactam [14], ceftolozane/tazobactam, meropenem/varobactam, cilastatin/relebactam, plazomicin, and fosfomycin lack activity against *S. maltophilia*” [20].

Studies have investigated antimicrobial combinations, showing promising synergistic effects. Examples include “trimethoprim-sulfamethoxazole/ciprofloxacin, ceftazidime/levofloxacin, ticarcillin/clavulanate/trimethoprim-sulfamethoxazole, ticarcillin-clavulanate/aztreonam, ticarcillin-clavulanate/trimethoprim-sulfamethoxazole, tigecycline/colistin, colistin/rifampicin, ceftazidime/minocycline, levofloxacin/erythromycin, and tigecycline/fosfomycin” [21].

Aerosolized colistin and levofloxacin administration, efflux pump inhibitors, quorum sensing interference, bacteriophage therapy, antimicrobial peptides such as silver or selenium nanoparticles, cationic compounds, cathelicidin-derived ones, plant oils, green tea epigallocatechin-3-gallate, and the use of *Bdellovibrio exovorus* are all examples of novel treatment approaches being studied to combat resistance in specific isolates [22].

Antimicrobial courses for *S. maltophilia* pneumonia usually last for about 7 days, but in immunocompromised patients, it can be extended to 10–14 days. Bacteremia cases are typically treated for 14 days.

#### AUTHOR CONTRIBUTIONS

The author VS and SS is principal investigator and coinvestigator respectively involved in the study design, conception, data collection, analysis, and report writing of the study. All authors involved in editing and review of manuscript.

#### CONFLICTS OF INTEREST

The study was supported by Scientific Pathology, Uttar Pradesh, India, but has no role in data collection and analysis of the study.

#### FUNDING SOURCES

Self-funded.

#### REFERENCES

- Senol E. *Stenotrophomonas maltophilia*: The significance and role as a nosocomial pathogen. *J Hosp Infect.* 2004;57(1):1-7. doi: 10.1016/j.jhin.2004.01.033, PMID 15142709
- Muder RR, Yu VL, Dummer JS, Vinson C, Lumish RM. Infections caused by *Pseudomonas maltophilia*. Expanding clinical spectrum. *Arch Intern Med.* 1987;147:1672-4.
- Calza L, Manfredi R, Chiodo F. *Stenotrophomonas (Xanthomonas) maltophilia* as an emerging opportunistic pathogen in association with HIV infection: A 10-year surveillance study. *Infection.* 2003;31(3):155-61. doi: 10.1007/s15010-003-3113-6, PMID 12789473
- Cernohorská L, Votava M. Determination of minimal regrowth concentration (MRC) in clinical isolates of various biofilm-forming bacteria. *Folia Microbiol (Praha).* 2004;49(1):75-8. doi: 10.1007/BF02931650, PMID 15114870
- Yeshurun M, Gafer-Gvili A, Thaler M, Keller N, Nagler A, Shimoni A. Clinical characteristics of *Stenotrophomonas maltophilia* infection in hematopoietic stem cell transplantation recipients: A single center experience. *Infection.* 2010;38(3):211-5. doi: 10.1007/s15010-010-0023-2, PMID 20425134
- Hentrich M, Schalk E, Schmidt-Hieber M, Chaberny I, Mousset S, Buchheidt D, et al. Central venous catheter-related infections in hematology and oncology: 2012 updated guidelines on diagnosis, management and prevention by the infectious diseases working party of the German society of hematology and medical oncology. *Ann Oncol.* 2014;25:936-47. doi: 10.1093/annonc/mdt545
- Gnanasekaran S, Bajaj R. *Stenotrophomonas maltophilia* bacteremia in end-stage renal disease patients receiving maintenance hemodialysis. *Dial Transplant.* 2009;38:30-2. doi: 10.1002/dat.20276
- De Oliveira-Garcia D, Dall'Agnol M, Rosales M, Azzuz AC, Alcántara N, Martínez MB, et al. Fimbriae and adherence of *Stenotrophomonas*

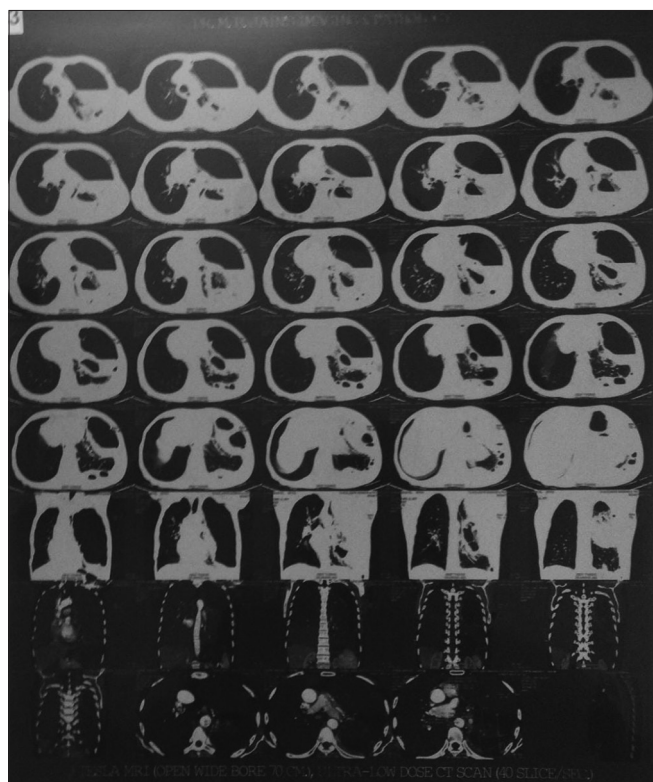


Fig. 1: CT scan large left-sided hydropneumothorax with air-fluid level

- maltophilia* to epithelial cells and to abiotic surfaces. Cell Microbiol. 2003;5:625-36. doi: 10.1046/j.1462-5822.2003.00306.x
9. Brooke JS. *Stenotrophomonas maltophilia*: An emerging global opportunistic pathogen. Clin Microbiol Rev. 2012;25(1):2-41. doi: 10.1128/CMR.00019-11, PMID 22232370
  10. Safdar A, Rolston KV. *Stenotrophomonas maltophilia*: Changing spectrum of a serious bacterial pathogen in patients with cancer. Clin Infect Dis. 2007;45(12):1602-9. doi: 10.1086/522998, PMID 18190323
  11. Willsey GG, Eckstrom K, LaBauve AE, Hinkel LA, Schutz K, Meagher RJ, et al. *Stenotrophomonas maltophilia* differential gene expression in synthetic cystic fibrosis sputum reveals shared and cystic fibrosis strain-specific responses to the sputum environment. J Bacteriol. 2019;201(15):e00074-19. doi: 10.1128/JB.00074-19, PMID 31109991
  12. Looney WJ, Narita M, Mühlemann K. *Stenotrophomonas maltophilia*: An emerging opportunist human pathogen. Lancet Infect Dis. 2009;9(5):312-23. doi: 10.1016/S1473-3099(09)70083-0, PMID 19393961
  13. Nicodemo AC, Paez JI. Antimicrobial therapy for *Stenotrophomonas maltophilia* infections. Eur J Clin Microbiol Infect Dis. 2007;26(4):229-37. doi: 10.1007/s10096-007-0279-3, PMID 17334747
  14. Matson HH, Jones BM, Wagner JL, Motes MA, Bland CM. Growing resistance in *Stenotrophomonas maltophilia*? Am J Health Syst Pharm. 2019 2;76(24):2004-5. doi: 10.1093/ajhp/zxz247, PMID 31789358
  15. Abbott IJ, Slavin MA, Turnidge JD, Thursky KA, Worth LJ. *Stenotrophomonas maltophilia*: Emerging disease patterns and challenges for treatment. Expert Rev Anti Infect Ther. 2011;9(4):471-88. doi: 10.1586/eri.11.24, PMID 21504403
  16. Weiss K, Restieri C, De Carolis E, Laverdière M, Guay H. Comparative activity of new quinolones against 326 clinical isolates of *Stenotrophomonas maltophilia*. J Antimicrob Chemother. 2000;45(3):363-5. doi: 10.1093/jac/45.3.363, PMID 10702558
  17. Watson L, Esterly J, Jensen AO, Postelnick M, Aguirre A, McLaughlin M. Sulfamethoxazole/trimethoprim versus fluoroquinolones for the treatment of *Stenotrophomonas maltophilia* bloodstream infections. J Glob Antimicrob Resist. 2018;12:104-6. doi: 10.1016/j.jgar.2017.09.015, PMID 28964955
  18. Jacobson S, Junco Noa L, Wallace MR, Bowman MC. Clinical outcomes using minocycline for *Stenotrophomonas maltophilia* infections. J Antimicrob Chemother. 2016;71(12):3620. doi: 10.1093/jac/dkw327, PMID 27516472
  19. Gales AC, Reis AO, Jones RN. Contemporary assessment of antimicrobial susceptibility testing methods for polymyxin B and colistin: Review of available interpretative criteria and quality control guidelines. J Clin Microbiol. 2001;39(1):183-90. doi: 10.1128/JCM.39.1.183-190.2001, PMID 11136768
  20. Doi Y. Treatment options for carbapenem-resistant Gram-negative bacterial infections. Clin Infect Dis. 2019 13;69(Suppl 7):S565-75. doi: 10.1093/cid/ciz830, PMID 31724043
  21. Hu LF, Gao LP, Ye Y, Chen X, Zhou XT, Yang HF, et al. Susceptibility of *Stenotrophomonas maltophilia* clinical strains in China to antimicrobial combinations. J Chemother. 2014;26(5):282-6. doi: 10.1179/1973947814Y.0000000168, PMID 24588423
  22. Gil-Gil T, Martínez JL, Blanco P. Mechanisms of antimicrobial resistance in *Stenotrophomonas maltophilia*: A review of current knowledge. Expert Rev Anti Infect Ther. 2020;18(4):335-47. doi: 10.1080/14787210.2020.1730178, PMID 32052662