

A STUDY OF VISUAL OUTCOME AND COMPLICATIONS OF SCLERAL-FIXATED INTRAOCULAR LENS

KAMLESH NAJUKRAM LANJE¹, RAJESH B GOTEKAR², SREELAKSHMI PILLAI³

Department of Ophthalmology, Bharati Vidyapeeth (Deemed To Be) University, Medical College and Hospital, Sangli, Maharashtra, India

*Corresponding author: Sreelakshmi Pillai, E-mail: pillaisree1509@gmail.com

Received: 13 March 2024, Revised and Accepted: 23 April 2024

ABSTRACT

Objectives: Objectives of this study are to find indications for the scleral-fixated intraocular lens, to measure visual acuity in patients with scleral-fixated intraocular lens postoperatively and also to note the complications of scleral-fixated intraocular lens intra and postoperatively.

Materials and Methods: The study includes 36 eyes of 36 aphakic patients presenting to Ophthalmology department between November 2019 and April 2021 after obtaining Institutional Ethical Committee Clearance. Informed and written consent were obtained from each patient included in the study. Goldmann applanation tonometer was used to record IOP for all cases preoperatively. Detailed ophthalmic examination was done on slit-lamp biomicroscope and best corrected visual acuity was recorded. Keratometry was done using an autorefractokeratometer. The axial length of the eye was calculated with the help of A scan biometry in aphakic mode. IOL power was then calculated with the SRK T formula using 118.2 as A constant for SFIOL. Patients underwent anterior vitrectomy followed by scleral fixation intraocular lens implantation by Gabor's technique after the detailed preoperative examination. The postoperative examination was done on day 1, day 7, at 1 month, and at 3 months, and the findings were noted.

Result: Out of 36, 25 (69%) patients were having surgical aphakia due to complications of cataract surgery. 5 (14%) patients were having aphakia due to trauma to the eye and 6 (17%) patients were having spontaneous dislocation of lens. Good visual outcome was observed postoperatively. Improvement in BCVA to 6/18 or more was observed in all 36 (100%) patients at the end of 1 month. Corneal edema, AC flare, vitreous hemorrhage, and increase in intraocular pressure were some of the complications that were noted in the immediate postoperative period. However, all the complications had resolved at the end of 1 month.

Conclusion: From this study, we can conclude that combined anterior vitrectomy and scleral-fixated sutured PCIOL implantation is an effective and safe procedure to correct aphakia in eyes without adequate capsular support. It provides excellent visual outcome with less postoperative complications. Furthermore, it is a superior alternative to ACIOLs and iris-fixated IOLs as it decreases the complications such as bullous keratopathy, UGH syndrome, iritis, and CME.

Keywords: Surgical aphakia, Cataract, Gabor's technique, BCVA

© 2024 The Authors. Published by Innovare Academic Sciences Pvt Ltd. This is an open access article under the CC BY license (<http://creativecommons.org/licenses/by/4.0/>) DOI: <http://dx.doi.org/10.22159/ajpcr.2024v17i7.50296>. Journal homepage: <https://innovareacademics.in/journals/index.php/ajpcr>

INTRODUCTION

In modern ophthalmology, aphakia is considered as a complication of cataract surgery. Crystalline lens is responsible for approximately 30% of the total ocular dioptric power. Therefore, surgical removal of the crystalline lens results in marked visual disability [1]. One of the great successes of modern ophthalmology is development of safe, effective IOLs for correction of aphakia. Early lens designs and fixation sites were associated with an unacceptably high rate of complications but with the development of modern posterior chamber IOLs remarkable safety and excellent visual outcome can be achieved after insertion into the capsular bag [2,3]. One of the major complications of modern cataract extraction surgeries is posterior capsule tear. When the posterior capsule tear is large or the anterior capsular rim is unstable, scleral-fixated intraocular lenses (SFIOL) or anterior chamber intraocular lenses (ACIOL) or iris claw can be implanted.

SFIOL has certain advantages over ACIOL such as less corneal endothelial damage, minimizing aniseikonia in contralateral eyes that are phakic or pseudophakic with a posterior chamber IOL in place [4-8].

Since the discovery of the scleral-fixated intraocular lenses by Parry in 1950, various changes and various techniques have emerged for its fixation. Placement of the IOL in the posterior chamber reduces the risk of bullous keratopathy, damage to anterior chamber angle structures, damage to corneal endothelium, pupillary block glaucoma,

and pseudophacodonesis. In addition, positioning the lens closer to the rotational center of the eye may reduce the centrifugal forces on the lens and stabilize the ocular contents, decrease the magnification associated with contact lenses, optical aberrations associated with aphakic spectacles and imparts superior optical properties to the eye [7].

Although SFIOLs have good visual outcome and have been proved to be a good alternative to other secondary IOL implantation procedures, it has some disadvantage of its own.

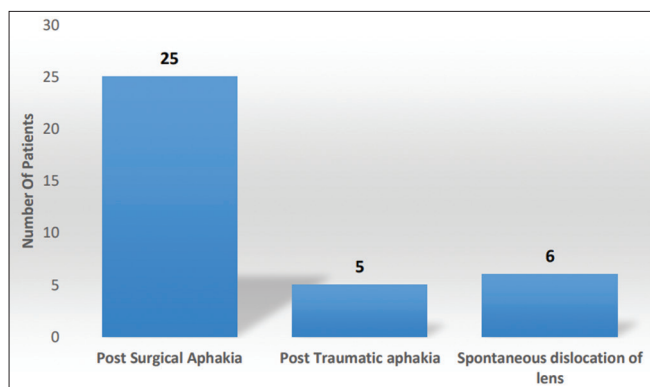
This study is conducted in view of studying the visual outcome and various intraoperative and postoperative complications associated with SFIOL (scleral-fixated intraocular lens).

METHODS

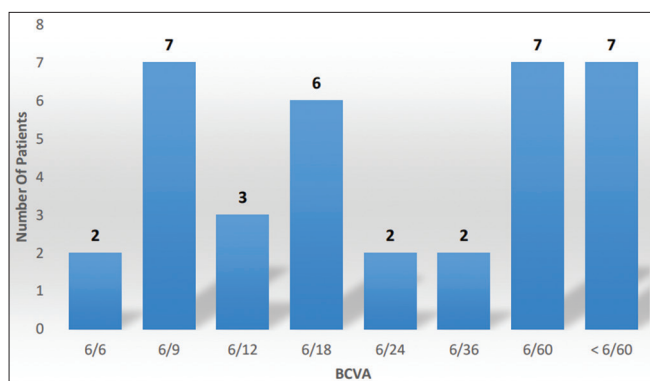
This study was done at Ophthalmology department of Bharati Vidyapeeth (Deemed to be University) Medical College and Hospital, Sangli. The study includes 36 eyes of 36 aphakic patients presenting to Ophthalmology department between November 2019 and April 2021 after obtaining Institutional Ethical Committee Clearance (BVDUMC&H/Sangli/IEC/Dissertation 2019-2020/300).

Inclusion criteria

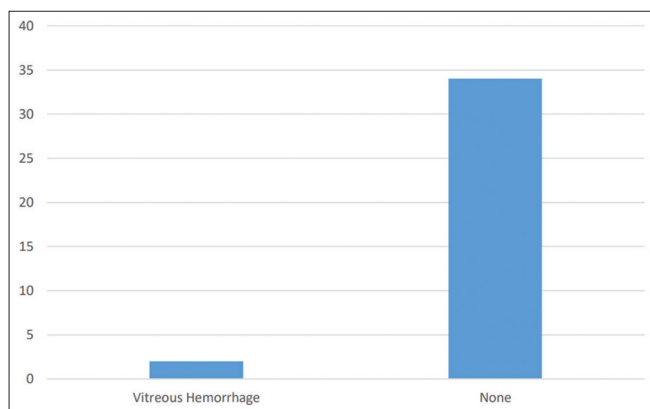
1. Complicated cataract cases with capsular bag rupture with surgical aphakia



Graph 1: The indications for SFIOL in patients.



Graph 2: Preoperative best-corrected visual acuity (BCVA) in patients.



Graph 3: Complications observed intraoperatively

- Cases with eye trauma with aphakia with total absence of capsular bag
- Cases with ectopia lentis.

Exclusion criteria

- Patients with preexisting corneal, vitreous, choroidal, or retinal pathology
- Patient who did not complete 3-month follow-up
- Aphakic patients who fulfill the inclusion criteria were included in the study.

This hospital-based prospective study was performed on 36 eyes of 36 patients with aphakia attending Department of Ophthalmology at Bharatividyaapeeth (Deemed to be University) Medical College and Hospital, Sangli, after fulfilling inclusion and exclusion criteria. Informed and written consent were obtained from each patient

included in the study. The evaluation of the patients started with detailed history. Patients were asked about their age, gender, duration of aphakia, history of trauma, history of past ocular surgery, and presence of diplopia. History of certain systemic diseases such as diabetes, hypertension, cardiac diseases, bronchial asthma, homocystinuria, and Marfan's syndrome was asked. All patients underwent a meticulous ocular examination. After taking the detailed history, examination of the patient was done. Baseline visual acuity without correction and with correction was obtained in all individuals with Snellen's distance visual acuity chart and near acuity. Goldmann applanation tonometer was used to record IOP for all cases preoperatively. Detailed examination of conjunctiva, cornea, anterior chamber, iris, and lens was done on slit-lamp biomicroscope. Using indirect ophthalmoscope with +20D lens, detailed fundus examination was done. Keratometry was done using autorefractometer and K1 and K2 readings were taken. Axial length of the eye was calculated with help of A scan biometry in aphakic mode. IOL power was then calculated with SRK T formula using 118.2 as A constant for SFIOL. Patients underwent anterior vitrectomy followed by scleral fixation intraocular lens implantation by Gabor technique after detailed preoperative examination. Postoperative examination was done on day 1, day 7, at 1 month, and at 3 months and the findings were noted.

OBSERVATION AND RESULTS

A prospective study of 36 eyes of 36 patients having unilateral aphakia was done from November 2019 to April 2021. Patients underwent scleral fixation intraocular lens implantation after detailed preoperative examination. Postoperative examination was done on day 1, day 7, at 1 month, and at 3 months and the findings were noted.

Distribution of patients according to age

Mean age of the patients was found to be 59.13 years (SD±16.56). 30 patients (83%) were in the age group 41–80 years. 3 patients (8%) were in age group 21–30 years. 1 (3%) patient each was in age group 10–20 years, 31–40 years, and 81–90 years, respectively.

Distribution of patients according to their gender

Out of 36 patients, 17 (47%) were males and 19 (53%) were females with male: female ratio of 0.9:1.

Profile of systemic diseases in patients

Out of 36 patients, 29 (81%) did not have any systemic comorbidities. 7 (19%) patients had hypertension and 5 (14%) had diabetes mellitus.

Laterality of the eye

In this study, the right eye was involved in 20 (55%) patients and the left eye was involved in 16 (44%) patients.

Graph 1 represents the indications for SFIOL in the study subjects. Out of 36, 25 (69%) patients were having surgical aphakia due to complication of cataract surgery. 5 (14%) patients were having aphakia due to trauma to the eye and 6 (17%) patients were having spontaneous dislocation of lens. Graph 2 shows pre-operative BCVA in the study subjects. 2 patients had a BCVA of 6/6 whereas <6/60 was observed in 7 patients.

18 (50%) patients had BCVA 6/18 or more on Snellen's visual acuity chart. In 14 (38%) patients, BCVA was 6/60 or less. 2 patients each (12%) had BCVA 6/24 and 6/36, respectively.

Table 1 shows preoperative intraocular pressure (IOP) of the patients in mmHg. 29 (80%) patients had IOP between 10 and 20 mmHg. 6 (17%) patients had IOP more than 20 mmHg and 1 (3%) patient had IOP <10 mmHg. Graph 2 shows pre-operative BCVA in the study subjects. 2 patients had a BCVA of 6/6 whereas <6/60 was observed in 7 patients.

Table 2 shows best corrected visual acuity on POD-1. 6/6 vision was achieved by 8% of the cases on POD-1 whereas <6/60 visual acuity was achieved by 19% of the patients.

Table 1: Preoperative intraocular pressure

IOP (mmHg)	Number of patients (%)
<10	1 (3)
10–20	29 (80)
21–30	5 (14)
>30	1 (3)

IOP: Intraocular pressure

Table 2: Best corrected visual acuity on POD-1

BCVA	Number of patients	Percentage %
6/6	3	8
6/9	7	19
6/12	2	6
6/18	8	23
6/24	2	6
6/36	3	8
6/60	4	11
<6/60	7	19

Table 3: Best corrected visual acuity on POD-7

BCVA	Number of patients	Percentage %
6/6	7	19
6/9	14	39
6/12	9	25
6/18	5	14
6/24	0	0
6/36	0	0
6/60	1	3
<6/60	0	0

Table 4: Best corrected visual acuity at 1 month post-operatively

BCVA	Number of patients	Percentage %
6/6	8	22
6/9	21	58
6/12	6	17
6/18	1	3
6/24	0	0
6/36	0	0
6/60	0	0
<6/60	0	0

Table 3 shows best corrected visual acuity on POD-7. 6/6 vision was achieved by 19% of the cases on POD-1 whereas 0% patients had visual acuity <6/60.

Table 4 shows Best corrected visual acuity at 1 month post operatively. 22% patients had a visual acuity of 6/6.

This shows that there has been a gradual improvement in the BCVA post operatively.

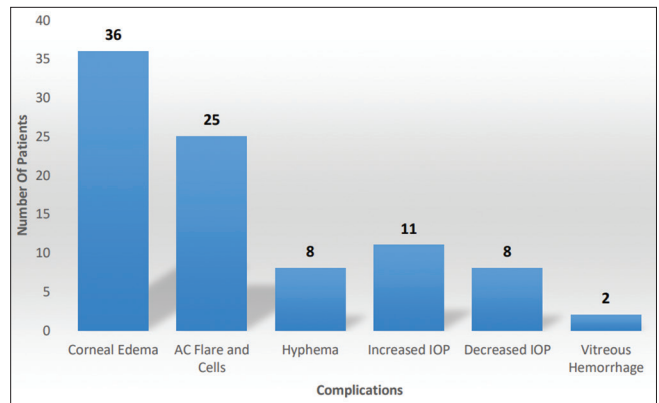
Graph 3 shows complications observed intra-operatively. Out of 36 patients, vitreous hemorrhage was observed in 2 (6%) patients. 34 (94%) did not have any intraoperative complications.

Graph 4 shows postoperative complication observed on day 1. All 36 (100%) patients had corneal edema on day 1. AC reaction (Flare and cells) were observed in 25 (70%) patients. 8 (23%) patients had hyphema and 2 (6%) patients had vitreous hemorrhage. Increase in IOP was observed in 15 (42%) patients whereas 8 (22%) patients had decreased IOP.

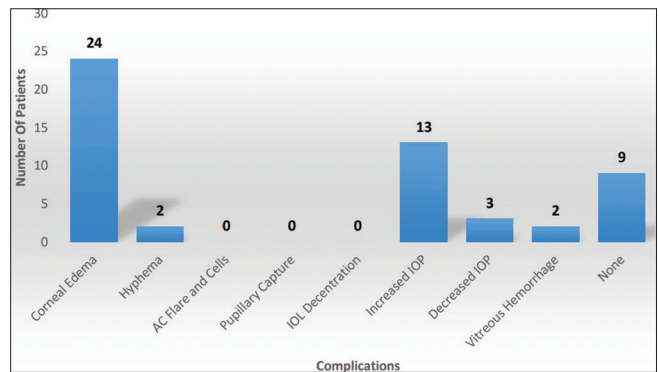
Graph 5 shows postoperative complications observed on day 7. 24 (67%) had corneal edema on day 7 as compared to 36 (100%)

Table 5: Complication profile at 1 month post operatively

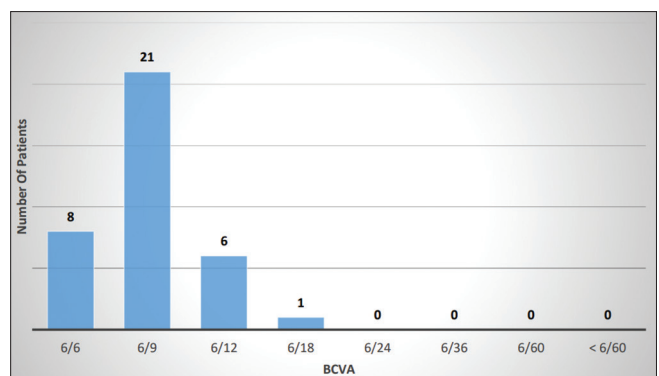
Complications	Number of cases	Percentage
Corneal edema	0	0
Hyphaema	0	0
AC flare and cells	0	0
Pupillary capture	0	0
IOL decentration and tilt	0	0
Increased IOP	0	0
Decreased IOP	0	0
Vitreous haemorrhage	0	0
None	36	36



Graph 4: Complication profile on POD-1



Graph 5: Complication profile on postoperative day 7



Graph 6: BCVA at 1 month postoperatively

on day 1. Hyphema was observed in 2 (6%) patients as compared to 8 (22%). 13(36%) patients had increased IOP whereas 3(8%) patients had decreased IOP. Vitreous hemorrhage was present in 2 (6%) patients. 9 (25%) patients showed complete resolution of complications.

Table 6: Best corrected visual acuity at 3 months post-operatively

BCVA	Number of patients	Percentage %
6/6	10	28
6/9	21	58
6/12	4	11
6/18	1	3
6/24	0	0
6/36	0	0
6/60	0	0
<6/60	0	0

Table 7: Complication profile at 3 months post operatively

Complications	Number of cases	Percentage
Glaucoma	0	0
Pupil deformation	0	0
Persistent uveitis	0	0
Cystoid macular edema	0	0
Vitreous prolapse in AC and haemorrhage	0	0
IOL Decentration	1	3
Suture Erosion	0	0
Pseudophakic Bullous keratopathy	0	0
None	35	97

Graph 6 shows BCVA at 1-month follow-up. Improvement in BCVA to 6/18 or more was observed in all 36 (100%) patients.

Table 5 shows postoperative complications observed at 1 month. There were no complications at the end of 1-month follow-up period.

Table 6 shows BCVA at 3-month follow-up. Improvement in BCVA to 6/18 or more was observed in all 36 (100%) patients. Table 7 shows complication profile at 3 months post operatively. IOL decentration was present in one case. No other complications were noted.

DISCUSSION

The most common indication for SFIOL in our study was surgical aphakia as a complication of cataract surgery found in 25 (69%) patients followed by spontaneous dislocation or subluxation of lens found in 6 (17%) patients. This was comparable to study conducted by Lee *et al.* [7] where 68% of patients had surgical aphakia at the time of presentation. In our study, intraoperative complications were observed in the form of vitreous hemorrhages in 2 (6%) patients. There were similar intraoperative complications observed in a similar study conducted by Hera *et al.*

In this study, BCVA was measured and postoperative complications were noted on day 1, day 7, at 1 month, and at 3 months. On day 1, BCVA improved to 6/18 or more in 20 (56%) patients. On the 7th-day follow-up, 30 (97%) patients showed improvement in BCVA of 6/18 or more. Only 1 patient had BCVA of 6/60. This improvement in BCVA was maintained at 1-month and 3 month follow-up.

Chang and Lee did a case series of 18 cases of uncomplicated sutured SFIOL [9]. Their study showed a final visual outcome of 6/12 or better in 78% of patients at 3-month follow-up. A prospective study of 45 patients over 5 years from October 1995 to November 2000 was done by Mazhry and Kadri. The most common complication was glaucoma seen in 8 (18%) cases followed by vitreous hemorrhage seen in 4 (9%) cases and hyphema seen in 2 (4%) patients. Sivakumar Charan did a retrospective study of 100 nonsutured secondary SFIOL implantation.

Most common immediate postoperative complication was anterior chamber reaction seen in 19% of cases. 8% of cases developed corneal edema. 1 case developed choroidal detachment, 2% of cases had

hyphema, and vitreous hemorrhage was seen in 2% cases. McCluskey and Harrisberg did a case series study of 12 cases of uncomplicated secondary suturing of scleral fixation IOL [10]. Their study showed a visual outcome of 6/12 or better in 7 (58%) and of 6/60 or worse in 2 (17%).

Most common postoperative complication observed was corneal edema seen in all 36 (100%) patients on day 1. This was followed by anterior chamber reaction seen in 25 (70%) patients. These complications were managed conservatively with topical steroids and complete resolution was seen at 1-month follow-up. Most of the suture-related complications as well as some other delayed complications such as glaucoma and retinal detachment found in similar studies were observed at 6-month or 1-year follow-up. None of these complications could be assessed as our study had a follow-up period of 3 months.

CONCLUSION

In this hospital-based prospective study conducted at tertiary care hospital in western Maharashtra, we studied visual outcome and complications associated with scleral-fixated intraocular lens. Hence, from this study, we can conclude that:

- Combined anterior vitrectomy and scleral-fixated sutured PC IOL implantation is an effective and safe procedure to correct aphakia in eyes without adequate capsular support. It provides excellent visual outcome with less postoperative complications.
- It is a superior alternative to ACIOLs and iris-fixated IOLs as it decreases the complications such as bullous keratopathy, iritis, and CME.
- Thorough preoperative examination, meticulous surgical technique and treatment of complications following surgery are essential to get the best possible outcome.
- Longer follow-up period is required to assess the long-term postoperative complications such as suture erosion, pseudophakic bullous keratopathy, glaucoma, and retinal detachment.

Limitations

Mean follow-up period of patients in this study was 3 months and some delayed complications such as suture erosion, glaucoma, and retinal detachment could not be assessed in this study.

REFERENCES

1. Apple DJ, Mamalis N, Loftfield K, Googe JM, Novak LC, Kavka-Van Norman D, *et al.* Complications of intraocular lenses. A historical and histopathological review. *Surv Ophthalmol.* 1984;29(1):1-54. doi: 10.1016/0039-6257(84)90113-9, PMID: 6390763
2. Chang JH, Lee JH. Long-term results of implantation of posterior chamber intraocular lens by suture fixation. *Korean J Ophthalmol.* 1991;5(1):42-6. doi: 10.3341/kjo.1991.5.1.42, PMID: 1942602
3. Holladay JT. Evaluating the intraocular lens optic. *Surv Ophthalmol.* 1986;30(6):385-90. doi: 10.1016/0039-6257(86)90092-5, PMID: 3726748
4. Lee VY, Yuen HK, Kwok AK. Comparison of outcomes of primary and secondary implantation of scleral fixated posterior chamber intraocular lens. *Br J Ophthalmol.* 2003 Dec;87(12):1459-62. doi: 10.1136/bjo.87.12.1459, PMID: 14660452
5. Lewis JS. Abexternosulcus fixation. *Ophthalmic Surg.* 1991;22(11):692-5. doi: 10.3928/1542-8877-19911101-14, PMID: 1792035
6. McCluskey P, Harrisberg B. Long-term results using scleral-fixated posterior chamber intraocular lenses. *J Cataract Refract Surg.* 1994;20(1):34-9. doi: 10.1016/s0886-3350(13)80040-5, PMID: 8133477
7. Miyake K, Asakura M, Kobayashi H. Effect of intraocular lens fixation on the blood-aqueous barrier. *Am J Ophthalmol.* 1984;98(4):451-5. doi: 10.1016/0002-9394(84)90130-2, PMID: 6486218
8. Stark WJ, Gottsch JD, Goodman DF, Goodman GL, Prutzer K. Posterior chamber intraocular lens implantation in the absence of capsular support. *Arch Ophthalmol.* 1989;107(7):1078-83. doi: 10.1001/archophth.1989.01070020140048, PMID: 2665697
9. Steinert RF. *Surgical Alternatives in Monocular Aphakia. Focal Ppoints 1990. Clinical Modules for Ophthalmologists. Vol. 8. United States: American Academy of Ophthalmology; 1990. p. 1.*
10. Waring GO 3rd. The 50-year epidemic of pseudophakic corneal edema. *Arch Ophthalmol.* 1989;107(5):657-9. doi: 10.1001/archophth.1989.01070010675025, PMID: 2719576