

**TO EVALUATE HEPATOPROTECTIVE ACTIVITY OF LEAVES OF *OCIMUM SANCTUM* USING ANIMAL MODEL**

ANURAG JAIN\*

Department of Pharmacology and Therapeutics, Sarojini Naidu Medical College, Agra, India. Email: dranurag2008@rediffmail.com

Received: 02 May 2015, Revised and Accepted: 18 May 2015

**ABSTRACT**

**Objective:** To evaluate the hepatoprotective activity of leaves of *Ocimum sanctum* in carbon tetrachloride (CCl<sub>4</sub>) induced hepatotoxicity in albino rabbits.

**Methods:** This study was conducted on 12 healthy albino rabbits of either sex weighing 1.5-2.0 kg, divided into 2 groups. Hepatotoxicity was induced in rabbits by CCl<sub>4</sub> 0.05 mg/kg, intra-peritoneally. Alcoholic extracts of leaves of *O. sanctum* was administered orally for 20 days from 1 day to day 20 in the doses of 100 mg/kg/day with the help of a syringe.

**Results:** Group I: The rise of serum transaminase (p<0.001), serum alkaline phosphatase (p<0.001), serum bilirubin (p<0.001) and decrease in serum albumin (p<0.001) due to hepatotoxic effect of CCl<sub>4</sub> when compared to zero-day of same group (p<0.001). Group II: *O. sanctum* extract was able to bring down the level of serum transaminase, serum alkaline phosphatase, serum bilirubin and increased in serum albumin in a statistical highly significant amount (p<0.001), when compared with Group I.

**Conclusion:** *O. sanctum* leaves found to be effective in reducing serum glutamic oxalacetic transaminase, serum glutamic pyruvic transaminase alkaline phosphatase, serum bilirubin. *O. sanctum* extract helps in normalize serum albumin level. *O. sanctum* extract had shown protection in the restoration of liver function and regeneration of liver cells as observed on histopathology.

**Keywords:** Hepatoprotective activity, *Ocimum sanctum*, Transaminases, Liver injury

**INTRODUCTION**

The liver is the largest internal organ in the body contributing about 2% of total body weight [1], which plays an essential role in the metabolism of foreign substances entering the body. They are known as xenobiotics. The liver has considerable reserve capacity, can often maintain function in spite of significant disease and is one of the few human organs capable of regeneration [1].

More than 1000 xenobiotics substances are potentially hepatotoxic [2]. The ability of the chemical to produce liver damage *in vivo* often results from the interaction of a series of the complex process involved in the uptake, biotransformation and elimination of these potentially toxic compounds.

Conventional drugs used in the treatment of liver disease are often inadequate. It is, therefore, necessary to search for alternative drugs for the treatment of liver diseases to supplement the currently used drugs of limited efficacy and safety.

Hence, this study is designed to evaluate the hepatoprotective effect of *Ocimum sanctum* in carbon tetrachloride (CCl<sub>4</sub>) induced hepatotoxicity in experimental animals, supported by histopathological evidence.

**METHODS**

This study was conducted in the Department of Pharmacology and Therapeutics in collaboration with Department of Pathology, Ganesh Shankar Vidyarthi Memorial Medical College (GSVM), Kanpur, after the clearance from Institutional Animal Ethical Committee for Prevention of cruelty and supervision of experiments on animals.

**Animals**

The study was conducted on 12 healthy albino rabbits of either sex weighing 1.5-2.0 kg, divided into 2 groups. The animals were made

available in the animal house of Department of Pharmacology and Therapeutics.

Rabbits also have metabolism similar to human beings. Hepatotoxicity induced in rabbit by CCl<sub>4</sub> simulate the symptoms of drug-induced hepatitis in human being without the development of concurrent infections. Hence, experiment on rabbits correlate well with human subjects.

All the animals were fed normal stock diet for 7 days. During this time, the animals got acclimatized to the new environment. All the animals were housed individually in a clean cage and maintained under standard conditions (12 hrs light and dark cycle, at room temperature 25±3°C and 35-60% humidity).

**Drugs used**

Alcoholic extracts of leaves of *O. sanctum*. This extract was administered orally for 20 days from 1 day to day 20 with the help of a syringe. CCl<sub>4</sub> was administered intraperitoneally for 10 days.

**Preparation of extract**

Leaves of *O. sanctum* were obtained from Herbal garden of GSVM Medical College, Kanpur. Leaves of *O. sanctum* were dried in the shade then turn into coarse powder. About 500 g of coarse powder of each was thus obtained, which was then subjected to cold percolation method for 7 days using 70% alcohol as a solvent. After 7 days, extract of each drug was collected. The alcohol-free extract was weighed and preserved in a refrigerator at 4°C.

CCl<sub>4</sub> was obtained from the market. Since CCl<sub>4</sub> is a hepatotoxic agent, it induces hepatitis in the animals. Hepatitis produces anorexia and decreases in the body weight; therefore, assessment of weight loss was done in all the groups.

1. 60 g of diet was given to each rabbit. Diet was provided between 11 am and 1.00 pm daily. Weighed diet was given and the amount

consumed was calculated from the difference between the left over amount of diet 24 hrs later. Water was given ad libitum.

- The weight of the animals: Weight was recorded daily from 1<sup>st</sup> day to 20<sup>th</sup> day. Any increase or decrease in the weight of rabbit during drug administration was recorded.
- Serum glutamic oxalacetic transaminase (SGOT), serum glutamic pyruvic transaminase (SGPT), Alkaline phosphatase, serum bilirubin, serum albumin estimation was done, blood samples were collected on zero day, 11<sup>th</sup> day, 21<sup>st</sup> day.
- Liver weight: At the end of the study rabbit were sacrificed and liver was taken out. It was weighed and preserved in 10% buffered formalin for histopathological study.

#### Procedure

Rabbits were divided into 2 groups with 6 rabbits in each group.

Group I: Animals of this group were treated with hepatotoxic agent i.e., carbon tetrachloride (CCl<sub>4</sub>) for 10 days in the dose of 0.05 ml/kg/day intra-peritoneally from 1<sup>st</sup> day to day 10 along with normal feed. On 11<sup>th</sup> day, blood samples were collected, and rabbits were sacrificed.

Group II: Animals of this group were given extract of leaves of *O. sanctum* 100 mg/kg/day orally for 20 days along with normal feed, from 11<sup>th</sup> day onward CCl<sub>4</sub> 0.05 mg/kg, i.p. was also given followed by herbal drug

Blood samples were collected on 0 day before giving any drug to see the control value of liver function tests (LFT), on 11<sup>th</sup> day to see the per se effect of herbal drug on LFT and on 21<sup>th</sup> day to see the protective effect of herbal drug on LFT. The value obtained were compared. Blood samples were drawn from the marginal vein of pinna using 22 gauge needle, after the ear hairs were shaved off. 3 ml blood was collected in the vial, for the liver function test.

Body weight was measured daily. The animals of Group I was sacrificed on 11<sup>th</sup> day, and the animals of Group II were sacrificed on 21<sup>th</sup> day. They were made unconscious, by giving ketamine. The abdomen was exposed, and liver was excised, weighed and was preserved in 10% buffered formalin for histopathological study.

#### Assessment of liver injury

Assessment of liver injury was done by biochemical estimation and histopathological study of liver under a light microscope.

#### Biochemical estimation

Serum bilirubin, SGOT, SGPT, Alkaline phosphatase, serum albumin levels were estimated by Olympus autoanalyser in the Department of Pathology.

#### Histopathology

Histopathological study of the rabbit's liver was done to assess the extent of toxicity. Liver was taken out after sacrificing the rabbit. It was weighed and preserved in 10% buffered formalin. Tissue sectioned to prepare slides. Staining was done with hematoxylin and eosin. Then slides were examined under a light microscope, and these slides were photographed [3].

#### Statistical calculations

Mean, standard deviation and standard error of the mean was calculated, and results were analyzed by using paired t test and Student t-test. p<0.05 were considered significant.

#### OBSERVATIONS AND RESULTS

Effect on diet intake, body weight, liver weight (Table 1). In rabbits of Group I, who were administered CCl<sub>4</sub> (0.05 mg/kg/day, intraperitoneally) along with normal feed, the diet intake was found to be 39.13±0.77 g/day. The decrease in food intake has led to a decrease in body weight. The mean decrease in body weight in Group I was considerably more than when compared to the Group II. The mean weight of liver was 28.38±0.18 g.

In rabbits of Group II (received *O. sanctum* extract) the average diet intake was decreased by 21.7% when compared to average diet intake during first 10 days of same group and increased by 13.3% when compared with Group I.

The mean weight of the liver was measured to be 35.16±0.22. This suggests that *O. sanctum* extract was able to arrest the decrease in weight of liver when compared to CCl<sub>4</sub> administered group.

In Group I, there was a highly significant (p<0.001) increase in the levels of serum transaminases, serum alkaline phosphatase, serum Bilirubin and significant decrease in serum albumin with p<0.001 compared to zero-day of same group (self-control).

In Group II, administration of *O. sanctum* extract to rabbits Group II feed on normal diet did not alter the level of serum transaminase (p>0.10), serum alkaline phosphatase (p>0.10), serum bilirubin and serum albumin (p>0.10), when 11<sup>th</sup> day rabbits compared to zero-day of same group.

In Group II, the rise of serum transaminase (p<0.001, Tables 2 and 3). Serum alkaline phosphatase (p<0.001, Table 4), serum bilirubin (p<0.01, Table 5) and decrease in serum albumin (p<0.001, Table 6) due to hepatotoxic effect of CCl<sub>4</sub> when compared to 0 day of same group.

*O. sanctum* extract was able to bring down the level of serum transaminase (Tables 2 and 3), serum alkaline phosphatase (Table 4), serum bilirubin (Table 5) and increased in serum albumin (Table 6) in a statistical highly significant amount (p<0.001), when compared with 11<sup>th</sup> day of rabbits receiving CCl<sub>4</sub> alone.

#### Histopathological assessment

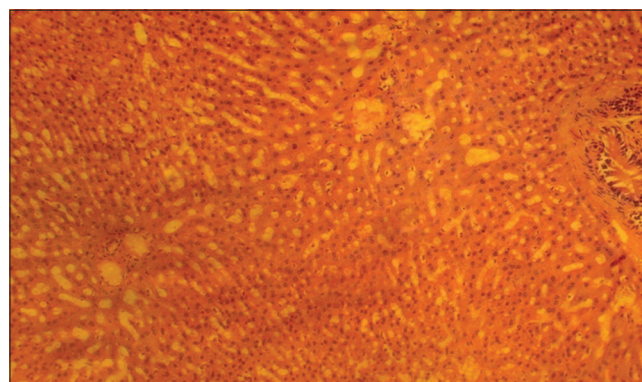
##### Rabbits administered carbon tetrachloride

Grade III fatty changes and hydropic degeneration was present in 75% of rabbits and Grade II fatty changes were present in 25% of rabbits. Centrilobular (perivenular) and periportal inflammation was found in 75% and 25% of rabbits respectively, chiefly infiltrated with monocytes. Grade II inflammation was present in all rabbits. Grade II necrosis and loss of cord pattern were found in all rabbits (Fig. 1).

##### Rabbits administered *O. sanctum* extract and CCl<sub>4</sub>

When rabbits on CCl<sub>4</sub> were compared with Group II rabbits receiving *O. sanctum* extract and CCl<sub>4</sub>, there was the protection of hepatic lobules from the damage induced by CCl<sub>4</sub>. Grade II fatty changes were present in 70% of rabbits. No Portal inflammation and no necrosis were found. Cord pattern was maintained (Fig. 2).

The result in this study suggests that administration of *O. sanctum* extract to the rabbits received CCl<sub>4</sub> from 11<sup>th</sup> day to 20<sup>th</sup> day caused



**Fig. 1: A section of rabbit liver treated with carbon tetra chloride alone showing marked fatty changes and Grade II inflammatory changes in 100% area and loss of cord pattern**

**Table 1: Average diet intake per day, mean liver weight (g) of rabbits, mean body weight (kg) of different groups**

Group	Average diet Intake (g/kg) 1 <sup>st</sup> to 10 <sup>th</sup> day	Average diet intake (g/kg) 11 <sup>th</sup> to 20 <sup>th</sup> day	Mean liver weight (g)	Average body weight (in kg) 1 <sup>st</sup> to 10 <sup>th</sup> day	Average body weight (in kg) 11 <sup>th</sup> to 20 <sup>th</sup> day
I (CCl <sub>4</sub> )	39.13±0.77	- <sup>s</sup>	28.38±0.18	1.04±0.11	- <sup>s</sup>
II ( <i>Ocimum sanctum</i> extract)	60.18±0.47	47.34±0.40	35.16±0.22	1.57±0.37	1.42±0.39

All values are in mean±SE, <sup>s</sup>Group I rabbits were sacrificed on 11<sup>th</sup> day SE: Standard error, CCl<sub>4</sub>: Carbon tetra chloride

**Table 2: Mean aspartate transaminase (AST, SGOT) in IU/L of rabbits in different groups**

Group	Mean SGOT±SE (IU/L) at zero day	Mean SGOT±SE (IU/L) at 11 <sup>th</sup> day	Mean SGOT±SE (IU/L) at 21 <sup>th</sup> day
I (CCl <sub>4</sub> )	30.67±0.88	87.17±1.58*	- <sup>s</sup>
II ( <i>Ocimum sanctum</i> extract)	29.00±1.53	29.67±1.93**	59.00±1.39*#

\*p<0.001, \*\*p>0.10, <sup>s</sup>Group I rabbits were sacrificed on 11<sup>th</sup> day, \*\*\*Values are compared with zero day of same group (self-control), #p<0.001, #compared with 11<sup>th</sup> day of Group I (CCl<sub>4</sub>), SE: Standard error, CCl<sub>4</sub>: Carbon tetra chloride, SGOT: Serum glutamic oxalacetic transaminase, ALP: Alkaline phosphatase

**Table 3: Mean alanine transaminase (ALT, SGPT) in IU/L of rabbits in different groups**

Group	Mean SGPT±SE (IU/L) at zero day	Mean SGPT±SE (IU/L) at 11 <sup>th</sup> day	Mean SGPT±SE (IU/L) at 21 <sup>th</sup> day
I (CCl <sub>4</sub> )	30.33±1.49	132.67±3.77*	- <sup>s</sup>
II ( <i>Ocimum sanctum</i> extract)	30.33±1.05	30.67±0.71**	74.33±1.3*#

\*p<0.001, \*\*p>0.10, <sup>s</sup>Group I rabbits were sacrificed on 11<sup>th</sup> day, \*\*\* values are compared with zero day of same group (self-control), #p<0.001, #compared with 11<sup>th</sup> day of Group I (CCl<sub>4</sub>), SE: Standard error, CCl<sub>4</sub>: Carbon tetra chloride, ALP: Alkaline phosphatase, SGPT: serum glutamic pyruvic transaminase

**Table 4: Mean ALP in IU/L of rabbits in different groups**

Group	Mean ALP±SE (IU/L) at zero day	Mean ALP±SE (IU/L) at 11 <sup>th</sup> day	Mean ALP±SE (IU/L) at 21 <sup>th</sup> day
I (CCl <sub>4</sub> )	36.50±2.53	121.83±3.07*	- <sup>s</sup>
II ( <i>Ocimum sanctum</i> extract)	37.00±2.34	36.83±1.89**	61.50±1.61*#

\*p<0.001, \*\*p>0.10 <sup>s</sup>Group I rabbits were sacrificed on 11<sup>th</sup> day, \*\*\*values are compared with zero day of same group (self-control), #p<0.001, #compared with 11<sup>th</sup> day of Group I (CCl<sub>4</sub>), SE: Standard error, CCl<sub>4</sub>: Carbon tetra chloride, ALP: Alkaline phosphatase

a decline in hepatotoxicity induced by CCl<sub>4</sub>. This is evidenced in the marked decrease in serum SGPT and SGOT level relative to the group treated with CCl<sub>4</sub> alone. *O. sanctum* extract appears to exhibit protection against liver injury.

## DISCUSSION

Today, most xenobiotics to which humans are exposed come from sources that include environmental pollution, food additives, cosmetics products, agro-chemicals, processed food and drugs. In general, these chemicals in the absence of metabolism would not be eliminated from the body efficiently, and thus would accumulate in the body resulting in toxicity. Hepatic injury is a common sequel of exposure to toxic agents.

The CCl<sub>4</sub> is one of the most commonly used hepatotoxins in the experimental study of liver diseases [4]. Plant derived natural

**Table 5: Mean serum bilirubin (mg/dl) of rabbits in different groups**

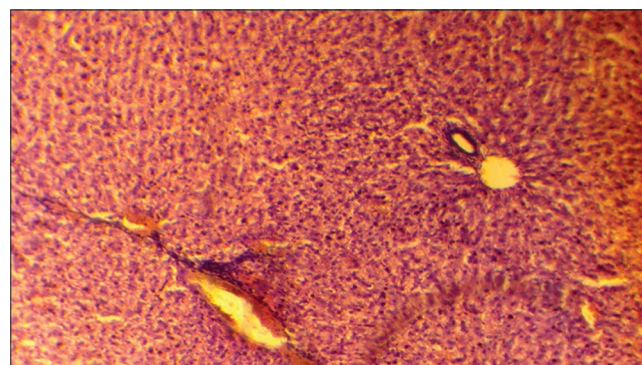
Group	Mean serum bilirubin (mg/dl) ±SE at zero day	Mean serum bilirubin (mg/dl) ±SE at 11 <sup>th</sup> day	Mean serum bilirubin (mg/dl) ±SE at 21 <sup>th</sup> day
I (CCl <sub>4</sub> )	0.33±0.04	1.07±0.07*	- <sup>s</sup>
II ( <i>Ocimum sanctum</i> extract)	0.38±0.03	0.35±0.02**	0.62±0.03***#

\*p<0.001, \*\*p>0.10, \*\*\*p<0.01, <sup>s</sup>Group I rabbits were sacrificed on 11<sup>th</sup> day, \*\*\*\* values are compared with zero day of same group (self-control), #p<0.001, #compared with 11<sup>th</sup> day of Group I (CCl<sub>4</sub>), SE: Standard error, CCl<sub>4</sub>: Carbon tetra chloride

**Table 6: Mean serum albumin (g/dl) of rabbits in different groups**

Group	Mean serum albumin (g/dl) ±SE at zero day	Mean serum albumin (g/dl) ±SE at 11 <sup>th</sup> day	Mean serum albumin (g/dl) ±SE At 21 <sup>th</sup> day
I (CCl <sub>4</sub> )	4.00±0.10	2.33±0.07*	- <sup>s</sup>
II ( <i>Ocimum sanctum</i> extract)	4.20±0.14	4.42±0.05**	3.63±0.23***#

\*p<0.001, \*\*p>0.10, \*\*\*p<0.01, <sup>s</sup>Group I rabbits were sacrificed on 11<sup>th</sup> day, \*\*\*\*Values are compared with zero day of same group (self control), #p<0.001, #compared with 11<sup>th</sup> day of Group I (CCl<sub>4</sub>), SE: Standard error, CCl<sub>4</sub>: Carbon tetra chloride



**Fig. 2: A section of rabbit liver treated with *Ocimum sanctum* extract and carbon tetra chloride (CCl<sub>4</sub>) showing some protection from damage induced by CCl<sub>4</sub> (Grade II fatty changes in 100% area)**

products such as flavonoids, terpenoids, and steroids, etc. have received considerable attention in recent years due to their diverse pharmacological properties, including hepatoprotective and antioxidant activity [5,6]. Realizing the fact this study was carried out to evaluate the hepatoprotective of *O. sanctum* extract in this direction.

Our findings regarding weight of liver, however, are different from earlier reports. Simmon's *et al.*, 1995 in their study have reported that increased organ weight (whether absolute or relative) is a sensitive indicator of organ toxicity [7]. Also, Sodhi *et al.* in their study have



reported an increase in the specific liver weight in experimental animals given protein restricted diet administered INH+R (causing hepatotoxicity) [8].

In this study, CCl<sub>4</sub> was able to produce hepatic damage which is manifested by an increase in serological marker and abnormal histopathology. These changes are similar to previous studies.

The serum level of marker enzymes: SGOT, SGPT, and ALP reflect the physiological state of the liver. The levels of these enzymes change accordingly to the distortion of the liver resulting from cellular injury of the organ caused by toxic metabolites and diseases. Serum and plasma enzymes levels have been used as a marker for monitoring chemically induced tissue damages [9,10].

The toxicity of CCl<sub>4</sub> to the liver of mammal is largely as a result of the active metabolite, trichloromethyl radical [11]. The above radical bind to tissue macro - molecule and thus induce peroxidative degradation of membrane lipids of endoplasmic reticulum, which are rich in polyunsaturated fatty acids. Shenoy *et al.* 2001 [12], postulated, that such development would ultimately lead to the formation of lipid peroxides. The increase enzyme level in the plasma of CCl<sub>4</sub> - treated rabbits, suggests that the toxicant was able to reach the liver and induce a detectable damage.

The increase in levels of serum bilirubin reflects the depth of jaundice and increase in transaminases and alkaline phosphatase indicates the cellular leakage and loss of functional integrity of cell membrane [13]. Liver enzymes are usually raised in acute hepatotoxicity but tend to decrease with prolonged intoxication due to damage to liver cells [14].

*O. sanctum* was found to protect the rats from the hepatotoxic action of paracetamol as evidenced by a significant reduction in the elevated serum enzyme levels. It is stipulated that the extract treated group was partially protected from hepatic cell damage caused by paracetamol [15].

Rabbits treated with *O. sanctum* extract have shown significant reduction of SGOT, SGPT, alkaline phosphatase and serum bilirubin and histopathology provide direct evidence of functional protection of hepatocyte. Various pathological changes such as steatosis, centrilobular necrosis, loss of cord pattern observed in Group I rabbits, were prevented in Group II.

## CONCLUSION

From the discussion, it is clear that the carbon tetrachloride administration produces hepatic injury as is evident both by the changes in the biochemical parameters and histopathological changes in the present study. There is evidence of varying degree of oxidative stress leading to hepatocellular damage. We observed that *O. sanctum* leaves extract protect the liver against CCl<sub>4</sub> induced hepatotoxicity.

*O. sanctum* extract found to be effective in reducing SGOT, SGPT, ALP, serum bilirubin and cause increase in serum albumin level. *O. sanctum* extract has shown protection in the restoration of liver function and regeneration of liver cells as observed on histopathology.

This study was done on a small scale and for short duration so further research needs to be done to confirm the above results and to find the active principle and mechanism of action responsible for their hepatoprotective activity.

## ACKNOWLEDGMENT

The author sincerely thanks to Department of Pharmacology and Pathology, GSVM Medical College, Kanpur for providing the necessary facilities for carrying out this work.

I am highly thankful to Dr. I.P. Jain (Professor & Head), Dr. S.P. Singh (Professor), Department of Pharmacology & Therapeutics, GSVM Medical College, Kanpur and Dr. Asha Agrawal (Professor) Department of Pathology, GSVM Medical College, Kanpur, whose wealth of knowledge and vast experience has been instrumental at all stages of this study.

## REFERENCES

1. Ward FM, Daly MJ. Liver disease. In: Clinical Pharmacy and Therapeutics. 3<sup>rd</sup> ed. London: Elsevier Science Limited; 2003. p. 209.
2. Guillouzo A. Liver cell models in *in vitro* toxicology. Environ Health Perspect 1998;106 Suppl 2:511-32.
3. Willianson EM, Okpako DT, Evans FJ. Selection, preparation and pharmacological evaluation of plant material. England: John Wiley; 1996.
4. Johnston DE, Kroening C. Mechanism of early carbon tetrachloride toxicity in cultured rat hepatocytes. Pharmacol Toxicol 1998;83(6):231-9.
5. DeFeudis FV, Papadopoulos V, Drieu K. *Ginkgo biloba* extracts and cancer: A research area in its infancy. Fundam Clin Pharmacol 2003;17(4):405-17.
6. Takeoka GR, Dao LT. Antioxidant constituent of almond. J Agric Food Chem 2003;51:496-501.
7. Raghavendran BR, Sathivel A, Devaki T. Hepatoprotective nature of seaweed alcoholic extract on acetaminophen induced oxidative stress. J Health Sci 2003;50(1):42-6.
8. Anandan R, Deepa Rekha R, Devaki T. Protective effect of *Picrorrhiza kurroa* on mitochondrial glutathione antioxidant system in D- galactosamine- induced hepatitis in rats. Curr Sci 1999;76:1543-5.
9. Lin JK, Wang CJ. Protection of crocin dyes on the acute hepatic damage induced by aflatoxin B1 and dimethylnitrosamine in rats. Carcinogenesis 1986;7(4):595-9.
10. Ngaha EO, Akanji MA, Madusolumuo MA. Studies on correlations between chloroquine-induced tissue damage and serum enzyme changes in the rat. Experientia 1989;45(2):143-6.
11. Johnson DE, Kroening C. Ethanol feeding stimulates trichloromethyl radical formation from CCl<sub>4</sub> in cultured rat hepatocytes. Pharmacol Toxicol 1998;83:231-9.
12. Shenoy KA, Somayaji SN, Bairy KL. Hepatoprotective effects of *Ginkgo biloba* against CCl<sub>4</sub> induced hepatic injury in rats. Indian J Pharmacol 2001;33:260-6.
13. Saraswat B, Visen PK, Patnaik GK, Dhawan BN. Anticholestatic effect of picroliv, active hepatoprotective principle of *Picrorrhiza kurroa*, against carbon tetrachloride induced cholestasis. Indian J Exp Biol 1993;31(4):316-8.
14. Cornelius CE. Biochemical evaluation of hepatic function in dogs. J Am Hosp Assoc 1979;15:25-9.
15. Chattopadhyay RR, Sarkar SK, Ganguly S, Medda C, Basu TK. Hepatoprotective activity of *O. sanctum* leaf extract against paracetamol induced hepatic damage in rats. Indian J Pharmacol 1992;24(3):163-5.