

## BONE GRAFT SUBSTITUTES WITH BONE CURETTAGE FOR THE TREATMENT OF FIBROUS DYSPLASIA OF RIGHT TIBIA

MAZHARUDDIN ALI KHAN, MCH, V.R.SUJIT KUMAR

<sup>1</sup>Professor and Head, Dept of Orthopedics, Deccan College of Medical Sciences, Hyderabad, India, <sup>2</sup>MBBS, 2<sup>nd</sup> year Post graduate student (MS Ortho), Deccan College of Medical Sciences, Hyderabad, India. Email: drmazharuddinalikhan@yahoo.com; ms@owaisihospital.com

Received: 20 May 2013, Revised and Accepted: 19 June 2013

### ABSTRACT

Fibrous dysplasia (FD) is a benign condition, with an ability to affect any bone in the body and has a wide spectrum of severity. It is a chronic condition of the skeleton where a portion of a bone develops abnormally. We report and discuss a case of six year old male patient suffering from fibrous dysplasia of right tibia, its diagnosis, and management including surgical intervention. Bone graft substitute with bone curettage was performed after thorough excision of bone tumour and bone wash. Procedure was carried out under general anaesthesia and C-arm guidance. Significant improvement was seen clinically and patient walked eight weeks after surgery. He was able to carry out routine activities normally with a significant improvement in quality of life. This was the latest surgical procedure available for the treatment of FD.

**Keywords:** Bone curettage, bone graft substitute with bone curettage, Fibrous dysplasia, quality of life

### INTRODUCTION

Fibrous dysplasia (FD) is a rare clinical condition in which bone tissue is replaced by fibro-osseous lesions. These skeletal lesions representing about 5% of all benign bone tumors may involve one bone (monostotic) or multiple bones (polyostotic). The lesions can occur throughout the skeleton but tend to occur in long bones, ribs and craniofacial bones; they represent 5-7% of all benign bone tumours. [1] Symptoms usually appear between 5 and 20 years of age with an earlier onset is seen in more extended cases of dysplasia. [2] Exact pathogenic mechanism of fibrous dysplasia is unknown but recent studies indicate that genetic factors may be responsible, and the disease is linked to a postzygotic mutation in guanine nucleotide stimulatory protein (GNAS1) located on chromosome 20q13.2-13.3. [3]

Birth marks (cafe-au-lait spots) often can be the first presenting sign of FD and may be associated with other endocrinal disturbance such as precocious puberty, hyperthyroidism, hypophosphatemia, excess growth hormone. When a patient presents with birth marks or combination of symptoms, it is known as McCune-Albright syndrome.

Symptomatic treatment is the option in FD as there is no cure. Though medications such as bisphosphonates have been shown to be highly efficacious in relieving pain, surgery is still the mainstay of treatment for FD affecting long bones.

Many studies have been conducted and data is available on FD in developed countries, but limited data is available from developing countries including India, where only anecdotal cases are reported.

### CASE REPORT

A six year old boy presented to our hospital, a tertiary care centre, with pain and swelling over right leg, associated with difficulty in walking, since one year. There was anterior bowing in the middle of the right leg. On admission, routine haematological and biochemical investigations including serum levels of calcium, phosphate, alkaline phosphate and ESR, serial X-rays – anteroposterior (AP) and lateral (LAT) view of right leg (fig 1a,b), tech 99m bone scan (fig 2a,b) and magnetic resonance imaging (MRI) scanning of right tibia were performed. Haemotological and biochemical results were within normal limits.

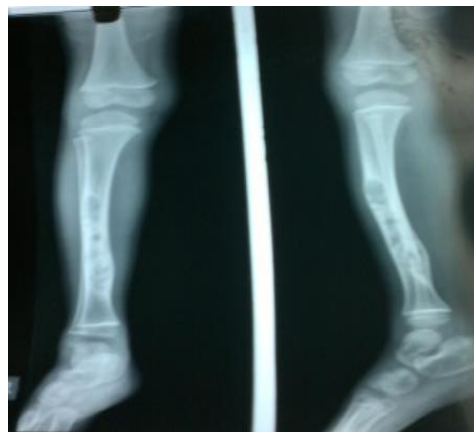

Fig1a: X-ray right tibia anteroposterior and lateral view at initial stage of the disease

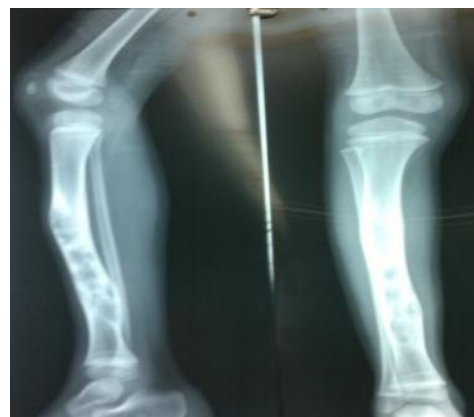

Fig1b: X-ray of right tibia anteroposterior and lateral view at later stage of the disease

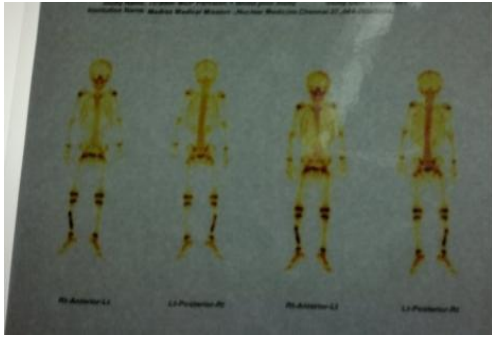


Fig2a

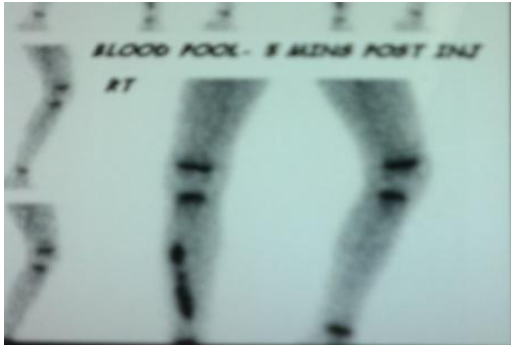


Fig2b

**Fig2a,b. Tech 99 m bone scan showing lesion in the right tibia**

Patient's age, clinical history, and results of investigations indicated a probable diagnosis of fibrous dysplasia of right tibia.

C-arm guidance and tourniquet control surgery was performed under general anaesthesia (GA) i.e bone graft substitute with bone curettage after thorough excision of bone tumour and bone wash followed by bone biopsy.

*Procedure*

Longitudinal incision was given on the antero-lateral aspect of middle third right leg under GA; affected bone was identified after separating the tissues under c-arm guidance. Major lesions were located and identified, bone was drilled and three holes were made on the middle third of right tibia. Bone graft substitute with bone curettage was done after a thorough wash. Wound was closed after confirming by C-arm. (fig3a,b,c,d,e,f,g)

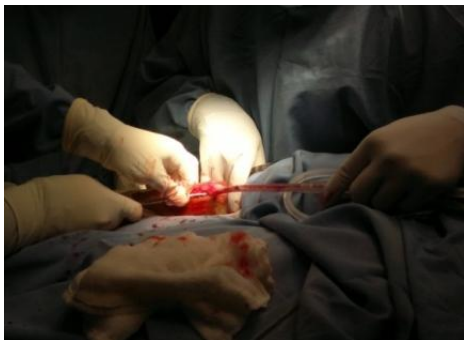


Fig3a The incision has been given to right leg

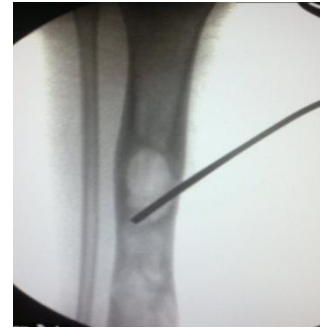

Fig3b C-arm picture identifying the major lesion

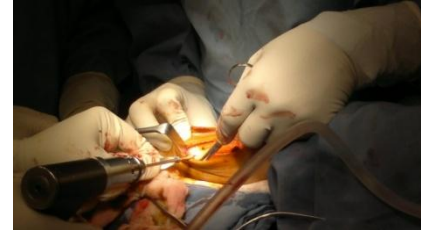

Fig3c

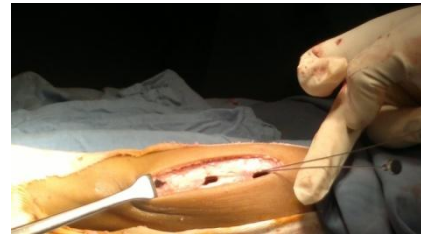

Fig3d

Fig3c,d Drilling and removal of bone at the site of the lesion

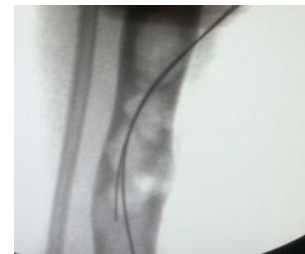

Fig3e C-arm picture showing a guide wire passed all through the bone

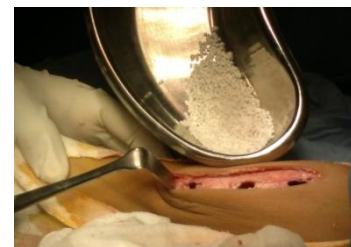
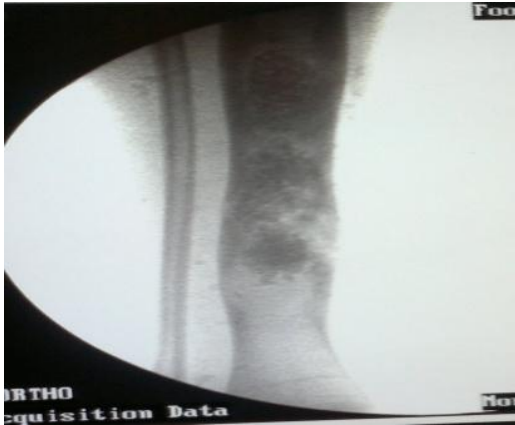
Fig 3f shows artificial bone graft to be positioned in the bone marrow of right tibia after thorough bone marrow wash.

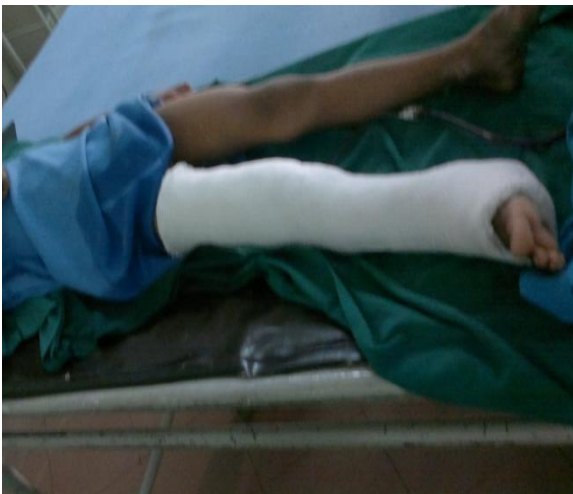

**Fig 3g C- arm picture with artificial bone graft in the right tibia**

#### Follow-up

Patient was covered with appropriate antibiotic pre and post operatively and post operative period was uneventful without any complications. Intravenous antibiotic administration was continued for five days and regular wound dressing was done. Patient was discharged from hospital after five days of surgery with an advice to continue oral antibiotics, bisphosphonate, calcium supplements and multivitamins for further one week. Patient was advised regular wound dressing till sutures were removed i.e till 13<sup>th</sup> post operative day. Regular follow up was done once in two weeks.

Plaster of Paris (POP) cast was applied on the affected leg for four weeks (fig 4) and Scotch cast was applied, for another two weeks, after removal of POP. Patient was advised not to bear weight on the right leg.



**Fig 4.POP cast above knee for right tibia**

Weight bearing exercises were taught by trained physiotherapist for two weeks, commencing from six weeks post-surgery.

Patient started walking eight weeks after surgery and was able to carry out routine activities normally.

#### DISCUSSION

FD is characterised by osteolysis in the cortex, peripheral sclerosis, dilation and thinning of the cortex surface, and narrowing of the marrow cavity. [4] It may lead to bowing deformity and pathological fracture (especially in the tibia) and may recur after surgical curettage, with or without bone grafting. [5,6] Successful treatment using vascularised bone grafts or bone transport has been reported. [5,7-9] Early en bloc resection and reconstruction is recommended, because local recurrence is common after curettage. [5] Radical resection with reconstruction prolongs postoperative rehabilitation. [7,8] Natural history of osteofibrous dysplasia involves gradual

development during the first decade of life, followed by spontaneous resolution. [10] Data on long term effects of the disease is not available in the literature and hence it is important to have long term follow up to observe and manage complications.

FD is seen in childhood and early adolescence, and our patient's age was within this age group. Usually it is asymptomatic, posing difficulty in diagnosis, but majority of cases present with bone pain, deformity and fractures, and our patient presented with bone pain, swelling and deformity. Though endocrinopathes are also associated with FD, our patient did not have any such feature. FD is usually diagnosed on the basis of characteristic radiological findings on X-ray, bone scans, and in this patient, a probable diagnosis of FD was made based on radiological findings.

Surgical intervention, which aims at symptomatic relief, is indicated in patients with disease that cannot be managed by conservative treatment, and who have an impending fracture or progressive deformity. We planned surgical treatment for this patient to achieve symptomatic relief and to improve quality of life. The surgery performed was the latest available surgical treatment in 2012.

Currently various surgical modalities are available for treatment of FD i.e minimal invasive plate fixation or intramedullary nailing, bone graft substitute with bone curettage; autograft is not advisable as it will be resorbed. Postoperatively bisphosphonates can be administered to the patient. Early surgical intervention prevents pathological fractures in these patients but requires customized plating; interference with wound healing is another issue which needs to be addressed. Though surgical treatment is available, but availability of experienced orthopedic surgeon that too in few selective centres, cost involved are major challenges faced by developing countries like India.

#### CONCLUSION

This technique is a useful tool in restoring the functions without compromising quality of life. Moreover, there was no surgery related complications. However, availability of an orthopedic surgeon with hands on experience in this technique is a challenge to be addressed.

#### Competing interest

The author(s) declare that they have no competing interests.

#### ACKNOWLEDGEMENT

We acknowledge the support of Dr M S Latha in the preparation of this manuscript.

#### REFERENCES

1. DiCaprio MR, Enneking WF. Fibrous dysplasia. Pathophysiology, evaluation, and treatment. *J Bone Joint Surg* 2005;87-A:1848-1864.
2. Campanacci M, Bertoni F, Bacchini P. Bone and Soft Tissue Tumors. Notini S, translator. New-York: SpringerVerlag: Translation of Tumori delle ossa e delle parti molli;1990:391-41
3. Weinstein LS, Chen M, Liu J. Gs (alpha) mutations and imprinting defects in human disease. *Ann N Y Acad Sci* 2002; 968:173-19
4. Campanacci M, Laus M. Osteofibrous dysplasia of the tibia and fibula. *J Bone Joint Surg Am* 1981;63:367-7
5. Lee RS, Weitzel S, Eastwood DM, Monsell F, Pringle J, Cannon SR, et al. Osteofibrous dysplasia of the tibia. Is there a need for a radical surgical approach? *J Bone Joint Surg Br* 2006;88:658-64.
6. Ozaki T, Hamada M, Sugihara S, Kunisada T, Mitani S, Inoue H. Treatment outcome of osteofibrous dysplasia. *J Pediatr Orthop B* 1998;7:199-202.
7. Karita M, Tsuchiya H, Sakurakichi K, Tomita K. Osteofibrous dysplasia treated with distraction osteogenesis: a report of two cases. *J Orthop Sci* 2004;9:516-20.
8. Tsuchiya H, Tomita K. Distraction osteogenesis for treatment of bone loss in the lower extremity. *J Orthop Sci* 2003;8:116-24.

9. Millett PJ, Lane JM, Paletta GA Jr. Limb salvage using distraction osteogenesis. *Am J Orthop (Belle Mead NJ)* 2000;29:628-3
10. Semian DW, Willis JB, Bove KE. Congenital fibrous defect of the tibia, mimicking fibrous dysplasia. A case report. *J Bone Joint Surg Am* 1975;57:854-7.