

## HEPATOPROTECTIVE EFFECT OF *GENISTA QUADRIFLORA* MUNBY EXTRACT AGAINST ETHANOL INDUCED TOXICITY

N. BOUBEKRI<sup>1,2\*</sup>, R. BOUKAABACHE<sup>1</sup>, A. AMRANI<sup>1,2</sup>, L. BELFARHI<sup>2</sup>, D. ZAMA<sup>1</sup>, O. BOUMAZA<sup>1</sup>, F. BENAYACHE<sup>1</sup>, S. BENAYACHE<sup>1</sup>

<sup>1</sup>Unité de Recherche Valorisation des Ressources Naturelles, Molécules Bioactives, Analyses Physicochimiques et Biologiques (VARENBIOMOL), Université Constantine 1, Route de Ain., <sup>2</sup>Laboratoire de physiologie animale; département de Biologie; Animale Faculté des Sciences de la Nature et de la Vie, Université Constantine 1 Algérie. Email: boubekrinassima@yahoo.fr

Received: 21 January 2014, Revised and Accepted: 7 February 2014

### ABSTRACT

**Objective:** Excessive ethanol intake induces severe tissue damage particularly in the liver through the generation of reactive oxygen species. This study was designed to examine the effect of *n*-butanol extract of *Genista quadriflora* for its protective potentials against ethanol induced toxicity. **Methods:** The effect of *n*-butanol extract of *Genista quadriflora* at a dose of 200 mg/kg was studied on ethanol induced hepatic damage (40% v/v, 3 g/kg per oral every 12 hours for 3 doses) in *Wistar Albino* rats. Serum transaminases, cholesterol, triglycerides, lipid peroxidation (MDA), reduced glutathione (GSH), glutathione peroxidase (GPx) and catalase were estimated to assess liver damage. A histological study was determined. **Results:** It was found that combined *Genista quadriflora* (200mg/kg) extract and ethanol treatment decreased significantly TBARS level and increased reduced glutathione, glutathione peroxidase, and catalase activities compared to the ethanol group ( $p < 0.01$ ). Treatment with ethanol altered liver architecture, whereas the extract pretreatment could be a protective factor for this organ. **Conclusions:** Results of *in vivo* experiments showed that the *n*-butanol extract of *Genista quadriflora* inhibited lipid peroxidation, protected the experimental animals from hepatic toxicity and maintained the levels of antioxidant enzymes.

**Keywords:** *Genista quadriflora*, ethanol, Antioxidant activities, lipid peroxidation, hepatoprotective effect.

### INTRODUCTION

The liver as a vital organ in the body is primarily responsible for the metabolism of endogenous and exogenous agents. It plays an important role in drug elimination and detoxification [1,2]. Alcoholic liver disease is one of the major causes of morbidity and mortality among alcoholics in the world [3]. Excessive consumption of ethanol is shown to lead to serious health problems. Ethanol molecule is small and soluble in both water and lipids; it permeates all tissues of the body and affects most vital functions of virtually all organs including liver, kidney, brain, heart and pancreas [4]. Several studies have shown that free radical mediated mechanisms are involved in ethanol-induced liver damage. Excessive reactive oxygen species ROS generation has been shown to induce lipid peroxidation, protein oxidation and fault elements of the antioxidant system leading to the eventual loss of the structure and function of cells [5]. Therefore inhibition of free radicals generation is important in providing protection against hepatic damage [4].

Scientific research in herbal medicine with hepatoprotective activity may be a great benefit as an alternative therapy in alcohol induced liver disease [6]. For a long period of time, plants have been a valuable source of natural product for maintaining human health and nowadays, many therapeutic studies are devoted to plants since plants are a natural source of antioxidants and hence reduce oxidative stress [4,7]. Therefore, the present study aims to investigate the hepatoprotective potentials of *n*-butanol extract of *Genista quadriflora* against alcohol induced toxicity.

### MATERIALS AND METHODS

#### Plant material

*Genista quadriflora* Munby (Fabaceae), an endemic species of North Africa (Algeria and Morocco) [8] was collected during the flowering phase in May 2008 from the area of El Kala, in the East of Algeria and authenticated by Dr. D. Sarri (Biology department, University of M'Sila - Algeria). A voucher specimen has been

deposited in the Herbarium of the Department of Nature and Life Science, Constantine 1 University.

#### Extraction

Air-dried aerial parts (1130 g) of *Genista quadriflora* were macerated at room temperature with MeOH-H<sub>2</sub>O (80:20, v/v) for 24h, three times. After filtration, the filtrate was concentrated and dissolved in H<sub>2</sub>O (500 ml) under magnetic agitation. The resulting solution was filtered and successively extracted with petroleum ether, CHCl<sub>3</sub>, EtOAc and *n*-butanol. The organic phases were dried with Na<sub>2</sub>SO<sub>4</sub>, filtered and concentrated in vacuo at room temperature to obtain the following extracts: petroleum ether (0.25g), chloroform (3g), EtOAc (4g) and *n*-butanol (50g).

#### Experimental animals

Female *Wistar Albino* rats weighing (200-250g) were used in the present study. The animals were kept in 12h light/dark cycles and maintained in an air-conditioned room at 22 to 25 °C, with free access to food and water *ad libitum* for two weeks. The general guidelines for the use and care of living animals in scientific investigations were designed according to the ethical standards for animals use and approved by the local ethical committee of animal use and followed [9]. The animals were divided into 4 groups, consisting of 6 animals each. All treatments were administered orally to rats (by gavages).

Group T: Control group (the untreated rats).

Group EtOH: Received 3 g/kg ethanol every 12 hours for 3 doses (ethanol diluted with normal saline 40% v/v) [4].

Group Ext.200: Received extract at the dose 200mg/kg.

Group ETOH-Ext.200: Received 200mg/kg extract and ethanol at the same dose mentioned earlier (the extract was administered half an hour before ethanol treatment).

After treatment, the rats were sacrificed by cervical dislocation and livers were isolated to measure the levels of antioxidant enzymes, MDA and for histopathological studies. The blood is collected through the retro-orbital sinus at the eye of rats for analysis of biochemical parameters. Levels of alanine aminotransferase (ALT), aspartate aminotransferase (AST), total cholesterol and triglycerides were estimated using commercial kits (Spinreact, SPAIN).

#### Estimation of lipid peroxidation

Lipid peroxidation in the liver is evaluated by measuring malondialdehyde (MDA) according to the method of Uchiyama and Mihara, 1978 [10]. MDA is one of the end products of the decomposition of polyunsaturated fatty acids (PUFAs) as a result of lipid peroxidation and reacts with thiobarbituric acid (TBA) at 100°C temperature and in acidic environment (pH 2-3). A molecule of MDA is condensed with two molecules of thiobarbituric acid (TBA) to form a colored complex in pink (reading at 532 nm).

#### Estimation of glutathione (GSH) level

The determination of GSH is based on the colorimetric method of Ellman, 1959 [11]. The glutathione assay is based on the oxidation reaction of GSH with acid 5,5'-dithiobis-2 nitro benzoic acid (DTNB) freeing the thionitrobenzoic acid (TNB) which absorbs at 412 nm.

#### Evaluation of Glutathione peroxidase (GPx) activity

GPx activity was measured by the method described by Flohe and Gunzler, 1984 [12]. Briefly, reaction mixture containing 0.4ml GSH (0.1 mM), 0.2ml TBS solution (Tris 50mM, NaCl 150mM PH 7.4) and 0.2 ml of tissue homogenate. After 5 min incubation at 25 °C, 0.2 ml of H<sub>2</sub>O<sub>2</sub> (1.3mM) was added in the mixture. The content was incubated at 37°C for 10 min. the reaction was stopped by 1 ml of 1% trichloroacetic acid (TCA) and centrifuged. Absorbance was recorded at 412 nm, and GPx activity was expressed as units/mg protein.

#### Measurement of catalase activity

Liver catalase activity was determined by the method of Claiborne, 1985 [13]. The homogenate was centrifuged at 2000 rpm for 15 min at 4° C. The supernatant was centrifuged at 9600 rpm for 30 min at 4° C (centrifuge SIGMA) and the final supernatant is the source used for the evaluation of the enzyme activity (catalase).

#### Histological studies

Immediately after sacrifice of rats, liver samples were removed and fixed in 10% formalin. The tissues were kept in the fixative for 12 h, dehydrated with serial ethanol cycles (70% to absolute), and then embedded in paraffin. The paraffin-embedded tissue was cut into 5 µm sections.

Tissue sections were stained with hematoxylin and eosin and observed under light microscopy [14].

#### Statistical analysis

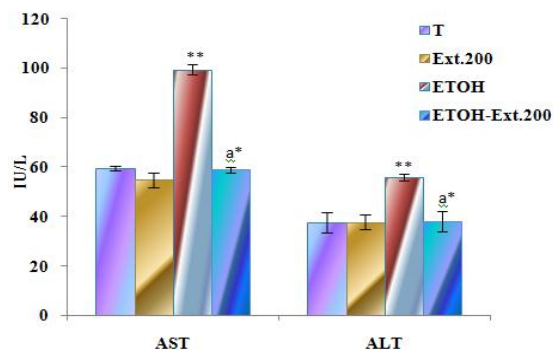
Data are expressed as the mean ± SD. Differences between means were evaluated by one-way analysis of variance (ANOVA). Statistical interferences were based on student's test for mean values comparing control and treated animals. Differences were considered significant at  $P < 0.05$ .

### RESULTS

#### Effect of *Genista quadriflora* on serum biochemical parameters

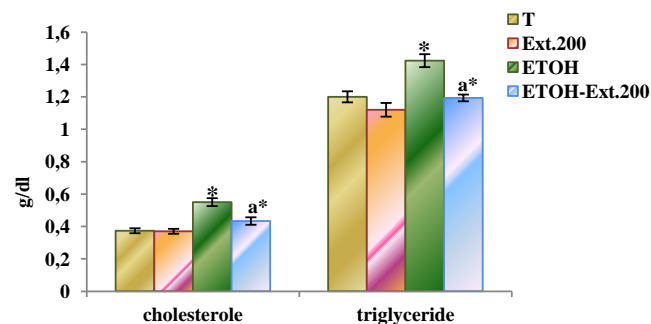
Ethanol caused significant increases in serum AST, ALT, total cholesterol and triglycerides levels ( $p < 0.01$ ;  $p < 0.05$ ) Compared to the control group indicated cell liver damage. While 200mg/kg of *n*-butanol extract administration caused a significant reductions ( $P < 0.05$ ) in these parameters compared to EtOH group (Fig.1 and

2). So, the *n*-butanol extract of *Genista quadriflora* (200mg/kg) protects the liver against toxicity caused by ethanol.



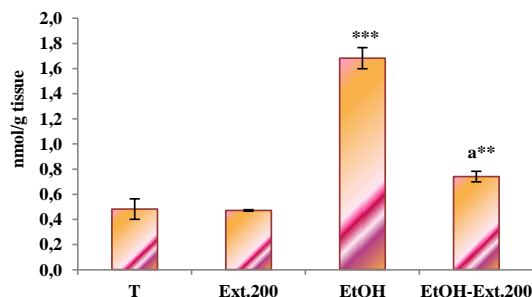
**Fig.1: Effects of n-butanol extract of *Genista quadriflora* and ethanol in serum AST and ALT.**

\* $P < 0.05$ ; \*\* $P < 0.01$ , compared to control group. a: compared to EtOH group; T: the untreated rats; EtOH: ethanol group; Ext.200: extract at the dose 200mg/kg; ETOH-Ext.200: ethanol+extract (200mg/kg)



**Fig.2: Effects of n-butanol extract of *Genista quadriflora* and ethanol in serum cholesterol and triglyceride.**

\* $P < 0.05$ ; \*\* $P < 0.01$ , compared to control group. a: compared to EtOH ethanol group; Ext.200: extract at the dose 200mg/kg; ETOH-Ext.200: ethanol+ extract (200mg/kg).

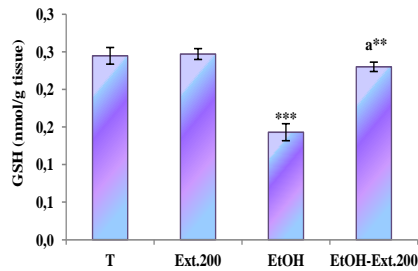


**Fig.3: Effects of n-butanol extract of *Genista quadriflora* and ethanol in MDA level.**

\*\* $P < 0.01$ ; \*\*\* $P < 0.001$ , compared to control group. a: compared to EtOH ethanol group; Ext.200: extract at the dose 200mg/kg; ETOH-Ext.200: ethanol+ extract (200mg/kg).

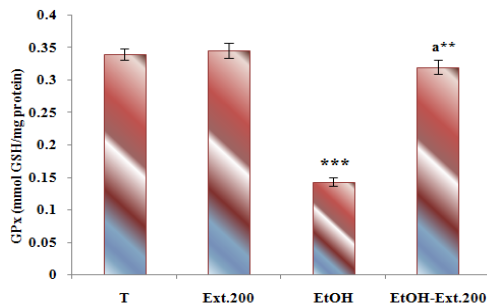
### In vivo antioxidant effect and MDA level of *Genista quadriflora*

Oxidative stress induced by ethanol caused significant ( $P < 0.001$ ) alterations in hepatic antioxidant defense system as GSH, GPx, CAT, and LPO levels compared to controls (Fig. 3,4,5,6). A significant change was observed in MDA level in rats treated with EtOH+extract (200mg/kg) ( $p < 0.01$ ). Extract treatment increased the level of reduced glutathione (GSH) and normalized the value of MDA compared to the EtOH group. The activity of the antioxidant system is maintained at normal levels in rats pretreated with the extract.



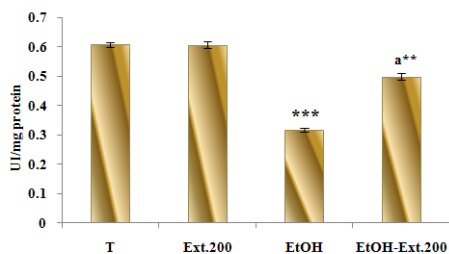
**Fig.4:** Effects of n-butanol extract of *Genista quadriflora* and ethanol in GSH level.

\*\* $P < 0.01$ ; \*\*\* $P < 0.001$ , compared to control group. a: compared to EtOH group; T: the untreated rats; EtOH: ethanol group; Ext.200: extract at the dose 200mg/kg; EtOH- Ext.200: ethanol+ extract (200mg/kg)



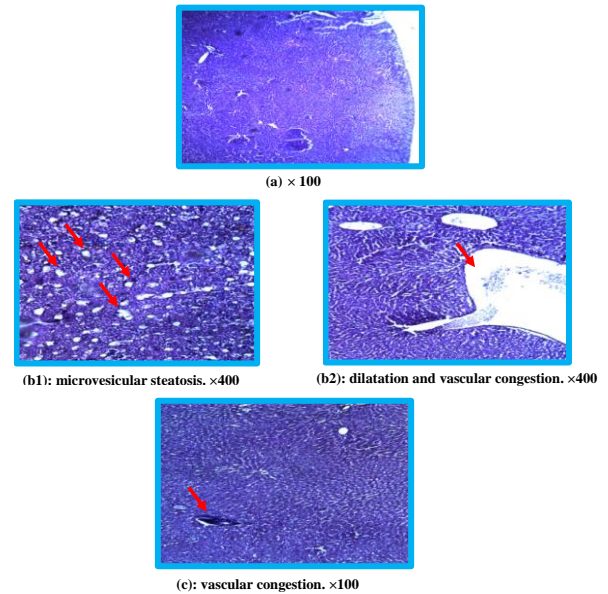
**Fig.5:** Effects of n-butanol extract of *Genista quadriflora* and ethanol in GPx level.

\*\* $P < 0.01$ ; \*\*\* $P < 0.001$ , compared to control group. a: compared to EtOH group; T: the untreated rats; EtOH: ethanol group; Ext.200: extract at the dose 200mg/kg; EtOH-Ext.200: ethanol+extract (200mg/kg)



**Fig.6:** Effects of n-butanol extract of *Genista quadriflora* and ethanol in Catalase level.

\*\* $P < 0.01$ ; \*\*\* $P < 0.001$ , compared to control group. a: compared to EtOH group; T: the untreated rats; EtOH: ethanol group; Ext.200: extract at the dose 200mg/kg; EtOH-



**Fig. 7:** Histological sections of livers from untreated and treated groups. (a): histology of normal control rat liver; (b1 and b2): histopathological seen in rats treated with ethanol; (c): liver of rats pretreated with n-butanol extract of *Genista quadriflora* (200mg/kg).

### Histology study

As shown in Figure 7 (a) the histological, features of the normal liver indicated a normal liver lobular architecture and cell structure. In liver sections of ethanol-treated group; showed dilatation and vascular congestion and microvesicular steatosis (Figure 7 b1 and b2). n-butanol extract of *Genista quadriflora*, showed protective effect on the hepatocellular steatosis, just occurrence of congestion of some vascular. (Figure 7 c)

### DISCUSSION

In the liver, the ethanol is oxidized to cytotoxic acetaldehyde by alcohol dehydrogenase and then to acetate by aldehyde dehydrogenase or xanthine oxidase [15]. This metabolism is accompanied by generation of free radical like ethyl and hydroxyl ethyl radicals. Ethanol inducible cytochrome CYP2E1 has high rate of NADPH oxidase activity that leads to the production of both superoxide anion and hydrogen peroxide at very high rate [16, 17].

In the present study the results were shown that the administration of ethanol caused severe acute liver damage in rats, as evidenced by the significant increase ( $p < 0.001$ ) in the MDA levels compared to the control group [18]. These results are in agreement with [4, 19]. Inhibition of LPO has been observed in *Genista quadriflora* extract treated groups due to their antioxidant and free radical scavenging activities through re-establishment of bio-membranes of hepatic parenchyma cells. The depletion of GSH induced generation of reactive oxygen species and oxidative stress with cascade of effects thereby affecting functional as well as structural integrity of cell and organelle membranes [20]. The elevated level of GSH with *Genista quadriflora* extract protected cellular proteins against oxidation through glutathione redox cycle and also directly detoxified reactive oxygen species and/or neutralized reactive intermediate species generated from exposure to ethanol.

Reactive oxygen species and free radicals are involved in oxidative stress-induced liver injury by ethanol. The restoration of the levels of decreased antioxidant profiles GPx and CAT by *Genista quadriflora* extract may be attributed to the biological significance in eliminating reactive free radicals that may affect the normal function of cells [21]. *Genista quadriflora* extract

significantly decreased ( $P < 0.05$ ) the activities of serum ALT and AST, which are biochemical markers of liver damage. This suggested a hepatoprotective activity of the extract against the acute toxicity of ethanol, these results concord with the results of Chaturvedi *et al.*, 2011[3]. ALT enzymes (alanine transaminase) are abundant in cytosol of hepatic parenchymal cells, while, aspartate transaminase (AST) is found in cytosol and mitochondria of hepatocytes [22]. It is also distributed in cardiac muscle, skeletal muscle, pancreas and kidney. Hence, ALT measurement liver is more specific to determine liver damage [23]. Increased ALT enzymes in ethanol-induced liver toxicity were due to the loss of structural integrity of liver. Since this enzyme is localized in the cytoplasm, it will be released into the blood circulation after cellular damage resulting in the elevation [24]. Increase of AST enzymes indicated that alcohol ingestion to rats causes both plasma membrane and organelle membrane (mitochondria) damage [6].

The benefits of n-butanol extract of *Genista quadriflora* has been further confirmed by histopathological observations. It was well-established that overdoses of ethanol lead to microvesicular steatosis with ballooning of hepatic cells (fatty liver). The three main mechanisms which may play a role in the development of alcoholic fatty liver which increased substrate supply for fatty acid esterification, direct stimulation of the esterification pathway and decreased export from the liver of triglyceride as Very-Low-Density Lipoproteins (VLDL) [25]. These effects have been significantly reduced with the pretreatment of n-butanol extract of *Genista quadriflora*.

#### CONCLUSION

In the present study, hepatoprotective effect of *Genista quadriflora* Munby extract against ethanol induced toxicity has been investigated. The protective effect of *Genista quadriflora* could be attributed to antioxidant, particularly phenols. n-butanol extract of *Genista quadriflora* scavenged free radicals and thus boosts the antioxidant capacity of organism.

#### ACKNOWLEDGMENTS

We are grateful to ATRSS and MESRS (DGRSDT) for financial support.

#### REFERENCES

- Mroueh M, Saab Y, Rizkallah R. Hepatoprotective activity of *Centaureum erythraea* on acetaminophen-induced hepatotoxicity in rats. *Phytother. Res.* 2004; 18: 431-433.
- Yesmin F., Rahman Z., Dewan J. F., Mazid Helali A., A Rahman N. I., Ahmed G. Alatraqchi, Ahmed A., Yousuf R., Salam A., Haque M. Hepato-protective role of the aqueous and n-hexane extracts of *Nigella sativa* linn. in experimental liver damage in rats. *Asian J Pharm Clin Res.* 2013; 6, Suppl 3: 205-209.
- Chaturvedi P, Pipedi-Tshekiso M, Moseki B and Kwape T E. Hepatoprotective potentials of water extract of *Bauhinia purpurea* bark against alcohol induced toxicity. *Sci Res Essays.* 2011; 6: 4347-4353.
- Esra Betül K, Betül E, Seval D, Gül Özdemirler E, Müjdat U, Necla kAk-toker. Effect of binge ethanol treatment on prooxidant-antioxidant balance in rat heart tissue. *Pathophysiology.* 2012; 19: 49-53.
- Tirapelli LF, Batalhão ME, Jacob-Ferreira AL, Tirapelli DP, Carnio EC, Tanus-Santosa JE, Queiroz RH, Uyemura SA, Padovan CM, Tirapelli CR. Chronic ethanol consumption induces histopathological changes and increases nitric oxide generation in the rat liver. *Tissue and Cell.* 2011; 43: 384- 391.
- Sutha D, Sabariah I, Surash R, Santhini M and Yam Mun F. Evaluation of the hepatoprotective activity of standardized ethanolic extract of *Curcuma xanthorrhiza* Roxb. *J. Med. Plant. Res.* 2010; 4: 2512-2517.
- Thenmozhi M., Dhanalakshmi M., Manjula Devi K., Sushila K., Thenmozhi S. Evaluation of hepatoprotective activity of leucas aspera hydroalcoholic leaf extract during exposure to lead acetate in male albino wistar rats. *Asian J Pharm Clin Res.* 2013; 6, Suppl 1: 78-81.
- Quezel P, Santa S. Nouvelle Flore de l'Algérie et des Régions Désertiques Méridionales, Tome I, ed. CNRS, Paris, 1962 p. 470.
- Concil of European Communities. *Offic. J. Eur. Communities*, 1986, (JO 86/609/CEE), L356:1-18.
- Uchiyama M, Mihara M. Determination of malonaldehyde precursor in tissues by thriarbituric acid test. *Anal. Biochem.* 1978; 86: 271-278.
- Ellman G. L. Plasma antioxidants. *Arch. Biochem. Biophys.* 1959; 82: 70- 77.
- Flohe L, Gunzler W.A. Assays of glutathione peroxidase. *Methods Enzymol.* 1984; 105:114-121.
- Clairborne A. Catalase activity, In: Greenwald R.A. (Ed), *CRC handbook of methods for oxygen radical research.* CRC Press, Boca Raton, FL, 1985; 283-284.
- Habhu PV, Shastry, RA, Mahadevan KM, Joshi H, Das SK. Hepatoprotective and antioxidant effects of *Argyrea speciosa* in rats. *Afr J Tradit Complement Altern Med.* 2008; 5, 158-164.
- Lieber CS. Role of oxidative stress and antioxidant therapy in alcoholic and non-alcoholic liver diseases. *Pharmacol.* 1997; 38: 601-628.
- Leiber CS. Metabolic consequences of ethanol. *Endocrinologist.* 1994; 4: 127-139.
- Zima T, Fialova L, Mestek O, Janebova M, Crkovska J, Malbohan I, Stipek S, Mikulikova L, Popov P. Oxidative stress, metabolism of ethanol and alcohol related disease. *J. Biomed. Sci.* 2001; 8: 59-70.
- Shokunbi OS, Odetola AA. Gastroprotective and antioxidant activities of *Phyllanthus amarus* extracts on absolute ethanol induced ulcer in albino rats. *J. Med. Plant. Res.* 2008; 2: 261-267.
- Wilson JI, Emonido OF, Akpulu SP, Igbigbi PS. Effect of ethanol and sialidase activities on the developing kidney of Wistar rats. *JCAB.* 2011; 5: 200-205.
- De Leve LD, Wang X, Kuhlenkamp JF, Kaplowitz N. Toxicity of azathioprine and monocrotaline in murine sinusoidal endothelial cells and hepatocytes: the role of glutathione and relevance to hepatic venoocclusive disease. *Hepatology.* 1996; 23: 589-599.
- Singh RP, Padmanathi B, Rao AR. Modulatory influence of *Adhatoda vesica* leaf extract on the enzymes of xenobiotic metabolism, antioxidant status and lipid peroxidation in Mice. *Mol Cell Biochem.* 2000; 213: 99-109
- James LP, Mayeux PR, Hinson JA. Acetaminophen-induced hepatotoxicity. *Drug Metab. Dispos.* 2003; 31: 1499-1506.
- Shyamal S, Latha PG, Shine VJ, Suja SR, Rajasekharan S, Devi TG. Hepatoprotective effects of *Pittosporum neelgherrense* Wight & Arn, a popular Indian ethnomedicine. *J. Ethnopharmacol.* 2006; 107:151-155.
- Sallie R, Tredger JM, William R. *Drugs and the liver.* *Biopharm Drug Dispos.* 1991; 12: 251-259.
- Salaspuro MP, Shaw S, Jayatileke E, Ross, WA, Lieber CS. Attenuation of the ethanol-induced hepatic redox change after chronic alcohol consumption in baboons: Metabolic consequences in vivo and in vitro. *Hepatology.* 1981; 1: 33-38.