

WOUND HEALING ACTIVITY OF *BINAHONG* LEAF EXTRACT NANOGEL ON ORAL TISSUES

OLIVIA AVRIYANTI HANAFIAH^{1*}, DENNY SATRIA², AMI ANGELA HARAHAP³, GOSTRY ALDICA DOHUDE¹,
CHANDRA LESTARI⁴, BERNARD⁴, AFIFAH AYUNI. HG⁴, TASYFINA HANNAN FAJAR⁵, HARRY KURNIA⁵

¹Department of Oral and Maxillofacial Surgery, Faculty of Dentistry, Universitas Sumatera Utara, Medan, Indonesia. ²Department of Pharmaceutical Biology, Faculty of Pharmacy, Universitas Sumatera Utara, Medan, Indonesia. ³Department of Pediatric Dentistry, Faculty of Dentistry, Universitas Sumatera Utara, Medan, Indonesia. ⁴Postgraduate Student, Faculty of Dentistry, Universitas Sumatera Utara, Medan, Indonesia. ⁵Undergraduate Student, Faculty of Dentistry, Universitas Sumatera Utara, Medan, Indonesia
*Corresponding author: Olivia Avriyanti Hanafiah; *Email: olivia.hanafiah@usu.ac.id

Received: 25 Jan 2024, Revised and Accepted: 05 Apr 2024

ABSTRACT

Objective: The objective of the present study is to formulate and evaluate a topical gel containing minoxidil and tofacitinib citrate for alopecia areata.

Methods: Forty-eight rat males were given treatment using 3% *binahong* leaf extract nanogel (twelve rats given palatal wound, twelve rats mandibular tooth extraction) and nanogel base (same with the amount used to extract). On palatal wounds, as many as four rats were in euthanasia on days third, seven, and fourteen for each group treatment. Whereas on the extraction groups, four rats were in euthanasia on days seventh, fourteen, and twenty-eight. palatal tissue and alveolar bone were taken, and fibroblasts as well as osteoblasts were observed using the coloring Hematoxylin-eosin.

Results: Data revealed there were significant differences in the number of fibroblasts in each treatment between day three and seven ($p < 0.05$), between day seven and fourteen ($p < 0.05$), and there were significant differences in the number of osteoblasts in each treatment for 3 periods ($p < 0.05$).

Conclusion: Application of *binahong* leaf extract nanogel on palatal wound increased fibroblast proliferation and on post-extraction socket increased the number osteoblasts indicating better wound healing compared to control.

Keywords: *Anredera cordifolia*, Soft tissue, Hard tissue, Wound healing, Fibroblast, Osteoblast

© 2024 The Authors. Published by Innovare Academic Sciences Pvt Ltd. This is an open access article under the CC BY license (<https://creativecommons.org/licenses/by/4.0/>)
DOI: <https://dx.doi.org/10.22159/ijap.2024.v16s2.07> Journal homepage: <https://innovareacademics.in/journals/index.php/ijap>

INTRODUCTION

Oral cavity known as a complex environment comprising both soft and hard tissues, which need to be regenerated or replaced due to defects [1, 2]. Wound in the oral cavity can be caused by disease, treatment, birth defects and/or trauma [1]. Dental extraction is one of the more frequent procedures performed in dentistry and causes damage to the adjacent soft and hard tissues [3, 4]. Bone healing process lasts 2-3 mo after tooth extraction and will be visible in the radiograph image if bone remineralization reaches at least 40 percent [5]. Besides, injury in the palatal site is undeniable which can be caused by trauma, defect, or surgical procedures [6, 7]. Palatal wound usually heals in 2-3 w and is more likely to develop scar tissue after healing [8]. Wound healing is a complicated physiological process which involves numbers of cells and chemical mediators (such as cytokines, chemokines, and growth factors) as described in many studies [9, 10]. Soft tissue and hard tissue experience the same phases of wound healing, including hemostasis, inflammatory, proliferative and maturation [3, 9].

Fibroblasts and osteoblast are two of which play a substantial role in the healing process of hard and soft tissue in the oral cavity [3]. At an early stage of healing, from the 3rd day to 1st week, Fibroplasia occurs, which is characterized by the active growth of fibroblasts [3, 4]. The most prevalent type of cell in connective tissue, the fibroblasts, is in charge of producing extracellular components (collagen, elastin, glycosaminoglycans, proteoglycans, and multi-adhesive glycoproteins) that form granulation tissue [3, 11]. Granulation tissue aims to prepare for the remodeling phase, when osteoblasts, osteoclasts, and osteocytes will start forming bones. Osteoblasts can be discovered in the alveolar healing process on the 7th day and will keep differentiating until more than 21st day [3]. As part of the mineralization process, osteoblasts have the ability to generate and secrete bone organic matrix and control electrolyte changes in extracellular fluid [12].

Herbal medicine has been introduced more as an alternative

medicine in the last two decades with the aim to reduce side effects from synthetic chemical drugs and more affordable prices [8, 13]. *Anredera cordifolia* (Ten.) Steenis, known as *binahong* in Indonesia, which belong to Basellaceae family plant that are known to be high-sustainable and grow in varied climates and has been used widely as traditional medicine in China, Taiwan, and Indonesia [3, 8]. Secondary metabolites extracted from *binahong* leaves contains flavonoids, terpenoids, tannins, saponins, ascorbic acid and oleanic acid, has been studied to have anti-inflammatory, anti-microbial, and promotes wound healing [3, 4]. Previous researchers have studied wound healing influence of *binahong* leaves extract gel in experimental animals [3, 4, 8, 11, 12, 14]. Application of 3% *binahong* leaves extract gel showed better promotion of palatal mucosa wound healing in Wistar rats than other concentrations [8]. Few other studies also showed that *binahong* leaves extract gel could accelerate tooth socket wound healing and increase alveolar bone healing shown by increasing the number of fibroblasts, osteoblasts and osteocytes [3, 4]. *Binahong* leaves extract gel is also proven to accelerate wound healing by increasing the expression of HIF-1, FGF-2, and BMP-2 on post-tooth extraction wounds in Wistar rats [11, 12, 14].

The most significant development in the realm of drug delivery was the change from hydrogel to nanogel [15]. Nanogels are hydrogels with nanoscale size ranging from 1-1000 nm [16, 17]. Due to their biocompatibility, versatility and stability in biological fluids, nanogels have a significant promise as cutting-edge drug delivery system [15, 17]. Nanogels can also be loaded with agents of various characteristics, as a result, it has been used widely as drug carriers [17]. Nanogel-based medications have been used for anti-cancer drugs, hemostatic, drugs for, autoimmune disease, anti-inflammatory, ophthalmic and neurodegenerative medications [18].

Therefore, the aim of this research is to know the effectiveness of *binahong* (*Anredera cordifolia* (Ten.) Steenis) leaves extract nanogel in increasing numbers of fibroblasts and osteoblasts to promote wound healing of soft and hard tissue within the oral cavity in Wistar rats.

MATERIALS AND METHODS

Chemicals

All chemicals use materials available in the Pharmaceutical Biology Laboratory, Faculty of Pharmacy and the Department of Histology, Faculty of Medicine, University of Sumatera Utara.

The 3% *binahong* leaf extract nanogel preparation

The 3% *binahong* leaf extract nanogel was made in the Pharmaceutical Biology Laboratory, Faculty of Pharmacy, University of Sumatera Utara. Start by adding the crushed extract into the nanogel base until homogeneous. Then, it was stirred at 2500 rpm for 8 h. The nanogel preparation particles were measured. Nanogel preparation of 35 *binahong* leaf extract and nanogel base then given 0.1 ml twice a day to the extraction socket and wound area.

Animals

Fifty-four male Wistar rats with an average body weight of 205.34g were provided by the Pharmaceutical Biology Laboratory, Faculty of Pharmacy, University of Sumatera Utara. Water and animal feed, according to laboratory standards are given ad libitum. The experimental protocol was approved by the animal research ethics committee, Faculty of Mathematics and Natural Sciences, University of Sumatera Utara (No. 0812/KEPH-FMIPA/2022) and approved its implementation after considering its relevance to human health which is guided by the principles of ethically tested animal research for research health using experimental animals.

Experimental groups

The animals were randomly divided into 12 groups, 6 groups were given 3% *binahong* leaf extract nanogel and the other 6 control groups were given nanogel base. Group 1 and 7 were euthanasia after 7 d of tooth extraction, group 2 and 8 were euthanasia after 14 d of tooth extraction, and group 3 and 9 were euthanasia after 28 d of tooth extraction. Group 4 and 10 were euthanasia after 3 d of making palatal wounds, groups 5 and 11 were euthanasia after 7 d of making palatal wounds, and groups 6 and 12 were euthanasia after 14 d of making palatal wounds.

Exhaustive research protocol

Administering 3% *binahong* leaf extract nanogel to experimental animals was started by making a palatal wound and removing the mandibular left incisor. The grouping protocol used in this study was an adaptation of Hanafiah *et al.* [3, 8] to observe the healing of palatal mucosa wounds and tooth socket wounds in Wistar rats. As much as 0.1 ml of both nanogel were given 2 times per day, in the morning and evening. Wound healing is clinically characterized by reduction to cover the wound area and histologically by increasing the number of fibroblasts and osteoblasts.

Euthanasia and sample storage

For the soft tissue group, euthanasia was performed on the 3rd, 7th,

and 14th days after making the palatal wound. Hard tissue group, euthanasia was performed on the 7th, 14th, and 28th day post-tooth extraction. Euthanasia of experimental animals using cervical dislocation, the middle of the palatal was cut crosswise using a sharp raspatory, and in experimental animals, for hard tissue examination, the alveolar bone was taken in the socket. Soft and hard tissue samples that had been taken were immediately fixed in a 10% Buffered Neutral Formalin (BNF) solution.

Cells analysis

Total fibroblast and osteoblast

The number of fibroblasts and osteoblasts was measured by calculating the mean cell count, which is a measurement method that shows the average number of fibroblast cells in the soft tissue of the palatal wound and osteoblast cells of the hard tissue of the socket wound after tooth extraction in Wistar rats. Samples were prepared and stained with hematoxylin-eosin, then observed using a light microscope with 400 times magnification at 5 fields of view. The calculation of fibroblast and osteoblast cells seen in each visual field was double-blinded by two different examiners using tally counter and calculator, then the results from each visual field were averaged [19].

Statistical analysis

In this study, data analysis was done by computerization. Data were analyzed first using the Shapiro-Wilk normality test. Then, proceed with the homogeneity of variance test using the Levene-Test test. If the data obtained is normally distributed and homogeneous, then it is continued with the One-Way ANOVA parameter test with a 95% confidence level, followed by LSD (Least Significant Difference) to find out the differences between groups. If the data obtained is not normally distributed, then the test used is the Kruskal-Wallis test.

RESULTS AND DISCUSSION

Fibroblast

Inspection test activity nanogels extract leaf *binahong* 3% against amount of cell fibroblasts especially formerly all data is tested normality and its homogeneity, shows the result data study the normally distributed and homogeneous. Cell fibroblasts were seen on the day the 3rd, 7th, and 14th after making a wound on the rat palatal mucosa. Cell fibroblasts experience enhancement on average the amount between days 3 and 7th, as well as experience decline between days 7 and 14 on the second group treatment (table 1). Differences in descriptions of fibroblasts from the results study can be seen clearly (fig. 1). The number of cell fibroblasts from the second group treatment show a meaningful difference after being tested using a one-way ANOVA test ($p < 0.05$). Results test the next use of LSD test to see the difference from each day treatment (table 2). There was a significant difference of fibroblasts between day 3 and 7, as well between day 7 and 14.

Table 1: Average amount of fibroblasts on the 3rd, 7th, and 14th day after making rat palatal wound

Treatment group	Observation	Amount Sampel	mean±SD	p-value
3% <i>binahong</i> extract nanogel	3 d	4	702.40±185.11	0.002*
	7 d	4	1016.75±132.02	
	14 d	4	504.10±62.48	
Base Nanogel	3 d	4	456.15±126.88	0.014*
	7 d	4	777.30±154.29	
	14 d	4	551.06±76.35	

*One-Way ANOVA test; $p < 0.05$; significant, Besides using one way ANOVA test, the data have done test advanced LSD for no difference between group treatments in a study, which can see in table 2.

Table 2: Results for total average LSD test fibroblasts on wound healing rat palatal mucosa

Treatment group	Observation	Comparison	The difference means±SE	p-value
3% <i>binahong</i> extract nanogel	3 d	7 d	-314.35±96.26	0.010*
	7 d	14 d	198.30±96.26	0.069
		14 d	512.65±96.26	0.000*
Base Nanogel	3 d	7 d	-321.15±87.30	0.005*
		14 d	-95.60±87.30	0.302
	7 d	14 d	225.55±87.30	0.030*

*Post-hoc LSD test; $p < 0.05$; significant

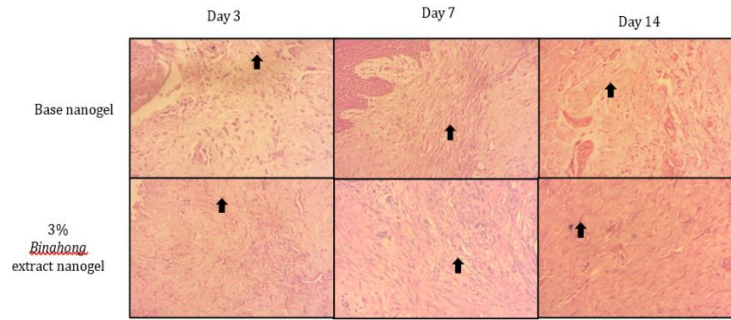


Fig. 1: Observation histopathology fibroblasts (arrows) on healing wound palatal mucosa. Observation on the day the 3rd, 7th, and 14th, after making a palatal wound, then colored with hematoxylin-eosin and seen using a microscope (400x)

Osteoblast

Normality and homogeneity tests were performed in all data obtained in this study and the data were normally distributed and homogeny. The differentiation of osteoblasts was examined on the 7th, 14th, and 28th day post tooth extraction. Both treatment groups showed an increase in numbers of osteoblasts from 7th to 14th and 28th day periods (table 3). Osteoblasts are visible along the matrix of the alveolar bone (fig. 2). The result of the one-way ANOVA test

showed significant statistical differences ($p < 0.05$) in osteoblasts cell count between two treatment groups (table 3). Both test results also showed significant differences ($p < 0.05$) among observation periods of time in each group (table 3). Then, LSD test performed and showed that there are significant differences between 7th and 28th days and between 14th and 28th days in both treatment groups (table 3). The significant differences in the number of osteoblasts were only observed in the 14th-day observation period between treatment groups (table 4).

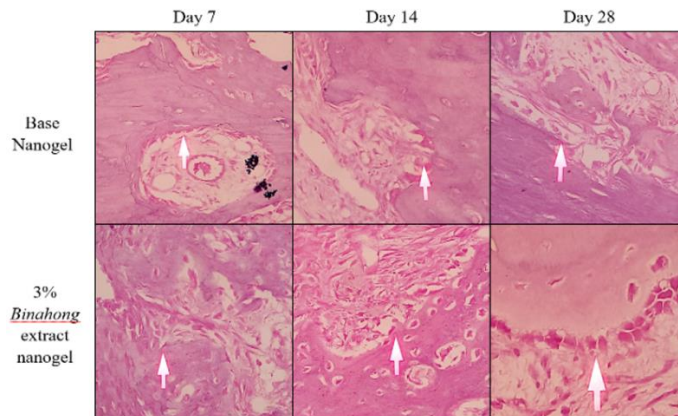


Fig. 2: Histopathological observation of osteoblasts (arrow) in the alveolar bone healing of tooth sockets. Observation period was on 7th, 14th, and 28th day post-extraction socket, then stained with hematoxylin-eosin with microscopes (400x)

Table 3: Effect of each treatment effect on tooth socket for three different time periods

Treatment group	Observation (day)	Osteoblast (mean±SD)	p-value	p-value
Base nanogel	7	18.70±10.042 ^a	0.0033*	0.0021*
	14	28.38±6.898 ^a		
	28	56.90±17.032 ^b		
3% binahong extract nanogel	7	32.30±8.015 ^a	0.0022*	
	14	52.25±7.170 ^a		
	28	85.96±26.019 ^b		

*Histopathological observation on osteoblasts is the parameter examined to indicate the effect of the treatment performed. Different superscript indicated significant statistical differences ($p < 0.05$) between time periods analyzed with the LSD test.

Table 4: Comparison of treatment effect on tooth socket for three different time periods

Observation (day)	Treatment group	Osteoblast (mean±SD)	p-value
7	Base nanogel	18.70±10.042	0.06
	3% binahong extract nanogel	32.30±8.015	
14	Base nanogel	28.38±6.898	0.005*
	3% binahong extract nanogel	52.25±7.170	
28	Base nanogel	56.90±17.032	0.08
	3% binahong extract nanogel	85.96±26.019	

*Histopathological observation on osteoblasts is the parameter examined to indicate the effect of the treatment performed. The superscript indicated significant statistical differences ($p < 0.05$) between treatment groups analyzed with LSD test.

This study shows the number of increased fibroblasts between days 3 and 7 and a decrease between days 7 and 14. Statistical data show exists a meaningful difference between days 3 and 7th as well as days to 7th and 14th; however, no there is a meaningful difference between days to 3rd and 14th of each group treatment (table 1 and table 2). Formation network granulation on wound signifies phase proliferation, where network granulation contains fibroblasts as well as cell inflammation. Results from this study follows the statement of Pebri *et al.* and Hanafiah *et al.*, namely that the beginning appearance of fibroblasts started from day 3 and keep going increase until the day of the 7th peak [8, 20]. Fibroblasts showed a form like a spindle or a cell-shaped star with an oval nucleus or round on HE staining (fig. 1). In the histopathology, inactive fibroblasts experience a change in morphology so, which is seen as cell elongation with a nucleus with small all-around fiber collagen [3, 8]. Picture histopathology shows that the on-base group is visible cell fibroblast accompanied with fiber less collagen solid, different with group nanogels extract *binahong* leaf 3% showing many cells formed fibroblasts with accompanied fiber dense collagen. This can be caused by the phytochemicals content on the *binahong* leaf, flavonoids and saponins increase the proliferation of fibroblasts and stimulate the collagen formation on the proliferation phase, which can speed up wound healing [21, 22].

The concentration of *binahong* leaf extract used in this investigation was based on Hanafiah *et al.*'s previous study on the effects of *binahong* leaf extract gel on the healing of palatal mucosal lesions [8]. In this study, the number of osteoblasts in both treatment groups increased from 7th to 14th and still increased to 28th day of the observation period (table 3). The result also showed only in the observation time of 14th day resulted in significant statistical differences between treatment groups (table 4). It is known that the proliferative phase usually starts during the first week and is divided into two parts, which is fibroplasia and bone formation [23]. A matrix created by osteoblasts is known as osteoid, and when osteoid is calcified, it forms woven bone [3, 12]. Until two weeks after tooth extraction, woven bone is still present in the wound and can be seen in the healing socket. Woven bone is temporary and must be replaced with mature bone types through bone modeling and remodeling phase, which will take up to months [23].

Binahong leaf is known to contain several secondary metabolites, such as flavonoid, tannin, alkaloid, saponin, and triterpenoid that are proven to promote wound healing. Flavonoid has an effect on reducing inflammation, increasing ALP, initiating osteoblast differentiation, and accelerating bone mineralization was documented [24, 25]. Tannin and alkaloid are known to prevent wound from free radicals and inhibit pathogenic bacteria growth [3, 26]. Saponin are documented to have increased osteoblast and bone mineralization. Triterpenoid, ursolic and oleanolic acid in the *binahong* leaf known to have antiseptic, antioxidant, and anti-inflammatory properties. Additionally, ursolic acid could affect osteoblast differentiation and growth as well as alkaline phosphatase (ALP) activity for bone mineralization [3, 27]. As a result, this investigation result also showed that there is a significant difference in the number of osteoblasts in 3% *binahong* leaf extract compare to base nanogel group (table 3).

CONCLUSION

Application nanogels extract leaf *binahong* 3% on palatal wound speed up proliferation cell fibroblasts and socket tooth post peel can push differentiation osteoblasts. So that sped up the healing of palatal wounds and bone better compared to group control.

FUNDING

Nil

AUTHORS CONTRIBUTIONS

All the authors of the manuscript have contributed equally to conceive and design the analysis, Collection the data, its analysis, manuscript writing, editing, and proofreading.

CONFLICTS OF INTERESTS

Declared none

REFERENCES

1. Bates D, Kampa P. Cell-based regenerative approaches to the treatment of oral soft tissue defects. *Int J Oral Maxillofac*

Implants. 2013;28(6):e424-31. doi: 10.11607/jomi.te22, PMID 24278955.

2. Nauta A, Gurtner GC, Longaker MT. Wound healing and regenerative strategies. *Oral Dis*. 2011;17(6):541-9. doi: 10.1111/j.1601-0825.2011.01787.x, PMID 21332599.
3. Hanafiah OA. Effects of 3% *binahong* (*Anredera cordifolia*) leaf extract gel on alveolar bone healing in post-extraction tooth socket wound in wistar rats (*Rattus norvegicus*). *F1000 Research*. 2022;10:1-20.
4. Hanafiah OA, Hanafiah DS, Syaflida R. The effect of 3% *binahong* leaf extract gel on the wound healing process of post tooth extraction. *Dent J*. 2021;54(2):57-62. doi: 10.20473/j.djmk.v54.i2.p57-62.
5. Haghghat A, Hekmatian E, Abdinian M, Sadeghkhan E. Radiographic evaluation of bone formation and density changes after mandibular third molar extraction: A 6 month follow up. *Dent Res J (Isfahan)*. 2011;8(1):1-5. PMID 22132008.
6. Alasqah M, Alrashidi A, Alshammari N, Alshehri A, Gufran K. Effect of honey dressing material on palatal wound healing after harvesting a free gingival graft: a prospective randomized case control study. *Eur Rev Med Pharmacol Sci*. 2022;26(8):2662-8. doi: 10.26355/eurrev_202204_28595, PMID 35503610.
7. Liu Y, Zhang S, Sakran KA, Yin J, Lan M, Yang C. Observation of palatal wound healing process following various degrees of mucoperiosteal and bone trauma in a young rat model. *Biology (Basel)*. 2022;11(8). doi: 10.3390/biology11081142, PMID 36009769.
8. Hanafiah OA, Abidin T, Ilyas S, Nainggolan M, Syamsudin E. Formulation and evaluation of *binahong* leaves extract gel on wound healing of the palatal mucosa. *J Biomimetics Biomater Biomed Eng*. 2020;48:85-91.
9. Goksen S, Balabanlı B, Coşkun Cevher S. Application of platelet-derived growth factor-BB and diabetic wound healing: the relationship with oxidative events. *Free Radic Res*. 2017;51(5):498-505. doi: 10.1080/10715762.2017.1327715, PMID 28480814.
10. Hanafiah OA. The role of TGF-beta 1 and PDGF-BB in wound healing of the palate. *Adv Heal Sci Res*. 2018;8:219-25.
11. Khoswanto C, Soehardjo I. The effect of *binahong* gel (*Anredera cordifolia* (Ten.) Steenis) in accelerating the escalation expression of HIF-1 α and FGF-2. *J Int Dent Med Res*. 2018;11:303-7.
12. Khoswanto C. Optimum concentration *Anredera cordifolia* (Ten.) steenis gel in increasing the expression BMP-2 and the number of osteoblasts post tooth extraction in wistar rats. *J Int Dent Med Res*. 2019;12:959-63.
13. Jain N. Dentistry: turning towards herbal alternatives: a review. *Sch J Appl Med Sci*. 2014;2:253-7.
14. Khoswanto C. Microvascular activity from the wound healing process in Wistar rats due to administration of *Anredera cordifolia* (Ten.) steenis. *J Int Dent Med Res*. 2021;14:1351-6.
15. Ahmed S, Alhareth K, Mignet N. Advancement in nanogel formulations provides controlled drug release. *Int J Pharm*. 2020;584:119435. doi: 10.1016/j.ijpharm.2020.119435, PMID 32439585.
16. Chen H, Zhang Y, Yu T, Song G, Xu T, Xin T. Nano-based drug delivery systems for periodontal tissue regeneration. *Pharmaceutics*. 2022;14(10):2250. doi: 10.3390/pharmaceutics14102250, PMID 36297683.
17. Li C, Obireddy SR, Lai WF. Preparation and use of nanogels as carriers of drugs. *Drug Deliv*. 2021;28(1):1594-602. doi: 10.1080/10717544.2021.1955042, PMID 34308729.
18. Zhang Zheng. Functional materials surface modified for the capture of circulating tumor cells. *NAT*. 2021;11(1):1-7. doi: 10.12677/NAT.2021.111001.
19. Sarkarat F, Modarresi A, Chiniforush N, Yazdanparast L, Rakhshan V. Efficacy of photodynamic therapy in minimizing bisphosphonate-related osteonecrosis of the jaws after dental extraction: a preliminary animal study. *J Oral Maxillofac Surg*. 2019;77(2):307-14. doi: 10.1016/j.joms.2018.09.036, PMID 30395823.
20. Pebri IG. Pengaruh pemberian ekstrak daun *binahong* (*Anredera cordifolia*) terhadap proses penyembuhan luka insisi (*vulnus incisivum*) pada mencit (*Mus musculus*). *J Ilm Mhs Vet*. 2017;2:1-11.

21. Ardiana T, Rizkia Putri Kusuma A, Dian Firdausy M. Efektivitas pemberian gel *binahong* (*Anredera cordifolia*) 5% terhadap jumlah sel fibroblas pada soket pasca pencabutan gigi marmut (*Cavia cobaya*). ODONTO: Dental Journal. 2015;2(1):64-70. doi: 10.30659/odj.2.1.64-70.
22. Gurcharan Singh GK, Utami NV, Usman HA. Effect of topical application of binahong [*Anredera cordifolia* (Ten.) steenis] leaf paste in wound healing process in mice. Althea Med J. 2014;1(1):6-11. doi: 10.15850/amj.v1n1.289.
23. Araujo MG, Silva CO, Misawa M, Sukekava F. Alveolar socket healing: what can we learn? Periodontol 2000. 2015;68(1):122-34. doi: 10.1111/prd.12082, PMID 25867983.
24. Hanafiah OA, Hanafiah DS, Syaflida R. The effect of topical application of 3% *binahong* (*Anredera cordifolia* (Ten.) steenis) leaves extract gel on the radiographic bone density in post-extraction socket. J Int Dent Med Res. 2021;14:736-41.
25. Zulkefli N, Che Zahari CNM, Sayuti NH, Kamarudin AA, Saad N, Hamezah HS. Flavonoids as potential wound-healing molecules: emphasis on pathways perspective. Int J Mol Sci. 2023;24(5). doi: 10.3390/ijms24054607, PMID 36902038.
26. Agyare C, Dwobeng AS, Agyepong N, Boakye YD, Mensah KB, Ayande PG. Antimicrobial, antioxidant, and wound healing properties of *Kigelia africana* (Lam.) beneth. and *strophanthus hispidus* DC. Adv Pharmacol Sci. 2013;2013:692613. doi: 10.1155/2013/692613, PMID 23662099.
27. Ismardianita E, Nasrul E, Yanwirasti Y, Hemiawati M. The effect of ethanol extract of *myrmecodia pendens* to TGF- β 1 expression and osteoblast cells after tooth extraction (the experimental research on *Cavia cobaya*). J Dentomaxillofac Sci. 2017;2:150-4.