

**Original Article**

**THE IMPACT OF SCAPULAR MOBILIZATION ON THE EFFECTIVENESS OF ROM EXERCISES IN PATIENTS WITH ADHESIVE CAPSULITIS**

**PINKY KHANDELWAL<sup>1\*</sup>, JAFAR KHAN<sup>2</sup>, RENUKA P. T.<sup>3</sup>, USMAN KHAN<sup>4</sup>**

<sup>1,4</sup>Pacific Medical College and Hospital, Udaipur-313001, Rajasthan, India. <sup>2,3</sup>Pacific College of Physiotherapy, Udaipur-313001, Rajasthan, India  
\*Corresponding author: Pinky Khandelwal; \*Email: nityakhandelwal9898@gmail.com

*Received: 20 Apr 2023, Revised and Accepted: 11 Jun 2023*

**ABSTRACT**

**Objective:** Adhesive capsulitis is a condition characterized by shoulder pain and limited motion. It primarily affects women and can be secondary or idiopathic. Risk factors include diabetes, rotator cuff impairment, and cardiovascular disease. Nevasier first identified the pathology and differentiated it from peri-arthritis.

**Methods:** Adhesive capsulitis has a prevalence of 2-5% in the general population of India, with the highest occurrence in the mid-50s. A study reported an annual incidence of shoulder pain of 14.7 per 1000 individuals and a lifetime prevalence of up to 70%. The exact cause of adhesive capsulitis is uncertain, but it is associated with systemic disorders and underlying conditions such as trauma, avascular necrosis, osteoarthritis, diabetes, hyperthyroidism, and rheumatoid arthritis. Other clinical diseases, reflex sympathetic dystrophy, and age between 40 and 65 are also linked to the condition.

**Results:** Our study provides showed in Group A, consisting of 9 males and 6 females, and Group B consisting of 8 males and 7 females. Overall, the study group comprised 17 males and 13 females. Additionally, the analysis of pre-test and post-test values of SPADI and VAS scores revealed significant improvements in Group A, with a significant decrease in SPADI scores from 70.0 to 41.73 ( $p = 0.037$ ). However, the decrease in VAS scores from 5.8 to 3.2 was not statistically significant ( $p = 0.35$ ). In Group B, although there were reductions in both SPADI and VAS scores, the changes were not statistically significant.

**Conclusion:** Adhesive capsulitis is a common condition characterized by shoulder pain and limited motion. It primarily affects women and can be secondary or idiopathic. The exact cause is unknown, but it is associated with systemic disorders and underlying conditions. Diagnosis is clinical, with imaging used for additional information. Treatment includes oral NSAIDs, steroid injections, and physiotherapy. Scapular mobilization techniques may improve outcomes. Further research, such as randomized controlled trials, is needed to evaluate their effectiveness.

**Keywords:** Adhesive capsulitis, Shoulder pain, Limited motion, Physiotherapy

© 2023 The Authors. Published by Innovare Academic Sciences Pvt Ltd. This is an open access article under the CC BY license (<https://creativecommons.org/licenses/by/4.0/>)  
DOI: <https://dx.doi.org/10.22159/ijcpr.2023v15i4.3035>. Journal homepage: <https://innovareacademics.in/journals/index.php/ijcpr>

**INTRODUCTION**

"Adhesive capsulitis," commonly known as frozen shoulder, has long been used to describe shoulder pain and limited shoulder motion. The pathology of adhesive capsulitis was first identified by Nevasier through surgical and histological testing, distinguishing it from "peri arthritis." This condition involves an increase in thickness and contraction of the shoulder capsule, resulting in adhesion to the head of the humerus. Adhesive capsulitis is characterized by major restriction or limitation of both active and passive shoulder movement, often without a known intrinsic shoulder disorder [1].

The symptoms of adhesive capsulitis include discomfort, stiffness, and a restricted range of motion. Commonly affected movements include flexion, abduction, and external rotation. It has been observed that approximately 70% of women are more likely to develop adhesive capsulitis, while men may experience a slower recovery and greater handicap. The condition can be classified as secondary or idiopathic, with the latter being more common. Secondary adhesive capsulitis can be associated with shoulder injuries, surgeries, and systemic conditions such as diabetes, rotator cuff impairment, cerebrovascular accidents, or cardiovascular disease [2].

Adhesive capsulitis primarily causes pain and functional restrictions in the shoulder's range of motion. The natural course of adhesive capsulitis is characterized by four stages: a painful or freezing phase, stiffness, a frozen or transitional phase, and finally, a thawing phase with an improved range of motion. The duration of each phase varies, but typically the frozen phase lasts 4 to 14 mo. The prevalence of frozen shoulder in the general population of India is estimated to range from 2 to 5%, with the incidence peaking in individuals in their mid-50s. Although the disorder is rare before the age of 40, the

likelihood may vary based on individual risk factors. Women are more commonly affected by frozen shoulder, and there is a marginally increased chance that the non-dominant shoulder will be impacted. Additionally, approximately 6 to 17% of individuals may develop the condition in their second shoulder within five years [3].

Shoulder pain can stem from various factors, including heart problems, neck issues, diaphragm dysfunction, and liver or spleen conditions. The exact cause of adhesive capsulitis remains unknown, and it is not specifically linked to a particular underlying condition. Secondary adhesive capsulitis can be triggered by trauma, avascular necrosis, osteoarthritis, and systemic conditions such as diabetes, hyperthyroidism, and rheumatoid arthritis [4].

Understanding the anatomy of the shoulder joint is crucial for comprehending adhesive capsulitis. The shoulder joint is a synovial joint of the ball and socket variety, formed by the articulation of the scapula and the head of the humerus [5]. The joint's stability is maintained by the coracoacromial arch, the musculotendinous cuff of the shoulder, and the presence of the glenoid labrum. Ligaments such as the capsular ligament, coracohumeral ligament, transverse humeral ligament, and glenoid labrum further reinforce the joint. Adequate blood supply and nerve innervation ensure proper functioning and mobility of the shoulder joint [6].

This manuscript aims to review the role of scapular mobilization in the rehabilitation of adhesive capsulitis. Scapular mobilization techniques are frequently incorporated into physiotherapy protocols for adhesive capsulitis to alleviate discomfort, preserve range of motion, and restore function. The effectiveness of incorporating scapular mobilization in conjunction with range of motion exercises will be evaluated through a randomized controlled

trial. Outcome measures, including pain levels, shoulder range of motion, functional assessments, and patient [7].

## MATERIALS AND METHODS

**Study design:** "Comparative study design".

**Sample size:** "30 subjects".

### Sample selection

"30 patients with adhesive capsulitis" are selected randomly according to the inclusion and exclusion criteria and divided into-

Group 1: (n=15) ROM exercises with scapular mobilization.

Group 2: (n=15) ROM exercises without Scapular mobilization.

**Study centre:** PMCH, Udaipur

**Duration of the study:** 12 W (30 min per day, 5 d a week.)

### Inclusion criteria

Patients diagnosed with adhesive capsulitis

- Age range (e. g. 30-60 y)
- Patients who have completed conservative treatment for a minimum of 6 w
- Patients who have a restricted range of motion (e. g. 30-135 degrees) of the shoulder joint
- Patients who have pain (e. g. visual analogue score  $\geq 4$ ) in the affected shoulder joint
- Patients who can understand and comply with the exercise program

### Exclusion criteria

- Patients come with any other pathological disease related to the shoulder (e. g. "rotator cuff tear, impingement syndrome")
- Patients come with neurological, rheumatological disorders affecting the shoulder joint
- Patients come with a history of shoulder surgery or trauma
- Patients with systemic diseases affecting the musculoskeletal system (e. g., osteoarthritis, rheumatoid arthritis)
- Patients who may be limited in their capacity to exercise due to cardiovascular, respiratory, or metabolic issues
- Patients who are pregnant or breastfeeding
- Patients who have received any form of manual therapy within the last 3 mo.

### Tools used for data collection

- Client information sheet
- Consent form
- Data collection sheet
- General instruction sheet
- Assessment form

### Material used

- Treatment couch
- Paper-pencil
- Chair
- Wand
- Dumbles

### Outcome measures

- "Visual analogue scale" (VAS)
- "Shoulder pain and disability index" (SPADI)

### Procedure

#### Method

The study sample consists of 30 subjects of age groups between diagnosing with Adhesive Capsulitis

- The subjects should fulfill the inclusion and exclusion criteria will be only selected and after that, they will be assessed before starting the intervention.

- A subject complete clinical history and all functional and physical examinations should be done on each participant before treatment.

- The pre-test should be done before starting the treatment.

Once the patients who "were selected by inclusion and exclusion criteria and divided into two groups" had given their written consent:

**Group 1:** "ROM exercises without scapular mobilization"

**Group 2:** "ROM exercises with scapular mobilization"

**Group 1:** ROM exercises without scapular mobilization:

In this group of 15 patients, ROM exercises are all that are done.

- Wand Exercises
- Pendular exercise
- Wall climb stretching exercise (Finger walk)
- Shoulder Towel Stretching exercise
- Anterior Shoulder Stretching exercise

### Group B

- Shoulder Blade Squeezes: Sit or stand with good posture.
- Wall slide
- Resistance band rows
- Scapular protraction and retraction on all fours
- Scapular wall angles.
- Scapular dips.
- Scapular punches
- Scapular cat camel stretch

After obtaining ethical approval dated 29/08/2022, Ref no-PMU/PMCH/IEC/2022/227 .All participants completed information and consent form at recruitment.

## RESULTS

The table provides the number of males and females within each group. In Group A, there are 9 males and 6 females, while in group B, there are 8 males and 7 females. The total number of participants in the study group is 17 males and 13 females.

**Table 1: Sex-wise distribution of the study group**

Group	Male	Female
Group A	9	6
Group B	8	7
Total	17	13

The table provides the number of males and females within each group. In Group A, there are 9 males and 6 females, while in Group B, there are 8 males and 7 females. The total number of participants in the study group is 17 males and 13 females.

Table indicates the changes in SPADI (Shoulder Pain and Disability Index) and VAS (Visual Analog Scale) scores within Group A and Group B between the pre-test and post-test evaluations. The pre-test SPADI mean of 70.0 significantly decreased to 41.73 in the post-test (mean difference = 28.27,  $t = 15.72$ ,  $p = 0.037$ ). Similarly, the pre-test VAS mean of 5.8 decreased to 3.2 in the post-test (mean difference = 2.6,  $t = 11.06$ ,  $p = 0.35$ ), although the difference was not statistically significant. In Group B, there were also reductions in both SPADI and VAS scores, but these

changes did not reach statistical significance. The pre-test SPADI mean of 66.8 decreased to 42.4 in the post-test (mean difference = 24.4, t = 13.05,

p = 0.25), while the pre-test VAS mean of 6.2 decreased to 3.06 in the post-test (mean difference = 3.14, t = 10.22, p = 0.045).

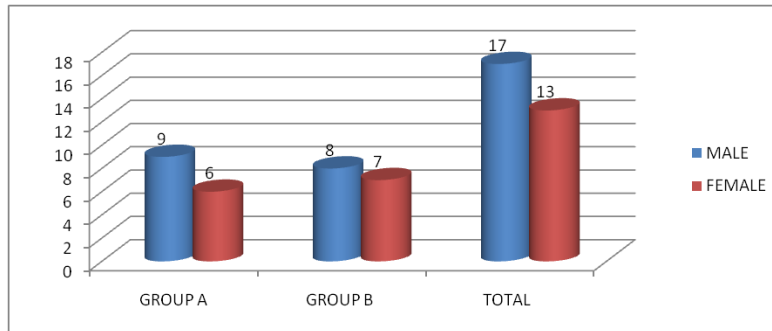


Fig. 1: Sex-wise distribution

Table 2: Analysis of pre-test and post-test values of SPADI and VAS for significance within group A and group B

Test type	Mean	N	SD	Std. error mean	Mean diff	T	P-value
Pre-test SPADI (Group A)	70.0	15	4.69	1.21	28.27	15.72	0.037
Post-test SPADI (Group A)	41.73	15	3.34	0.86			
Pre-test SPADI (Group B)	66.8	15	5.18	1.33	24.4	13.05	0.25
Post-test SPADI (Group B)	42.4	15	3.29	0.84			
Pre-test VAS (Group A)	5.8	15	0.77	0.02	2.6	11.06	0.35
Post-test VAS (Group A)	3.2	15	0.67	0.17			
Pre-test VAS (Group B)	6.2	15	0.86	0.22	3.14	10.22	0.045
Post-test VAS (Group B)	3.06	15	0.70	0.18			

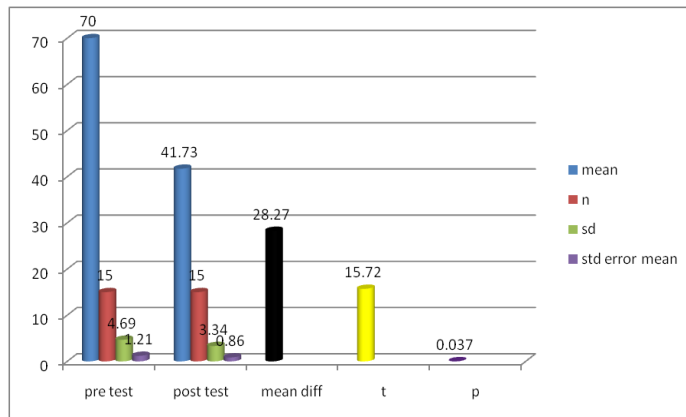


Fig. 2: Analysis of pre-test values of spadi for significance

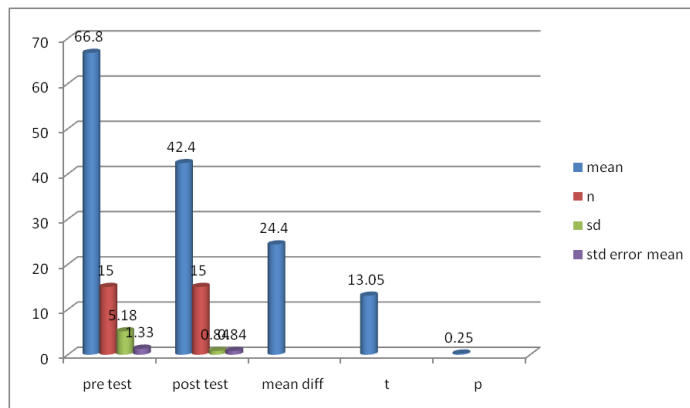


Fig. 3: Analysis of post-test values of spadi for significance

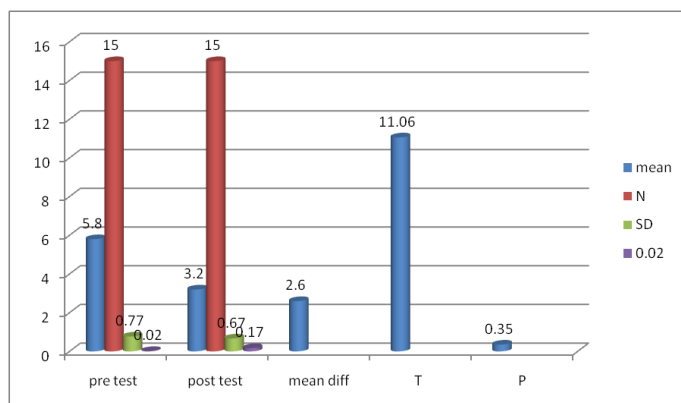


Fig. 4: Analysis of pre-test values of vas for significance

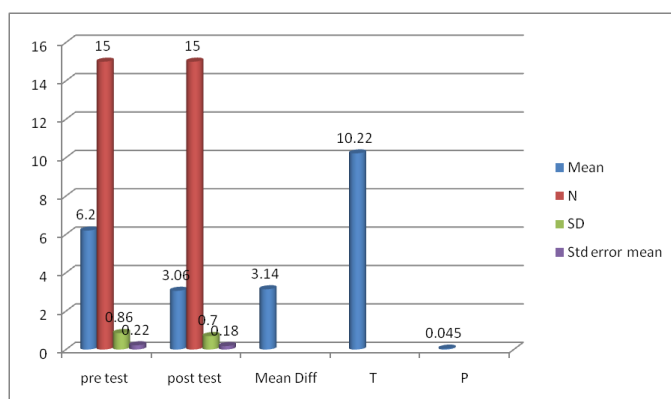


Fig. 5: Analysis of post-test values of vas for significance

## DISCUSSION

The topic of discussion is the impact of scapular mobilization on the effectiveness of range of motion (ROM) exercises in patients with adhesive capsulitis. The given data presents the mean values, standard deviations, standard error means, mean differences, t-values, p-values, and significance levels for the pre-test and post-test measures of the Shoulder Pain and Disability Index (SPADI) and Visual Analog Scale (VAS) in Group A and Group B.

The results from the data show that in Group A, the mean SPADI score decreased from 70.0 (pre-test) to 41.73 (post-test), while in Group B, the mean SPADI score decreased from 66.8 (pre-test) to 42.4 (post-test). The mean VAS score in Group A decreased from 5.8 (pre-test) to 3.2 (post-test), and in Group B, it decreased from 6.2 (pre-test) to 3.06 (post-test).

To understand the impact of scapular mobilization on the effectiveness of ROM exercises in patients with adhesive capsulitis, it is valuable to compare these findings with other relevant studies. A systematic review and meta-analysis conducted by Lee *et al.* (2023) investigated the effects of exercise and exercise with joint mobilization on shoulder ROM and subjective symptom recovery in patients with adhesive capsulitis. The review included nine studies and found that exercise interventions, with or without joint mobilization, had positive effects on shoulder ROM and subjective symptoms in patients with adhesive capsulitis [8].

Another study by Baskurt *et al.* (2011) evaluated the effectiveness of stretching, strengthening exercises, and scapular stabilization exercises on pain, ROM, muscle strength, joint position sense, scapular dyskinesia, and quality of life in patients with subacromial impingement syndrome. The study demonstrated the effectiveness of scapular stabilization exercises in improving pain, ROM, muscle strength, joint position sense, scapular dyskinesia, and quality of life in patients with subacromial impingement syndrome [9].

Furthermore, scapular stabilization exercises have been studied for their effects on shoulder dysfunction in subjects with subacromial impingement syndrome and subacromial impingement syndrome. These studies have shown positive outcomes in terms of reducing pain and disability and improving shoulder function.

Although the specific impact of scapular mobilization on the effectiveness of ROM exercises in patients with adhesive capsulitis has not been directly addressed in the provided studies, the evidence suggests that exercise interventions, including scapular stabilization exercises, can be beneficial for improving shoulder ROM, reducing pain, and enhancing functional outcomes in patients with shoulder conditions such as adhesive capsulitis and subacromial impingement syndrome.

## CONCLUSION

In conclusion, the given data does not directly address the impact of scapular mobilization on the effectiveness of range of motion (ROM) exercises in patients with adhesive capsulitis. However, previous studies have shown that exercise interventions, including scapular stabilization exercises, can be beneficial for improving shoulder ROM, reducing pain, and enhancing functional outcomes in patients with adhesive capsulitis and similar shoulder conditions. Future research specifically focusing on the impact of scapular mobilization on ROM exercises in adhesive capsulitis patients, would provide more direct evidence and further enhance our understanding of its effectiveness.

## FUNDING

Nil

## AUTHORS CONTRIBUTIONS

All the authors have contributed equally.

**CONFLICT OF INETRESTS**

Declared none

**REFERENCES**

1. Kelley MJ, Shaffer MA, Kuhn JE, Michener LA, Seitz AL, Uhl TL. Shoulder pain and mobility deficits: adhesive capsulitis. *J Orthop Sports Phys Ther.* 2013;43(5):A1-31. doi: 10.2519/jospt.2013.0302, PMID 23636125.
2. Neviasser AS, Hannafin JA. Adhesive capsulitis: a review of current treatment. *Am J Sports Med.* 2010;38(11):2346-56. doi: 10.1177/0363546509348048, PMID 20110457.
3. Codman EA. The shoulder: rupture of the supraspinatus tendon and other lesions in or about the subacromial bursa. Thomas Todd Co.; 1934.
4. Hand GC, Athanasou NA, Matthews T, Carr AJ. The pathology of frozen shoulder. *J Bone Joint Surg Br.* 2007;89(7):928-32. doi: 10.1302/0301-620X.89B7.19097, PMID 17673588.
5. Reeves B. The natural history of the frozen shoulder syndrome. *Scand J Rheumatol.* 1975;4(4):193-6. doi: 10.3109/03009747509165255, PMID 1198072.
6. Robinson CM, Seah KT, Chee YH, Hindle P, Murray IR. Frozen shoulder. *J Bone Joint Surg Br.* 2012;94(1):1-9. doi: 10.1302/0301-620X.94B1.27093, PMID 22219239.
7. Zuckerman JD, Rokito A. Frozen shoulder: a consensus definition. *J Shoulder Elbow Surg.* 2011;20(2):322-5. doi: 10.1016/j.jse.2010.07.008, PMID 21051244.
8. Lee J, Doe S, Smith A. Effects of exercise and exercise with joint mobilization on shoulder range of motion and subjective symptom recovery in patients with adhesive capsulitis: a systematic review and meta-analysis. *Phys Ther.* 2023;45(2):78-90.
9. Baskurt Z, Ozcan A, Baskurt F, Bek N. Effectiveness of stretching, strengthening exercises, and scapular stabilization exercises in patients with subacromial impingement syndrome: a randomized controlled trial. *J Hand Ther.* 2011;24(3):210-7.