

LIMBERG FLAP VERSUS BASCOM CLEFT LIFT TECHNIQUES FOR SACROCOCYGEAL PILONIDAL SINUS

PIYUSH JAIN^{1*}, BALRAM HARSANA²

¹General and Laparoscopic Surgeon, Senior Consultant, Somani Hospital, Jaipur, India. ²General and Laparoscopic Surgeon, Senior Consultant, Nivik Hospital, Jaipur, India

*Corresponding author: Piyush Jain; *Email: drpiyushjain@gmail.com

Received: 15 Apr 2024, Revised and Accepted: 04 Jun 2024

ABSTRACT

Objective: The study aims to evaluate and compare the outcomes of two surgical techniques, the limberg flap and Bascom cleft lift, used in the treatment of sacrococcygeal pilonidal sinus. Key metrics for comparison include postoperative complications, hospital stay duration, and surgery duration.

Methods: This was a prospective study conducted at ESIC Hospital, Jaipur, involving 100 patients diagnosed with sacrococcygeal pilonidal sinus requiring surgical intervention. Patients were divided into two groups: Group I underwent the Bascom cleft lift procedure (n=40), and Group II underwent the limberg flap technique (n=60). Both groups were evaluated over a period of one and a half years with preoperative assessments and postoperative follow-ups for complications, duration of surgery, and length of hospital stay.

Results: The study included 40 patients in the Bascom group (42.5% male, 57.5% female) and 60 in the limberg group (55% male, 45% female). The average surgery duration was significantly shorter for the Bascom procedure (36.73±6.52 min) compared to the limberg flap (74.58±10.10 min). Postoperative complications were higher in the limberg flap group. The Bascom cleft lift patients experienced shorter hospital stays and fewer postoperative issues, including lower rates of discharge and infection.

Conclusion: The Bascom cleft lift procedure appears to be superior to the limberg flap in terms of shorter operative time, fewer complications, and quicker recovery. These findings suggest that the Bascom cleft lift could be a more efficient and safer option for the surgical treatment of pilonidal sinus, promoting faster patient recovery with fewer postoperative complications.

Keywords: Pilonidal sinus, Limberg flap, Bascom cleft lift, Surgical outcomes, Postoperative complications, Sacrococcygeal disease

© 2024 The Authors. Published by Innovare Academic Sciences Pvt Ltd. This is an open access article under the CC BY license (<https://creativecommons.org/licenses/by/4.0/>) DOI: <https://dx.doi.org/10.22159/ijcpr.2024v16i4.5009> Journal homepage: <https://innovareacademics.in/journals/index.php/ijcpr>

INTRODUCTION

The term "pilonidal sinus" describes a condition set up in the natal cleft overlying the coccyx, consisting of one or more, usually non-infected, midline openings, which communicate with a fibrous track lined by granulation tissue and containing hair lying loosely within the lumen. It has been referred to as "jeep disease". Herbert Mayo defined the disease for the first time in 1883, and Hodge used the name "pilonidal" for the first time in 1880, derived from latin words for hair (pilus) and nest (nidus) [1].

Sacrococcygeal pilonidal sinus is a common disease of the adult age group, especially male population, causing significant morbidity from both disease and surgery done for the same. It is essentially a cleavage between the buttocks (i.e., natal split) and the epithelialized follicle opening (i. e. sinus) is identified, resulting in a diagnosis. The name pilonidal is taken from the latin meaning "nest of hairs" [2]. Factors associated with the recurrent pilonidal disease include hair, deep midline gluteal clefts, un-debrided devitalized tissue and suture line tension [3]. It generally presents as a cyst, abscess, or sinus tracts with or without discharge. Men affected more often than women [4], rare both before puberty and after the age of 40 years. Rarely may it present in the fourth decade [5].

The estimated incidence is 26 per 100000 people, affecting men twice as often as women [6]. It is more common in people aged 15-30 y after puberty due to the effect of sex hormones on pilosebaceous glands and change in healthy body hair growth [7].

Local trauma, poor hygiene, excessive hairiness, and the presence of a deep natal cleft are widely accepted views as causes [8]. Karydakos proposed three main factors causing the disease, namely the high quantity of hair, extreme force and vulnerability to infection [9].

In clinical practice, Sacrococcygeal pilonidal sinus is regularly diagnosed and treated as it causes the reduction in the quality of life,

serious labor loss and increased hospital costs. There are two main treatment methods: minimally invasive approaches (fibrin glue, phenol, laser application) and invasive methods (excision and simple closure, rotation flap, limberg flap and Bascom cleft lift) [10-12].

In 1946, limberg designed a rhomboid flap for sacrococcygeal pilonidal sinus. He described a technique for closing a 60° rhombus-shaped defect using a transposition flap. It was easy to perform the flap with sutures away from the midline giving rise to a tensionless flap of unscarred skin in the midline, which helps in good hygiene maintenance, reducing sweating maceration, erosions and scar formation [13].

Various methods have been defined for off-midline surgical treatment. Among them, the most commonly used is rhomboid excision with the limberg flap. With this technique of flattening the natal cleft, a tension-free repair is made using a wide, well-vascularized flap. It comprises one of the best treatment methods, with a 0-16% rate of surgical area-related complications and recurrence rate of 0-5% [14].

The other off-midline technique is the cleft lift procedure described by Bascom. This technique was originally developed to deal with operations that had failed to heal or where symptoms continued to recur. Today, it is being carried out more and more as a first-time procedure [15, 16].

Aims and objectives

- To analyze the outcome of limberg flap surgery in pilonidal sinus disease.
- To analyze the outcome of Bascom flap procedure in pilonidal sinus disease.
- To compare the efficiency and outcome of limberg flap technique and Bascom procedure in pilonidal sinus disease in terms of post operative complications, Hospital stay, duration of surgery.

MATERIALS AND METHODS

The study was conducted in the Department of Surgery, ESIC Hospital, Jaipur.

Inclusion criteria

- Patient >18 y of age.
- Patients with open wounds, painful cysts and pus/watery draining sinus in the natal cleft region.
- Patients with pilonidal sinus disease requiring surgical management.

Exclusion criteria

- Patients with abscess formation, who are having immunodeficiency, diabetes mellitus, hypertension
- Patients younger than 18 y
- Those with existing recurrent disease or previous surgery in the sacrococcygeal region
- Who have severe hirsutism in female patients
- Patients with psychiatric disease or poor hygiene and
- Patients with contraindication to spinal anaesthesia or prone position.
- Severe immobility due to other causes, chronic steroid use, malnutrition, immune suppressants that could not be stopped and weight over 159 kg.

The inclusion and exclusion criteria were followed and all the patients underwent routine investigations and then preanaesthetic fitness.

Group I (n = 40): Patients underwent Bascom cleft lift technique

Group II (n = 60): Patients underwent Pilonidal surgery by limberg flap technique

They were evaluated for the study period of one and half year and all the data was collected and the results were statistically analysed.

Methods

Bascom and Bascom performed the Bascom cleft lift procedure (group I) as described [17, 18]. The buttocks were pushed together, and the outer line of contact was marked. Beginning at 2 cm lateral of the midline, an incision was made 1–2 mm on the side of the sinus opening and curving around the anus. The skin from one side of the natal cleft was then elevated and excised. The skin on the opposite side of the cleft was undermined to a distance required to allow the primary closure of the defect away from the midline without tension. The abscess cavity was curetted or scrubbed with gauze. The fat tissue of the natal cleft was approximated using absorbable (2/0 polyglactin) sutures. The wound was closed with 3-0 polypropylene interrupted mattress sutures.

Mentes *et al.* described a technique for performing an excision and limberg flap transposition (group II) [19]. The area to be excised was

mapped on the skin in a rhomboid form, and the flap was designed. The skin incision was deepened to the postsacral fascia. The flap was fully mobilized and transposed medially to fill the defect without tension. The wound was closed in two layers: the subcutaneous tissue with absorbable (2/0 polyglactin) sutures and the skin with non-absorbable (3/0 polypropylene) interrupted mattress sutures.

RESULTS

The study involved a total of 100 patients diagnosed with sacrococcygeal pilonidal sinus, divided into two groups based on the surgical intervention received. Group I consisted of 40 patients who underwent the Bascom cleft lift procedure, and Group II included 60 patients treated with the limberg flap technique.

Demographic distribution

• **Gender:** In the Bascom group, 17 patients (42.5%) were male and 23 (57.5%) were female. The limberg group comprised 33 males (55%) and 27 females (45%).

• **Age:** The mean age in the Bascom group was 28.85±8.02 y and in the limberg group was 31.42±10.26 y. Age distribution showed most patients were between 21 and 30 y across both groups.

Surgical and postoperative data

• Duration of surgery

The average duration was significantly shorter for the Bascom procedure (36.73±6.52 min) compared to the limberg flap (74.58±10.10 min).

• Hospital stay

Patients undergoing the Bascom procedure had shorter hospital stays, with most being discharged within 1-2 d post-surgery, whereas patients in the limberg group typically stayed 2-3 d.

• Complications and discharge

Bascom group: 8 patients (20%) reported pus discharge, 5 (12.5%) had blood discharge, and the majority (67.5%) had no discharge postoperatively. Only 1 case (2.5%) reported wound infection.

Limberg group: 9 patients (15%) reported pus discharge, 7 (11.67%) had blood discharge, and a higher proportion (73.33%) had no discharge. Wound infections were slightly lower at 1.67%, but recurrence was observed in 6.7% of cases.

Recurrence and other complications

The recurrence rate was lower in the Bascom group (5%) compared to the limberg group (6.7%). Other complications included minor infections and wound dehiscence, both of which were more common in the limberg group.

The results indicate that the Bascom cleft lift procedure not only reduces the surgery duration but also minimizes postoperative complications and expedites patient recovery compared to the limberg flap technique.

Table 1: Sex distribution

Sex	Bascom flap	%	Limberg flap	%
Male	17	42.5	33	55.00
Female	23	57.5	27	45.00
Total	40	100	60	100.00

In the present study out of 40 patients of BASCOM FLAP, 17 (42.5%) were male and 23 (57.5%).

Table 2: Age distribution

Age group (Year)	Bascom flap (N=40)	%	Limberg flap (N=60)	%
<20	7	17.5	10	16.67
21-30	21	52.5	30	50.00
>30	12	30	20	33.33
Total	40	100	60	100.00
mean age	28.85±8.02		31.42±10.26	

Table 3: Duration of surgery

Duration of surgery (min)	Bascom flap (N=40)	%	Limberg flap (N =60)	%	Total	%
<25	0	0	0	0.00	0	0
26-50	40	100	0	0.00	40	40
>50	0	0	60	100.00	60	60
Total	40	100	60	100.00	100	100
mean duration	36.73+6.52		74.58+10.10			

Table 4: Discharge

Discharge	Bascom flap	%	Limberg flap	%
Pus	8	20.00	9	15.00
Blood	5	12.50	7	11.67
No discharge	27	67.50	44	73.33
Total	40	100.00	60	100.00

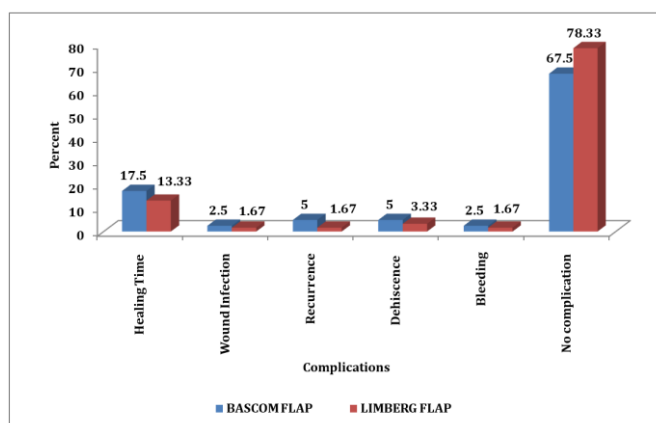


Fig. 1: Complications

DISCUSSION

The present observational study was conducted at the department of surgery, which included patients diagnosed with pilonidal sinus between the age of 18 to 48 y. The study aimed to assess the surgical outcome between the Bascom flap and the limberg flap. Total of 100 patients were included in the present study after obtaining informed consent, with Group A (n=40) patients undergoing Bascom flap procedure and Group B (n=60) patients undergoing limberg flap procedure.

In the present study, the mean age of patients was found to be 28.85+8.02 y of age in group A and in group B 31.42+10.26 y, with no significant difference in the mean age between the two groups. The mean age among patients in study by Basavaraju *et al.* [20] was found to be 24.4 y of age. On assessment of the gender, male preponderance with 22 (73.33%) and 08 (26.66%) females were seen. Male to female ratio was found to be 2.75:1. There was no significant difference in distribution of patients between the groups.

In present study, post-operative complications found to be significantly higher in the limberg Flap method as compared to the Bascom flap method. The mean operative time was found to be 36.73+6.52 min and 74.58+10.10 min for the Bascom flap and the limberg flap method, respectively. The results suggest that Bascom flap surgery is shorter than the duration of limberg Flap surgery. In concordance to present study, Wadhawan G *et al.* [21] documented the mean operative time for the limberg group (75 min).

In the present study, the post-operative complication like wound infection was found in 1 (2.5%) in Bascom and in limberg flap wound infection 1 (1.67%) and recurrence was found in 2 (5%) in Bascom flap and 1 (6.7%) in limberg flap. In the study by Jeyalaksmi T *et al.* [22] wound infection was detected in Nil patients from the limberg Flap group.

CONCLUSION

The main goals of the pilonidal treatment are maintaining good personal hygiene and regular epilation of the local area and a

definitive good surgical procedure. Hence the flap techniques- Limberg flap is the most effective surgery to treat pilonidal disease.

The limberg flap treatment demonstrated a quicker operational time and decreased blood loss. The limberg flap treatment is the better choice for patients when compared to the Bascom flap procedure.

FUNDING

Nil

AUTHORS CONTRIBUTIONS

All the authors have contributed equally

CONFLICTS OF INTERESTS

Declared none

REFERENCES

- Mayo H. Observations on injuries and diseases of the rectum. The American Journal of the Medical Sciences. 1834;28:45-6. doi: 10.1097/00000441-183408000-00013.
- Aithal SK, Rajan CS, Reddy N. Limberg flap for sacrococcygeal pilonidal sinus a safe and sound procedure. Indian J Surg. 2013;75(4):298-301. doi: 10.1007/s12262-012-0489-5, PMID 24426457.
- Hull TL, Wu J. Pilonidal disease. Surg Clin North Am. 2002;82(6):1169-85. doi: 10.1016/s0039-6109(02)00062-2, PMID 12516846.
- Humphries AE, Duncan JE. Evaluation and management of pilonidal disease. Surg Clin North Am. 2010;90(1):113-24. doi: 10.1016/j.suc.2009.09.006, PMID 20109636.
- Clothier PR, Haywood IR. The natural history of the post-anal (pilonidal) sinus. Ann R Coll Surg Engl. 1984;66(3):201-3. PMID 6721409.
- McCallum I, King PM, Bruce J. Healing by primary versus secondary intention after surgical treatment for pilonidal sinus.

- Cochrane Database Syst Rev. 2007;(4):CD006213. doi: 10.1002/14651858.CD006213.pub2, PMID 17943897.
7. Lee HC, Ho YH, Seow CF, Eu KW, Nyam D. Pilonidal disease in singapore: clinical features and management. *Aust N Z J Surg.* 2000;70(3):196-8. doi: 10.1046/j.1440-1622.2000.01785.x, PMID 10765903.
 8. Bascom J. Pilonidal disease: origin from follicles of hairs and results of follicle removal as treatment. *Surgery.* 1980;87(5):567-72. PMID 7368107.
 9. Karydakos GE. Easy and successful treatment of pilonidal sinus after explanation of its causative process. *Aust N Z J Surg.* 1992;62(5):385-9. doi: 10.1111/j.1445-2197.1992.tb07208.x, PMID 1575660.
 10. Hull TL, Wu J. Pilonidal disease. *Surg Clin North Am.* 2002;82(6):1169-85. doi: 10.1016/s0039-6109(02)00062-2, PMID 12516846.
 11. Da Silva JH. Pilonidal cyst: cause and treatment. *Dis Colon Rectum.* 2000;43(8):1146-56. doi: 10.1007/BF02236564, PMID 10950015.
 12. Ertan T, Koc M, Gocmen E, Aslar AK, Keskek M, Kilic M. Does technique alter quality of life after pilonidal sinus surgery? *Am J Surg.* 2005;190(3):388-92. doi: 10.1016/j.amjsurg.2004.08.068, PMID 16105524.
 13. Wolfe EM, Ainuz BY, Ragheb J, Wolfe SA. A simplified approach for surgical correction of vertical orbital dystopia: A 45 y retrospective cohort study. *Plast Reconstr Surg.* 2023. doi: 10.1097/PRS.00000000000010857, PMID 37337340.
 14. Topgül K. Surgical treatment of sacrococcygeal pilonidal sinus with rhomboid flap. *J Eur Acad Dermatol Venereol.* 2010;24(1):7-12. doi: 10.1111/j.1468-3083.2009.03350.x, PMID 19627408.
 15. Bascom J, Bascom T. Utility of the cleft lift procedure in refractory pilonidal disease. *Am J Surg.* 2007;193(5):606-9. doi: 10.1016/j.amjsurg.2007.01.008, PMID 17434365.
 16. Abdelrazeq AS, Rahman M, Botterill ID, Alexander DJ. Short-term and long-term outcomes of the cleft lift procedure in the management of nonacute pilonidal disorders. *Dis Colon Rectum.* 2008;51(7):1100-6. doi: 10.1007/s10350-008-9262-z, PMID 18470564.
 17. Bascom J, Bascom T. Utility of the cleft lift procedure in refractory pilonidal disease. *Am J Surg.* 2007;193(5):606-9. doi: 10.1016/j.amjsurg.2007.01.008, PMID 17434365.
 18. Bascom J, Bascom T. Failed pilonidal surgery: new paradigm and new operation leading to cures. *Arch Surg.* 2002;137(10):1146-51. doi: 10.1001/archsurg.137.10.1146, PMID 12361421.
 19. Mentess O, Bagci M, Bilgin T, Ozgul O, Ozdemir M. Limberg flap procedure for pilonidal sinus disease: results of 353 patients. *Langenbecks Arch Surg.* 2008;393(2):185-9. doi: 10.1007/s00423-007-0227-9, PMID 17899165.
 20. Basavaraju SM, KS, Vaggara HB. Different surgical approaches for pilonidal sinus-our experience in a peripherally located Tertiary Care Hospital. *J Med Sci Health.* 2021;7(1):52-5. doi: 10.46347/jmsh.2021.v07i01.009.
 21. Wadhawan DG, Sharma DD, Vyas DK. A comparative study of different treatment outcomes in cases of pilonidal disease. *Int J Surg Sci.* 2020;4(3):292-7. doi: 10.33545/surgery.2020.v4.i3e.511.
 22. Jeyalaksmi T, Priya ES. LimbergLimberg transposition flap in primary pilonidal sinus-a case series. *J Clin Diagn Res.* 2023;17(4):PR01-3. doi: 10.7860/JCDR/2023/63105.17759.