

NEUROREGENERATIVE EFFECTS OF D- α -TOCOPHEROL ON THE CRUSHED SCIATIC NERVE OF DIABETIC RATS

BIJO ELSY¹, AIJAZ AHMED KHAN^{1*}, VEENA MAHESHWARI²

¹Department of Anatomy, JN Medical College, Aligarh Muslim University, Aligarh, Uttar Pradesh, India. ²Department of Pathology, JN Medical College, Aligarh Muslim University, Aligarh, Uttar Pradesh, India. Email: aijazahmedkhan7@live.com

Received: 14 February 2017, Revised and Accepted: 21 February 2017

ABSTRACT

Objective: This present study is designed to explore the neuroregenerative effects of d- α -tocopherol on peripheral nerve in both healthy and diabetic rats.

Methods: 24 albino rats were divided into four groups; healthy control, diabetic control, healthy treated, and diabetic treated. Diabetes was induced by single subcutaneous injection of alloxan (100 mg/kg). Treated groups were administered d- α -tocopherol orally, daily (200 mg/kg) for 3 weeks. Through a mid-thigh incision, sciatic nerve was crushed with Kocher's forceps, and skin wound was closed with absorbable suture. Sciatic functional and static indices were used to assess the functional recovery in conjunction with histological, histomorphological, and biochemical analyses at the end of 3 weeks.

Results: It was noticed that d- α -tocopherol supplementation accelerates functional recovery, enhances the antioxidant levels, and promotes the regeneration and extracellular matrix reorganization of peripheral nerves.

Conclusion: It is concluded that the d- α -tocopherol appears to be an optimistic option in the management of peripheral nerve crush injury in both healthy and diabetics.

Keywords: Antioxidant, d- α -tocopherol, Diabetes, Rats, Regeneration, Sciatic nerve.

INTRODUCTION

Oxidative stress exacerbates the development and progress of diabetes and its complications and the vascular impairment which is commonly seen in diabetic neuropathy [1,2]. Reactive oxygen species (ROS) have been implicated for direct damage to the peripheral neurons while Schwann cells and antioxidant protection mechanisms are compromised in diabetes [3]. Therefore, antioxidants administration appears to be potentially attractive and clinically applicable neuroprotective agents against oxidative stress [4,5].

One of the most important aspects of treatments of diabetic neuropathy is to prevent or correct the ROS generation [2]. The antioxidant treatments are can be among the promising therapeutics that can prevent or correct reduced motor and sensory nerve conduction velocity in diabetic rats [6,7]. Since vitamin E has been claimed to play a central role in maintaining neurological structure and function [8], its possible use in both diabetes and regeneration of injured nerve appears logical.

Some recent studies, Khan *et al.* [9,10], have also revealed that the antioxidant vitamin C or steroids are able to reduce the post-injury nerve dysfunction and improve nerve regeneration of crushed sciatic nerve in healthy rats. Many other biomedical studies have also aimed to focus on the regeneration processes that occur during peripheral nerve reparation [11,12].

The assessment of peripheral nerve morphology is a pillar in the investigation of nerve damage and regeneration in tissue engineering [13], but limited data are available at present on the neuroregenerative effect of tocopherol isoforms on peripheral nerves. Therefore, the present study is focused to explore the potency of d- α -tocopherol on regeneration of crushed peripheral nerve in both healthy and diabetic rats using functional, histopathological, histomorphological, and biochemical parameters.

METHODS

24 albino rats of either sex each weighing 230-320 g were obtained from Central Animal House of JN Medical College, AMU, Aligarh. The study was approved by the Institutional Animal Ethical Committee (No. 8937/2014). This present study followed the same method as described in our previous study [14] regarding animal care, induction of diabetes, and monitoring of blood sugar level.

Experimental groups' route and dosage of treatment

Animals were divided into four groups having six rats in each group: (1) Healthy control - HC; (2) diabetic control - DC; (3) healthy d- α -tocopherol treated - HPT, and (4) diabetic d- α -tocopherol treated - DPT (200 mg/kg body weight, orally, daily for 3 weeks). d- α -Tocopherol myra E capsule (vitamin E) manufactured by PT Darya-Varia Laboratoria Tbk, Indonesia, imported and packed by United Laboratories, Inc., 66 United St, Philippines.

Surgical procedure

All animals received general anesthesia through inhalation of ether. Horizontal skin incision was made on the shaved right mid-thigh area. Crushed injuries were made on the sciatic nerve proximal to its division with Kocher's forceps by splitting the fascia between gluteus maximus and tensor fascia lata. The muscles were re-approximated, the overlying connective tissue and skin incision were closed with 3-0 Vicryl (2 metric-NW2401)-absorbable sterilized surgical needled suture USP (synthetic; braided coated polyglactin 910 violet; from Ethicon, manufactured in India by Johnson and Johnson Ltd., Aurangabad). Povidone-iodine solution (antiseptic) was applied on the wound and 0.5 ml Voveran (analgesic) and 2 mg single shot of Gentamycin (antibiotic) were also injected simultaneously [14].

Functional evaluation

a. Foot print analysis - Footprint analysis was performed at weekly interval. All experimental animals' feet were dipped in an ink solution

and they were permitted to walk down the track upon a strip of white paper. These foot prints were used to calculate the sciatic function index (SFI) and the sciatic static index (SSI).

- b. SFI - Calculation is based on Bain *et al.* [15]. The lengths of the third toe to its heel (PL), the first to the fifth toe (TS) and the second toe to the fourth toe (IT) were measured on the experimental side (E) and the opposite normal side (N) in each rat. SFI of each animal was calculated by the following formula:

$$SFI = [(-38.3 \times PLF) + (109.5 \times TSF) + (13.3 \times ITSF)] - 8.8$$
 Wherein different factors were calculated as under:

$$PLF = (EPL - NPL) / NPL; TSF = (ETS - NTS) / NTS; ITSF = (EIT - NIT) / NIT$$
- c. SSI - Calculation is based on Bain [16] by using the static factors, not considering the print length factor (PL), according to the equation:

$$SSI = [(108.44 \times TSF) + (31.85 \times ITSF)] - 5.49$$

In both SFI and SSI, an index score of zero was considered normal and an index of -100 indicated total impairment. When no footprints were measurable, the index score of -100 was given.

Sample collection and fixation of tissue

On completion of 3 weeks animals were sacrificed under deep ether anesthesia and then excised the crushed sciatic nerve. The excised nerves were immersion-fixed in 10% neutral buffered formalin. To assay the biochemical parameters, the method of serum preparation were followed as described in the previous study [14].

Gross examination

Daily observation was made to check for any autotomy or nibbling of toenails, edema, infections and ulcerations on the nerve crushed hind limb.

Histopathology and histomorphometry

Fixed nerves samples were processed for light microscopical studies. The 5 µm thick paraffin sections were stained with haematoxylin and eosin (H and E), Masson's trichrome (MT), aldehyde fuchsin with fast green, luxol fast blue with PicroSirus Red, periodic acid Schiff with haematoxylin and Verhoeff Van Gieson (VVG). Histomorphometry were performed on transverse sections stained with H and E, MT and VVG for counting the number of blood capillaries.

Biochemical estimation and analysis

Enzymatic antioxidant

Serum catalase was assayed by colorimetry as described [17]. The light absorbance of the sample was determined at 620 nm.

Non-invasive biomarker (oxidative stress parameter)

Serum total antioxidant capacity (TAC) was evaluated using ferric reducing antioxidant power assay [18]. The absorbance of sample was measured at 620 nm using photo colorimeter.

Statistical analysis

All the data were statistically evaluated and the significance calculated using one-way "ANOVA" followed by Tukeys test. All the results were expressed as mean±standard deviation and p<0.05 was considered as statistically significant.

RESULTS

Body weight and blood sugar level

After induction of diabetes the typical clinical manifestations of the diabetes such as polyphagia, polydipsia and polyuria were observed in diabetic groups.

Weight and blood sugar levels of all animals in each group were monitored at weekly intervals. Mean body weight in HC and treated groups (HPT and DPT) remained stable while DC group showed slight decrement at the end of study period. Mean blood sugar levels of healthy groups (HC and HPT) remained within normal limits while diabetic groups (DC and DPT) showed >450 mg/dl throughout the experimental period (Tables 1 and 2).

Gross observations

After sciatic nerve crushed injury, complete paralysis of the right side foot was observed in all rats (Fig. 1). Autotomy was prevented by the use of anti-nail-bite substance. Hence none of the rats showed autotomy or nibbling of toenails, edema, infection or ulceration on the foot.

After sciatic nerve crushed injury, complete paralysis of the right side foot was observed.

Functional analysis

On 3rd week the better footprints were observed in treated groups compared to control groups (Fig. 2). Both SFI and SSI mean values in DC showed total impairment, in HC values were significantly (p<0.01) more negative compared to treated groups (Fig. 3).

On 3rd week the better footprints were observed in treated groups compared to control groups.

Microscopic observations on 3rd week in longitudinal sections

1. Degenerating changes and fibrosis

The control groups showed increased vacuolization of nerve sheath and numerous atrophic fibres with histiocytes and degenerative

Table 1: Body weights (g) of the animals of all groups during the period of study (mean±SD)

Groups	Day 0	Day 7	Day 14	Day 21
HC	270±35.59	266.67±15.28	283.33±20.82	290±21.60
DC	277.5±25	247.5±17.08	235±23.80	227.5±22.17
HPT	260±33.17	250±21.60	286.25±18.87	293.33±20.82
DPT	267.5±29.86	240±20.5	257.5±17.08	272.5±22.17

The mean body weight in DC showed slight weight reduction while all other groups remained stable at the end of study period. SD: Standard deviation, HC: Healthy control, DC: Diabetic control, HPT: Healthy d-α-tocopherol treated, DPT: Diabetic d-α-tocopherol treated

Table 2: Blood sugar (mg/dl) of the animals of all groups during the period of study (mean±SD)

Groups	Day 0	Day 7	Day 14	Day 21
HC	146±28.21	124±19.98	160.67±18.01	167±17.06
DC	540.25±47.12	553±39.42	574.25±30.20	578±34.73
HPT	124±14.23	126.5±17.52	136±18.70	147.12±18.12
DPT	546.5±35.80	555.2±29.95	507.4±36.14	478.4±36.64

Note that the mean blood sugar levels of healthy groups (HC and HPT) remained within normal limits while the diabetic groups (DC and DPT) showed hyperglycemic state throughout the period of study. SD: Standard deviation, HC: Healthy control, DC: Diabetic control, HPT: Healthy d-α-tocopherol treated, DPT: Diabetic d-α-tocopherol treated

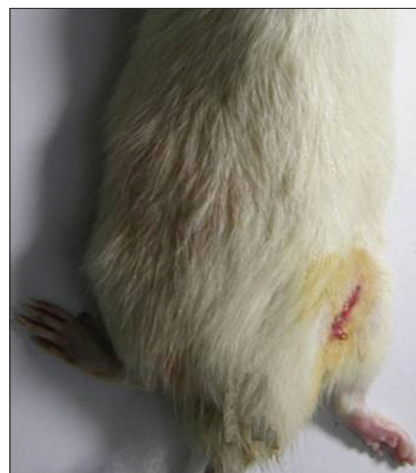

Fig. 1: Right foot after sciatic nerve crushed injury

debris whereas in treated groups had lesser vacuolization of nerve sheath and few atrophic fibres with histiocytes and degenerative debris (Fig. 4). More collagen fibres were observed in HC, these fibres were disorganized in DC whereas in treated groups these fibres were commonly arranged in an organized manner (Fig. 5).

2. Regenerating changes

a. Reappearance of elastin fibres:

The control groups were associated with fewer elastin fibres in the epineurium and absence of these fibres in the other connective tissue coverings whereas in treated groups these fibres were noticed in all three connective tissue coverings (Fig. 6).

b. Cellularity:

The HC showed moderate degree of infiltration of inflammatory cells and only few bands of Bungner (Fig. 7).

In DC bands of Bungner were deficient (Fig. 7) and marked pericapillary infiltration by inflammatory cells and presence of multinucleated giant cells with granuloma (Fig. 8a and b). Minimal infiltration of inflammatory cells and presence of bands of Bungner were observed in treated groups (Fig. 7).

c. Regenerated nerve fibres:

The HC had lesser number of thin nonmyelinated nerves whereas in DC only fragments of small nerve fibres were observed.

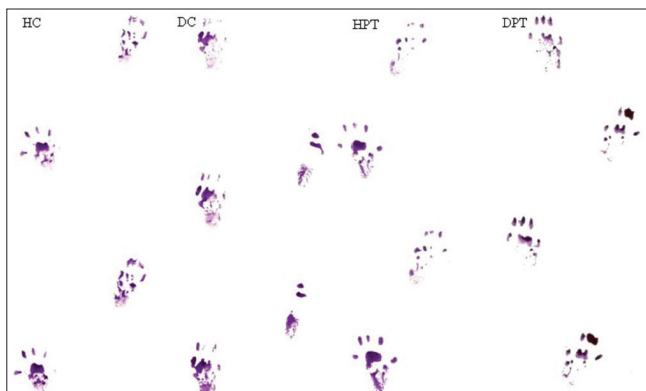


Fig. 2: Foot prints of all groups on 3rd week

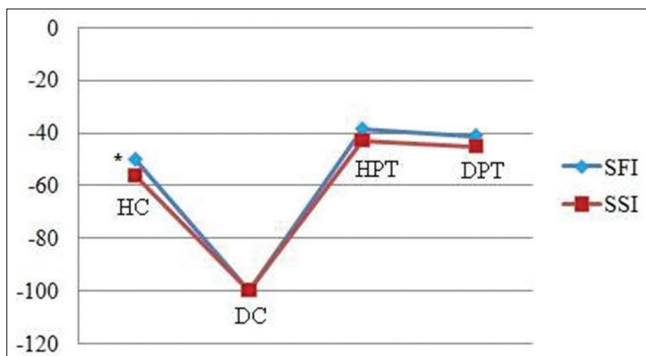


Fig. 3: Both sciatic function index and sciatic static index (SSI) values of all groups on 3rd week (mean±standard deviation).

Both sciatic function index and SSI mean values in diabetic control showed total impairment, in healthy control values were significantly (*p<0.01) more negative compared to treated groups

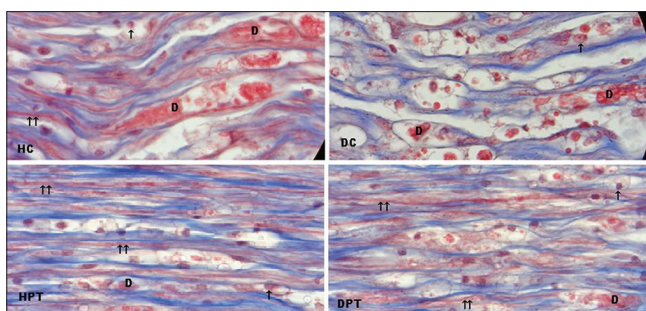


Fig. 4: Masson's trichrome stained sections showing degenerating changes on 3rd week. Arrows ↑ - Pointing the vacuolization of nerve sheath with histiocytes, ↑↑ - Nonmyelinated nerve fibres. D - Degenerative debris, at initial magnification ×1000

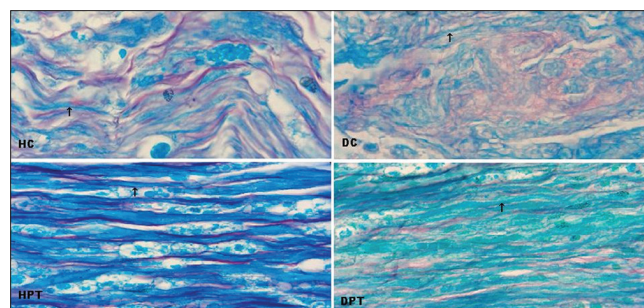


Fig. 5: Luxol fast blue with PicroSirus Red stained sections showing arrangements of collagen fibres. Arrangements of collagen fibres (red color) and arrow (↑) pointing the nerve fibres at initial magnification ×1000

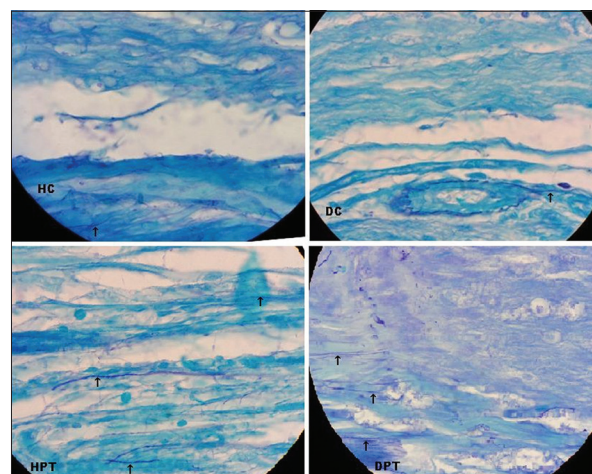


Fig. 6: Aldehyde fuchsin with fast green stained sections showing elastin fibres. Arrows (↑) pointing the presence of elastin fibres (Violet color) at initial magnification ×1000

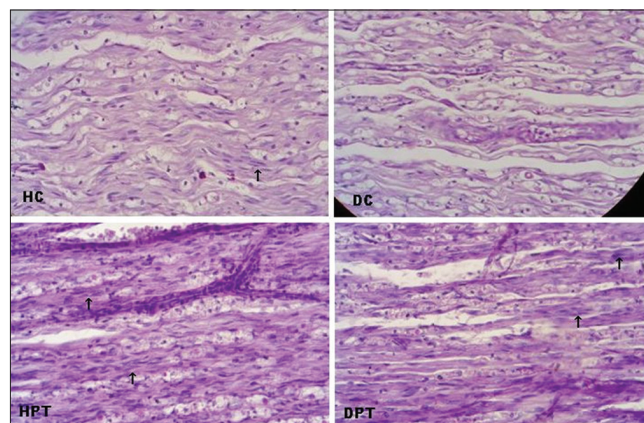


Fig. 7: Periodic acid Schiff with hematoxylin stained sections showing the bands of Bungner. Arrows (↑) pointing bands of Bungner at initial magnification ×400

Numerous nonmyelinated nerve fibres were noticed in treated groups (Figs. 4 and 5).

Histomorphometry

Neovascularization

On 3rd week, the transverse sections from HC and DC revealed that the mean values of number of capillaries were significantly ($p<0.05$, $p<0.01$) less compared to treated groups (Fig. 9). In addition the endoneurial arterioles' walls were more thickened in DC as compared to all other groups (Fig. 10).

Biochemical analysis on 3rd week

Enzymatic antioxidant and oxidative stress parameter

Serum catalase activity and TAC exhibited significant ($p<0.05$) reduction in DC as compared to HC. All serum analyses values improved significantly after supplementation of d- α -tocopherol in HPT as compared to all other study groups ($p<0.01$) and in DPT as compared to DC ($p<0.05$; Table 3).

DISCUSSION

In hyperglycemia, there is enhanced generation of ROS which is believed to cause neuronal damage and the development of diabetic neuropathy [2,19,20]. Nerve regeneration and functional recovery after peripheral nerve injury also remains a clinical challenge [21]. Vitamin E supplementation has been shown to have beneficial effects on diabetic neuropathy [22]. Axonotmesis, commonly seen in crush injury which causes severe sensorimotor impairments and functional disabilities [23] are therefore, also expected to get benefit from vitamin E supplement.

Since proper walking requires coordinated function involving sensory input, motor response and cortical integration [24,25], in this present study SFI and SSI have been used to evaluate the functional recovery of sciatic nerve after crushed injury. The SFI is a non-invasive method to assess the overall functional recovery of the sciatic nerve during the regeneration process. The SSI is claimed to be an effective and accurate method for the assessment of the functional recovery after sciatic nerve injury in rats [16]. Our results revealed that in treated groups the values of these indices were significantly less negative as compared to HC. In DC these indices values were more negative which indicates the total impairment. The functional motor recovery is slower in the presence of persistent hyperglycemia [26].

Histological parameters are the predictors of severity of peripheral nerve damage as well as that of the extent of regeneration [13,27].

On 3rd week the HC showed moderate degenerative changes whereas in DC presence of numerous atrophic fibres with histiocytes and increased vacuolization of nerve sheath indicates that the Wallerian degeneration is prerequisite for nerve regeneration and these degenerative changes were impaired in experimental diabetic rats [28-30]. Another study Khan [31] revealed that in Wallerian degeneration of optic nerve the degenerative debris was only partly removed even after 3 months. But in treated groups of the present study have shown most of the debris was removed on 3rd week. More deposition of collagen fibres were seen in control groups which is an indicator of more fibrosis [32] and these fibres were irregularly arranged in DC. Relatively lesser amount of collagen fibres arranged in parallel rows was noticed in the treated groups due to the effect of d- α -tocopherol for 3 weeks.

The viscoelastic properties of the peripheral nerve are thought to be due to its connective tissue supporting elements like elastin and collagen [33]. Elastin fibres are present in epineurium with thick and thin fibres, perineurium with thicker band of fibres and endoneurium with thinner fibres [34]. The control groups were associated with fewer elastin fibres only in the epineurium but in treated groups these fibres were predominantly in the epineurium and perineurium and smaller fibrils in the endoneurium. The endoneurial elastin fibres may provide

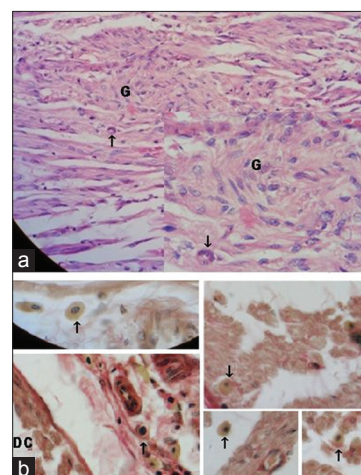


Fig. 8: Haematoxylin and eosin stained and Verhoeff Van Gieson (VGG) sections of diabetic control (DC). (a) Longitudinal sections of DC, arrow ↑ - Pointing multinucleated giant cell, G - Granuloma at initial magnification $\times 400$ and $\times 1000$ (inset). (b) VGG stained transverse sections ↑ - Pointing inflammatory cells at initial magnification $\times 1000$

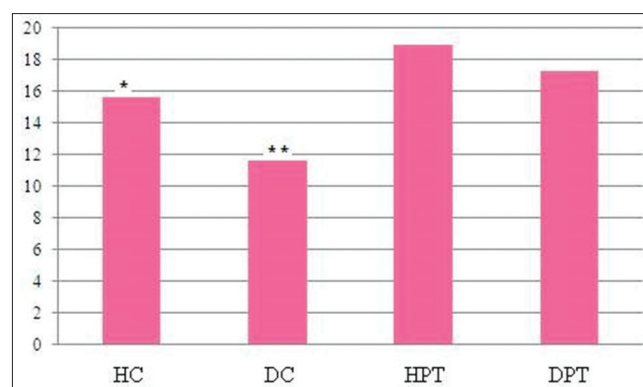


Fig. 9: Number of blood capillaries on 3rd week transverse sections (mean \pm standard deviation). Both control groups (Healthy control and diabetic control) the number of blood capillaries were significantly less (* $p<0.05$, ** $p<0.01$) less compared to treated groups

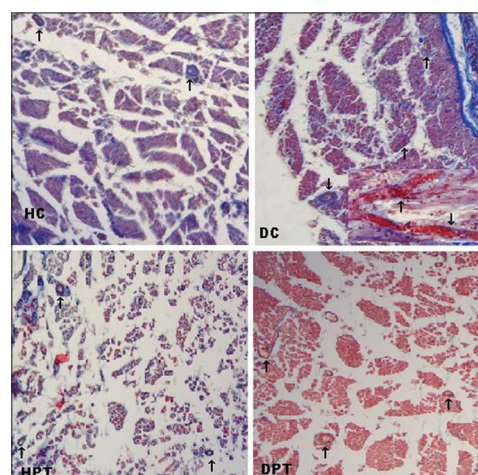


Fig. 10: Masson's trichrome stained sections showing blood capillaries. Transverse sections of all groups and longitudinal section of diabetic control (DC) (inset), arrow ↑ - Pointing blood capillaries at initial magnification $\times 200$ and $\times 400$ in DC longitudinal section

Table 3: Effects of d- α -tocopherol supplementation on biochemical parameters (mean \pm SD)

Groups	Catalase (u/ml)*	TAC (μ mol/L)
HC	0.0672 \pm 0.004	1285.5 \pm 67.18
DC	0.0438 \pm 0.005*	1000 \pm 67.88*
HPT	0.088 \pm 0.004	1481.3 \pm 78.02
DPT	0.066 \pm 0.006	1309.5 \pm 101.12

All biochemical parameters reveal significantly less in DC compared to all other groups (* p <0.05), *Catalase (u/ml) μ -mol of H₂O₂ utilised/mt. SD: Standard deviation, HC: Healthy control, DC: Diabetic control, HPT: Healthy d- α -tocopherol treated, DPT: Diabetic d- α -tocopherol treated, TAC: Total antioxidant capacity

sufficient force to produce the wave-like or unstretched position of the individual axons within the fascicle [34].

The HC showed moderate degree of inflammatory cells and only few proliferated Schwann cells organized as bands of Bungner [35]. The DC were associated severe infiltration of inflammatory cells especially around capillaries, presence of multinucleated giant cells with granuloma formation and the absence of Schwann cells' bands of Bungner. In treated groups only minimal inflammatory cells were seen, the proliferated Schwann cells and bands of Bungner were obvious which is provide supportive environment and direction for successful axonal regeneration [36].

In HC lesser number of thin newly regenerated nerve fibres was noticed indicating a partial regeneration of the nerve fibers [32] whereas only fragments of nerve fibres were seen in DC. Numerous thin nerve fibres were seen in treated groups, probably the fibres are in remodeling stage [37]. The regenerating units initially lack myelin even when the parent axon is a myelinated fiber. With time, these unmyelinated fibers become myelinated [38].

A prominent finding in diabetic neuropathy is the thickening of endoneurial arterioles due to increased deposition of basement membrane material [39], these features were observed in DC. Significantly less number of capillaries was observed in control groups compared to treated groups. Changes in capillary number and permeability and increased vascularization enhances successful axonal regeneration [40].

Catalase is a preventive antioxidant which inhibits the initial production of free radicals and removes the excess H₂O₂ [41]. The present study showed that the serum catalase activity value was lower in DC this is in agreement with other studies [42-44] that conducted in plasma and brain tissues of rats. This activity was normalizing in control group after vitamin E treatment [43]. The 3 weeks administration of d- α -tocopherol helps to increase the serum catalase activity in treated groups [14].

The antioxidant capacity of plasma is the primary measure and marker to evaluate the status and potential of oxidative stress in the body [45]. The present work observed that serum total antioxidant level in DC was significantly lower (p <0.05) compared to HC is in agreement with the findings of other study [46]. Improved serum antioxidant capacity was observed in treated groups by administration of d- α -tocopherol for 3 weeks [14].

CONCLUSION

Based on the findings of the present study it is concluded that the d- α -tocopherol supplementation accelerates functional recovery, enhances the antioxidant levels, promote the extracellular matrix reorganization and regeneration of peripheral nerve after crush-injury. Therefore in both healthy and diabetic conditions, the d- α -tocopherol appears to be a beneficial therapeutic nutritional supplement in the management of peripheral nerve injury.

ACKNOWLEDGMENTS

All kinds of support availed from the Department of Anatomy, JN Medical College, Aligarh Muslim University is gratefully acknowledged.

REFERENCES

- Sireesha K, Rao SP. Oxidative stress and diabetes: And overview. Asian J Pharm Clin Res 2015;8:15-9.
- Bin-Jaliah I, El-Attar S, Khaleel EF, El-Sayed LA, Haidara MA. Remedial effects of vitamin e and l-arginine on peripheral neuropathy in streptozotocin-induced diabetic rats. Am J Pharmacol Toxicol 2014;9:13-23.
- Negi G, Kumar A, Kaundal RK, Gulati A, Sharma SS. Functional and biochemical evidence indicating beneficial effect of melatonin and nicotinamide alone and in combination in experimental diabetic neuropathy. Neuropharmacology 2010;58(3):585-92.
- Merenda A, Bullock R. Clinical treatments for mitochondrial dysfunctions after brain injury. Curr Opin Crit Care 2006;12(2):90-6.
- Lalkovicová M, Danielisová V. Neuroprotection and antioxidants. Neural Regen Res 2016;11(6):865-74.
- Cotter MA, Love A, Watt MJ, Cameron NE, Dines KC. Effects of natural free radical scavengers on peripheral nerve and neurovascular function in diabetic rats. Diabetologia 1995;38(11):1285-94.
- Cameron NE, Cotter MA, Horrobin DH, Tritschler HJ. Effects of alpha-lipoic acid on neurovascular function in diabetic rats: Interaction with essential fatty acids. Diabetologia 1998;41(4):390-9.
- Sen CK, Khanna S, Roy S. Tocotrienol: The natural vitamin E to defend the nervous system? Ann N Y Acad Sci 2004;1031:127-42.
- Khan AA, Ajmal M, Faizal MP, Elsy B, Faruqi NA. Effects of vitamin C on regeneration of sciatic nerve crush injury in adult rats - A light microscopic study. J Int Acad Res Multidiscip 2015;3:68-77.
- Khan AA, Faruqi NA, Ansari MS. Effects of hydrocortisone on the sciatic nerve crushes injury in adult rat - A light microscopic study. Curr Neurobiol 2014;5:11-6.
- Chalfoun CT, Wirth GA, Evans GR. Tissue engineered nerve constructs: Where do we stand? J Cell Mol Med 2006;10(2):309-17.
- Jiao H, Yao J, Yang Y, Chen X, Lin W, Li Y, et al. Chitosan/polyglycolic acid nerve grafts for axon regeneration from prolonged axotomized neurons to chronically denervated segments. Biomaterials 2009;30(287):5004-18.
- Vleggeert-Lankamp CL. The role of evaluation methods in the assessment of peripheral nerve regeneration through synthetic conduits: A systematic review. Laboratory investigation. J Neurosurg 2007;107(6):1168-89.
- Elsy B, Maheshwari V, Khan AA. Effects of d- α -tocopherol on progression of reepithelialization, matrix remodeling and appearance of epidermal appendages in secondary skin wounds of diabetic rats. J Dermatol Clin Res 2016;4:1081-7.
- Bain JR, Mackinnon SE, Hunter DA. Functional evaluation of complete sciatic, peroneal, and posterior tibial nerve lesions in the rat. Plast Reconstr Surg 1989;83(1):129-38.
- Bervar M. Video analysis of standing - An alternative footprint analysis to assess functional loss following injury to the rat sciatic nerve. J Neurosci Methods 2000;102(2):109-16.
- Sinha AK. Colorimetric assay of catalase. Anal Biochem 1972;47(2):389-94.
- Benzie IF, Strain JJ. The ferric reducing ability of plasma (FRAP) as a measure of "antioxidant power": The FRAP assay. Anal Biochem 1996;239(1):70-6.
- Hawkins CL, Davies MJ. Generation and propagation of radical reactions on proteins. Biochim Biophys Acta 2001;1504(2-3):196-219.
- Baydas G, Sonkaya E, Tuzcu M, Yasar A, Donder E. Novel role for gabapentin in neuroprotection of central nervous system in streptozotocine-induced diabetic rats. Acta Pharmacol Sin 2005;26(4):417-22.
- Fan L, Yu Z, Li J, Dang X, Wang K. Schwann-like cells seeded in acellular nerve grafts improve nerve regeneration. BMC Musculoskelet Disord 2014;15:165.
- Algaidi S. The effect of antioxidants on experimentally induced diabetic peripheral neuropathy in adult male albino rats. J Am Sci 2011;7:671-7.
- Navarro X, Vivó M, Valero-Cabrè A. Neural plasticity after peripheral nerve injury and regeneration. Prog Neurobiol 2007;82(4):163-201.
- Sarikcioglu L, Demirel BM, Utuk A. Walking track analysis: An assessment method for functional recovery after sciatic nerve injury in the rat. Folia Morphol (Warsz) 2009;68(1):1-7.

25. de Medinaceli L, Freed WJ, Wyatt RJ. An index of the functional condition of rat sciatic nerve based on measurements made from walking tracks. *Exp Neurol* 1982;77(3):634-43.
26. Malysz T, Ilha J, Nascimento PS, De Angelis K, Schaan BD, Achaval M. Beneficial effects of treadmill training in experimental diabetic nerve regeneration. *Clinics (Sao Paulo)* 2010;65(12):1329-37.
27. Castro J, Negrodo P, Avendaño C. Fiber composition of the rat sciatic nerve and its modification during regeneration through a sieve electrode. *Brain Res* 2008;1190:65-77.
28. Terada M, Yasuda H, Kikkawa R. Delayed Wallerian degeneration and increased neurofilament phosphorylation in sciatic nerves of rats with streptozocin-induced diabetes. *J Neurosci* 1998;155(1):23-30.
29. Terada M, Yasuda H, Kogawa S, Maeda K, Haneda M, Hidaka H, et al. Expression and activity of cyclin-dependent kinase 5/p35 in adult rat peripheral nervous system. *J Neurochem* 1998;71(6):2600-6.
30. Yasuda H, Terada M, Maeda K, Kogawa S, Sanada M, Haneda M, et al. Diabetic neuropathy and nerve regeneration. *Prog Neurobiol* 2003;69(4):229-85.
31. Khan AA. Wallerian degeneration in the optic nerve of the rabbit. *Cells Tissues Organs* 2004;177(2):104-9.
32. Breshah MN, Sadakah AA, Eldrieny EA, Saad KA. Functional and histological evaluation of rat sciatic nerve anastomosis using cyanoacrylate and fibrin glue. *Tanta Dent J* 2013;10:67-74.
33. Sunderland S. *Nerves and Nerve Regeneration*. 2nd ed. Edinburgh: Livingstone; 1978.
34. Tassler PL, Dellon AL, Canoun C. Identification of elastic fibres in the peripheral nerve. *J Hand Surg Br* 1994;19(1):48-54.
35. Pfister BJ, Gordon T, Loverde JR, Kochar AS, Mackinnon SE, Cullen DK. Biomedical engineering strategies for peripheral nerve repair: Surgical applications, state of the art, and future challenges. *Crit Rev Biomed Eng* 2011;39(2):81-124.
36. Grinsell D, Keating CP. Peripheral nerve reconstruction after injury: A review of clinical and experimental therapies. *BioMed Res Int* 2014;2014:13.
37. Sanchez EC. Hyperbaric oxygenation in peripheral nerve repair and regeneration. *Neurol Res* 2007;29(2):184-98.
38. Flores AJ, Lavernia CJ, Owens PW. Anatomy and physiology of peripheral nerve injury and repair. *Am J Orthop (Belle Mead NJ)* 2000;29(3):167-73.
39. Agamanolis DP. *Neuropathy, An illustrated interactive course for medical students and residents*. Chapter 12, peripheral nerve pathology 2014;1-2.
40. Hobson MI. Increased vascularisation enhances axonal regeneration within an acellular nerve conduit. *Ann R Coll Surg Engl* 2002;84(1):47-53.
41. Vasudevan DM, Sreekumari S. *Textbook of Biochemistry (For Medical Students)*. 4th ed. New Delhi: Jaypee Publication; 2005. p. 340-1.
42. Jeyashanthi N, Ashok V. Anti-oxidative effect of *Cassia auriculata* on streptozotocin induced diabetic rats. *Indian J Clin Biochem* 2010;25(4):429-34.
43. Shirpoor A, Ansari MH, Salami S, Pakdel FG, Rasmi Y. Effect of vitamin E on oxidative stress status in small intestine of diabetic rat. *World J Gastroenterol* 2007;13(32):4340-4.
44. Shelat DY, Acharya SR. Neuroprotective activity of novel cur-ca-thione and its oxidative stress study. *Int J Pharm Pharm Sci* 2016;8:167-73.
45. Brahm KT, Kanti BP, Abidi AB, Ibrahim RS. Markers of oxidative stress during diabetes mellitus. *J Biomark* 2013;2013:3.
46. Nakhaee A, Bokaeian M, Saravani M, Farhangi A, Akbarzadeh A. Attenuation of oxidative stress in streptozotocin-induced diabetic rats by *Eucalyptus globulus*. *Indian J Clin Biochem* 2009;24(4):419-25.