

Original Article

HEPATOPROTECTIVE ACTIVITY OF SPHAERANTHUS AMARANTHOIDES WHOLE PLANT IN PARACETAMOL INDUCED HEPATOTOXICITY IN RATS

RADHAKRISHNAN GOWRI*, VARADHARAJAN MADHAVAN, SUNKAM YOGANARASIMHAN

Department of Pharmacognosy, Faculty of Pharmacy, M. S. Ramaiah University of Applied Sciences, Bangalore, Karnataka 560054
Email: gowrijp@gmail.com

Received: 28 Feb 2015 Revised and Accepted: 15 Jun 2015

ABSTRACT

Objective: To evaluate the protective effect of ethanol extract of whole plant of *Sphaeranthus amaranthoides* against paracetamol induced hepatotoxicity in albino wistar rats.

Methods: Liver damage was induced by administration of paracetamol orally at a dose of 2 g/kg body weight. Protective effect of the extract was determined by assessing the levels of serum enzymes like AST, ALT, ALP, total protein, total bilirubin, liver Malondialdehyde and glutathione levels. The extract was standardized by HPTLC method.

Results: Administration of ethanol extract at 400 mg/kg b. wt showed significant (***) reduction in elevated serum enzyme levels compared to paracetamol induced animals. Paracetamol induced liver toxicity decreased the liver glutathione level and increased the MDA level. The results of our study showed that ethanol extract at 400 mg/kg significantly increased glutathione content and decreased the MDA level indicating the protective role of *Sphaeranthus amaranthoides* ethanol extract against paracetamol induced liver toxicity.

Conclusion: *Sphaeranthus amaranthoides* whole plant possesses potent hepatoprotective activity against paracetamol induced hepatotoxicity.

Keywords: *Sphaeranthus amaranthoides*, Hepatoprotective, Paracetamol, Biochemical parameters, Lipid peroxidation.

INTRODUCTION

Paracetamol is one of the common Over the Counter (OTC) drug widely used as analgesics. It shows hepatotoxicity at higher doses. Paracetamol overdoses may cause mitochondrial dysfunction due to the covalent binding with mitochondrial proteins and results in insufficient mitochondrial respiration and ATP synthesis. Ninety percent of paracetamol is metabolized into phenolic glucuronide and sulfate by glucuronyltransferase and sulfotransferase.

Nearly 5 to 10 % is metabolized in to N-acetyl-*p*-benzoquinoneimine (NAPQI) by cytochrome P₄₅₀ (preferably by the enzyme CYP2E1). NAPQI forms covalent bonds with cellular macromolecules and affects the general cellular structure and function, leading to liver damage [1].

In traditional systems of medicine, many plants have been used for the treatment and control of liver disorders [2, 3]. Phytoconstituents derived from plants have gained much importance recently due to its diversified biological and pharmacological properties including antioxidant and hepatoprotective activity. Despite extensive research, to identify a drug in the modern medicine to cure liver disorders Silymarin a natural flavonoid from *Silybum marianum* (L.) Gaertn is the drug of choice to cure liver disorders [4]. Hence extensive research has been carried out to identify hepatoprotective agents from medicinal plants.

Sphaeranthus amaranthoides Burm. f belonging to Asteraceae is a fragrant herb distributed in moist places throughout the plains of Southern India. *Sphaeranthus amaranthoides* is considered as a substitute for the drug Munditika in Ayurveda [5], the accepted source for which is *Sphaeranthus indicus* Linn [6, 7]. The plant is also used in the Siddha system of medicine and referred as Sivakaranthai [5]. Munditika is traditionally used to treat various diseases like jaundice (*kamala*), fever (*jwara*), epilepsy (*apasmara*), gastric disorders (*udararoga*) and painful swellings (*sotha*) [8]. Antioxidant and wound healing [9] activity has been reported for *S. amaranthoides*. However no work has been reported on the hepatoprotective activity of whole plant of *S. amaranthoides* against paracetamol induced liver toxicity in rats, though some work has been carried out on D-galactosamine induced hepatitis in rats [10].

MATERIALS AND METHODS

Collection of plant material

The whole plant of *S. amaranthoides* in flowering condition was collected from Komaneri village of Thuthukudi district; Tamil Nadu in January 2011. The collected plant material was identified and authenticated by Dr. S. N. Yoganarasimhan, Taxonomist and Research coordinator, Faculty of Pharmacy, M. S. Ramaiah University of Applied Sciences, Bangalore. Taxonomic identification was carried out using available literature [11]. A voucher herbarium specimen (Gowri 044) has been deposited in the Department of Pharmacognosy, Faculty of Pharmacy, M. S. Ramaiah University of Applied Sciences, Bangalore along with the sample of crude drug. The plant material was thoroughly washed with water to remove the adhering dirt and sandy material, cut into small pieces and shade dried.

Chemicals and reagents

Paracetamol was procured from Yarrow Chem Products, Mumbai, India. HPTLC plates were obtained from MERCK, Germany. All the other reagents and solvents used were of analytical grade.

Preparation of ethanol extract

Coarsely powdered whole plant material (100 g) was extracted with 95% (V/V) alcohol using soxhlet apparatus. The extract was filtered and concentrated using rotary evaporator under reduced temperature.

Preliminary phytochemical screening

The Preliminary phytochemical screening of ethanol extract was carried out following standard methods [12-15].

HPTLC fingerprint studies for flavonoids

HPTLC analysis was performed using Camag HPTLC system equipped with Linomat V applicator and a TLC scanner 3, equipped with WinCATS-4 software. Documentation of the developed chromatogram was done by using CAMAG Reprostar 3 with 12bit CCD camera, controlled by WinCATS-4 software. A precoated aluminium plate with silica gel 60F254 (10×10) was used as stationary phase. Ethanol extract (5 mg/ml) was prepared by dissolving the extract in methanol and 4 µl was applied on the plate using Camag micro syringe of 100 µl

capacities. The plates were developed using CHCl_3 : Methanol (90:10) as mobile phase [16] in a Camag twin trough chamber to a distance of 9 cm each, the plate was scanned at 365 nm.

Experimental animals

Healthy Albino rats (Wistar strain) of either sex (170–200 g) were used for the study. The animals were bred and maintained in the animal house of Faculty of Pharmacy, M. S. Ramaiah University of Applied Sciences, Bangalore. Animal house was well maintained under standard hygienic conditions, at room temperature and humidity ($60 \pm 10\%$) with 12 h day and night cycle. The animals were provided with standard pellet diet and water *ad libitum*. The study was approved by the Institutional Animal Ethical Committee (IAEC certificate no. MSRCP/P-10/2010).

Acute toxicity studies

Female Albino rats of Wistar strain in the weight range 170–200 g were used for acute toxicity studies. The animals were fasted overnight and administered with a dose up to 2000 mg/kg body weight and observed for any behavioral and neurological changes for first 2 hrs and for any toxicity or mortality for 72 hrs [17, 18].

Experimental protocol

Liver damage was induced by administration of Paracetamol orally at the dose of 2 g/kg b. wt [19]. The animals were divided into 5 groups of 6 animals each. Group I was maintained as normal control and administered 10% Tween 80 solution (1 ml/kg b. w., p. o) once daily for 5 d. Group II was maintained as positive control and administered with paracetamol (2 g/kg b. wt, p. o) on 2nd and 3rd day. Group III was administered with standard Silymarin (100 mg/kg b. wt. p. o) once daily for 5 days and paracetamol (2 g/kg b. wt, p. o) on 2nd and 3rd day, 30 min after Silymarin administration. Group IV & V were administered ethanol extract at a dose of 200 & 400 mg/kg, once daily for 5 days and were administered with paracetamol (2 g/kg b. wt, p. o) on 2nd and 3rd day, 30 min after extracts administration. On 6th day, 18 h after the last dose of paracetamol, all the animals were anaesthetized for collection of blood from retro-orbital plexus.

Separation of serum and estimation of biochemical parameters

The blood was collected from the retro-orbital plexus using a heparinized capillary tube. Blood was allowed to stand for 30 min to clot and serum was separated by centrifugation at 10000 rpm for 10 min. The separated serum was used for the estimation of SGPT (ALT), SGOT (AST), alkaline phosphatase, total proteins, total bilirubin, total cholesterol and triglycerides. The biochemical parameters were estimated by using a Semi-automatic B4B[®] Diagnostic Division Chemistry Analyzer CA-2005, using diagnostic kits obtained from Agappe Diagnostic Ltd, Kerala.

Isolation of liver

The animals were sacrificed by excess of ether anaesthesia; liver was carefully removed and washed with ice cold saline solution. A portion of liver was preserved in 10% neutral formalin for histopathological studies.

Preparation of liver homogenate and estimation of liver enzymes level

Liver homogenates were prepared in 0.15M Potassium chloride for estimation of Malondialdehyde and in phosphate buffer pH (7.4) for estimation of glutathione. The MDA [20, 21] and reduced glutathione levels [22] in liver tissues were determined.

Statistical analysis

Data were expressed as mean \pm SEM values and tested with One Way Analysis of Variance (ANOVA) followed by Tukey-Kramer Multiple comparison test. Values were considered statistically significant with $P < 0.001$.

RESULTS

Preliminary Phytochemical screening

The ethanol extract obtained was a dark green semisolid mass with a yield of 5.25 % w/w. The studies showed the presence of alkaloids,

carbohydrates, phenolic compounds like tannins & flavonoids, saponins and proteins.

HPTLC studies

Phenolic compounds like flavonoids are reported to possess hepato protective activity and hence HPTLC for flavonoids is undertaken in this study.

The HPTLC analysis of ethanol extract for flavonoids at 365 nm revealed 12 phyto constituents having R_f values 0.03, 0.08, 0.15, 0.18, 0.23, 0.27, 0.42, 0.57, 0.74, 0.84, 0.91, 0.98 out of which spots with R_f values 0.06, 0.27, 0.57, 0.74, 0.91 are prominent when compared to other spots.




Fig. 1: Chromatogram of ethanol extract of *S. amaranthoides* at 365 nm for flavonoids

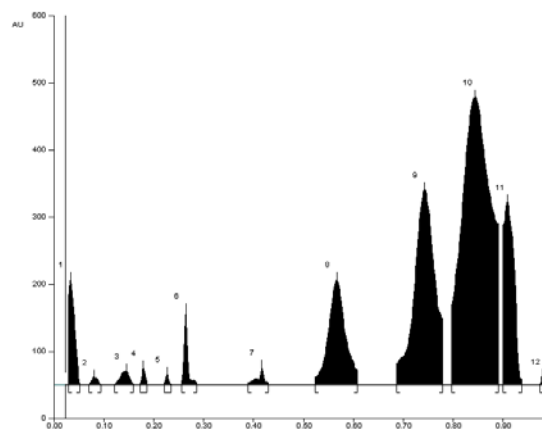


Fig. 2: HPTLC finger print profile of ethanol extract of *S. amaranthoides* at 365 nm

Hepatoprotective studies

Acute toxicity studies of ethanolic extract of *Sphaeranthus amaranthoides* did not show any mortality or toxic symptoms up to 2000 mg/kg b. wt. Hence, 1/5th and 1/10th of the highest dose tested is fixed as the dose for further pharmacological activity. Table 1 and 2 shows the elevated level of AST, ALT, ALP, total bilirubin, total cholesterol and triglycerides in animals treated with paracetamol (2 g/kg body weight) which is indicative of severe liver necrosis. Administration of ethanolic extract at the doses of 200 and 400 mg/kg remarkably prevented paracetamol induced hepatotoxicity in a dose dependent manner. There was a significant ($P < 0.001$) restoration of these enzyme levels on administration of ethanolic extract.

Table 1: Effect of ethanol extract of *S. amaranthoides* on biochemical parameters in paracetamol intoxicated rats

Group	AST(U/l)	ALT(U/l)	ALP(U/l)	TP(g/dl)
Normal control (Tween 80)	71.61±5.43	35.49±9.96	32.56±1.43	6.78±0.87
Positive control (Paracetamol induced)	365.63±29.18	125.80±20.93	100.42±0.09	3.08±0.03
Silymarin(100 mg/kg)	112.21±4.23***	56.85±1.56***	39.87±0.18***	6.18±0.19***
Ethanol extract (200 mg/kg)	253.78±10.41***	98.15±0.728 ^{ns}	72.11±4.12 ^{ns}	3.84±0.19**
Ethanol extract (400 mg/kg)	205.45±11.50***	65.62±3.20***	57.08±14***	5.54±0.37***

All values are expressed as mean±SEM, One way Anova followed by Tukey Kramer multiple comparison test (n = 6). The significance on comparison with positive control group ***P<0.001, ** P<0.01,^{ns}P>0.05.

Table 2: Effect of ethanol extract of *S. amaranthoides* on serum levels of total bilirubin, TC and TG in paracetamol intoxicated rats

Group	TB (mg/dl)	TC (mg/dl)	TG (mg/dl)
Normal control	0.172±0.002	82.06 C±28.53	112.2±34.27
Positive control	1.234±0.08	318.57±25.35	248.35±61.42
Silymarin(100 mg/kg)	0.321±0.032***	183.43±5.023***	159.07±5.20***
Ethanol extract (200 mg/kg)	1.001±0.031 ^{ns}	230.43±11.87***	201.68±4.64*
Ethanol extract (400 mg/kg)	0.712±0.023***	190.64±9.31***	175.71±6.16***

All values are expressed as mean±SEM, One way Anova followed by Tukey Kramer multiple comparison test (n = 6). The significance on comparison with positive control group ***P<0.001, * P<0.05,^{ns}P>0.05.

Since oxidative stress is one of the causes for paracetamol induced hepatotoxicity, liver antioxidant enzymes like GSH and MDA levels were measured [23]. Table 3 shows a reduction in the level of reduced glutathione in liver tissue of paracetamol intoxicated rats, but pretreatment with 400 mg/kg of the extract significantly (**P<0.001) increased the GSH level in the liver tissue. Further

there was a significant increase in MDA level in paracetamol induced group when compared to the normal group, indicating the extent of lipid peroxidation. This was significantly (P<0.001) decreased in animals treated with 400 mg/kg of ethanol extract indicating the protective role of ethanol extract against paracetamol induced toxicity.

Table 3: Effect of ethanol extract of *S. amaranthoides* on contents of MDA and GSH in liver homogenates of paracetamol intoxicated rats

Group	GSH(nmoles/100 mg tissue)	MDA (nmoles/100 mg tissue)
Normal control	46.34±2.413	0.287±0.094
Positive control	24.34±0.758	0.902±0.044
Silymarin(100 mg/kg)	47.68±1.223***	0.348±0.021***
Ethanol extract (200 mg/kg)	30.59±1.038*	0.529±0.031***
Ethanol extract (400 mg/kg)	41.26±0.678***	0.404±0.020***

All values are expressed as mean±SEM, One way Anova followed by Tukey Kramer multiple comparison test (n = 6). The significance on comparison with positive control group ***P<0.001, * P<0.05

Histopathological study

Fig. 3 shows the histopathology of livers of animals treated with paracetamol and ethanol extract. Histopathological profile of liver of control animals showed normal perivenular, periportal and midzonal hepatocytes (fig. 3.1). Liver section of animals treated with paracetamol showed distorted liver architecture with more hepatocytes showing degenerative changes and necrosis (fig. 3.2). The liver section of animals treated with 200 mg/kg of ethanol extract showed distorted architecture. The periportal region shows inflammatory infiltration and some of the sinusoids appear disrupted (fig. 3.4), whereas liver section of animals treated with 400 mg/kg dose showed intact architecture with normal sinusoids (fig. 3.5). The above results confirmed the hepato protective effect of ethanol extract of whole plant of *S. amaranthoides* in paracetamol induced hepatotoxicity in rats.

DISCUSSION

Paracetamol, a widely used analgesic and antipyretic drug, produces acute liver damage at higher doses. Acetaminophen induced hepatotoxicity is one of the main cause for acute liver failure (ALF)[24]. Acute paracetamol poisoning is now most common cause

of liver failure in many developed countries like UK, US, Australia and Canada [25, 26]. Overdose of paracetamol causes necrosis of the centrilobular hepatocytes characterized by nuclear pyknosis and eosinophilic cytoplasm followed by large excessive hepatic lesion. The covalent binding of N-acetyl-P-benzo quinoneimine, an oxidative product of paracetamol to sulphhydryl group of protein result in lipid peroxidative degradation of glutathione level and thereby produces cell necrosis in the liver [27, 28]. Hepatic cellular damage may result in leakage of enzymes like Alanine aminotransferase (ALT) and aspartate amino-transferase (AST) into the blood, which can be measured as indicators of cell damage. Their levels are markedly elevated in hepatitis and other acute liver damage. ALT level is most commonly used to determine hepatic damage than AST. In the present study, hepato protective activity of ethanol extract of whole plant of *S. amaranthoides* at doses 200 and 400 mg/kg was assessed by measuring the level of various serum enzymes like AST, ALT, ALP, TP and TB. However, treatment with 200 and 400 mg/kg of ethanolic extract of *S. amaranthoides* significantly reduced the elevated levels of AST, ALT, ALP, total bilirubin, total cholesterol and triglycerides (**P<0.001) when compared with the paracetamol intoxicated group.

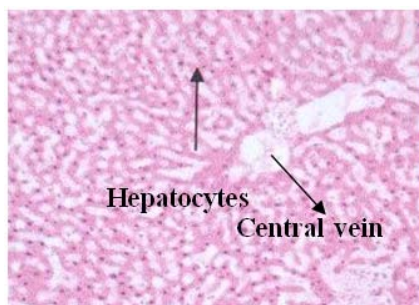


Fig. 3.1: Normal control (x100)

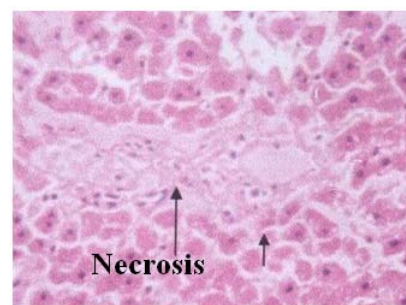


Fig. 3.2: Positive control (x400)

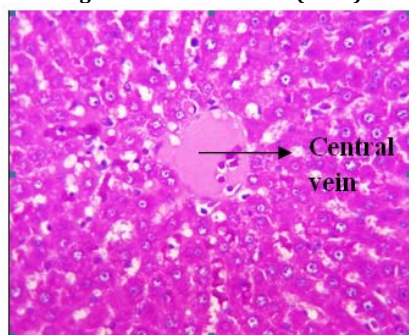


Fig. 3.3: Standard group (x400)

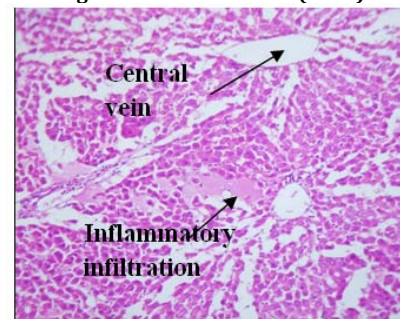


Fig. 3.4: Ethanol extract 200 mg/kg(x100)

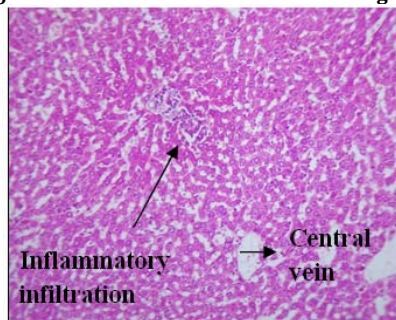


Fig. 3.5: Ethanol extract 400 mg/kg (x100)

Fig. 3: Histopathological sections of livers of animals treated with paracetamol and ethanol extract of *S. amaranthoides*

The mechanism of increased ROS and RNS in paracetamol induced liver toxicity has been reported extensively. At safe dose level the metabolite of paracetamol was efficiently detoxified by glutathione (endogenous antioxidant) forming an acetaminophen-glutathione conjugate. However, at toxic doses the metabolite depletes the hepatic glutathione by 80–90% [29]. Lipid peroxidation is a complex process by which poly-unsaturated fatty acids in cellular membranes undergo reaction with oxygen resulting in formation of alkenals, alkanals, hydroxy alkenals and Malondialdehyde (MDA). Malondialdehyde is a secondary product of lipid peroxidation, which can be used as an index to measure the extent of lipid peroxidation. There was a significant increase in MDA level and reduction in the level of reduced glutathione in liver tissue of paracetamol intoxicated group ($P < 0.001$) as compared to normal control. Pretreatment with 200 and 400 mg/kg of ethanol extract of *S. amaranthoides* significantly reduced the lipid peroxide MDA content and increased the GSH level in the liver tissue (** $P < 0.001$). Histopathological reports of the liver samples also support the protective role of *S. amaranthoides*.

Hepatoprotective activity of ethanol extract of *S. amaranthoides* in D-galactosamine induced hepatitis in rats has been reported by Swarnalatha *et al.* In their study the protective role of ethanol extract of *S. amaranthoides* was assessed by measuring the levels of serum and liver enzymes. D-galactosamine induced liver damage resembles viral hepatitis [30] and the hepato necrotic process may involve different pathogenic mechanism such as inhibition of RNA synthesis [31], free radical dependant pathway [32] and

modification of phospholipid composition of mitochondria membrane [33]. Ethanolic extract significantly ($P < 0.001$) reduced the elevated levels of ALT, AST and ALP and increased the reduced glutathione level in the liver tissues of D-galactosamine intoxicated rats. The findings of our present study correlates with the reported D-galactosamine induced liver toxicity. Since the plant is effective in scavenging the free radicals generated by both D-galactosamine and paracetamol induced liver toxicity, *S. amaranthoides* can be effectively used to treat drug induced hepatotoxicity. This hepatoprotective activity study substantiates the use of *S. amaranthoides* in Ayurveda as an alternate source for the drug, Munditika.

The phytochemical screening and the HPTLC analysis of the ethanol extract showed the presence of phenolic compounds like flavonoids and tannins. Several studies have correlated the hepatoprotective potential of plants with the presence of flavonoids [34]. Hence the protective role of *S. amaranthoides* in paracetamol induced hepatotoxicity may be due to the presence of these secondary metabolites.

CONCLUSION

The result of the present study indicates that the ethanol extract of *S. amaranthoides* whole plant possesses hepatoprotective activity against paracetamol induced hepatotoxicity. This study supports the traditional use of *S. amaranthoides* as an alternate source for *S. indicus* which is used for the treatment of *kamala* (Jaundice) in Ayurveda.

ACKNOWLEDGEMENT

The authors are thankful to Dr. V. Chelladurai for helping in the collection of authentic plant material and also to Gokula Education Foundation, Bangalore for providing facilities to carry out the research work.

CONFLICT OF INTERESTS

Declared None.

REFERENCES

- Linda BS, Myron JT, Ronald WB, Jonathan RH. Acetaminophen hepatotoxicity and acute liver failure. *J Clin Gastroenterol* 2009;43:342-9.
- Visen PK, Shukla B, Patnaik GK, Dhawan BN. Andrographolide protect rat hepatocytes against paracetamol-induced damage. *J Ethnopharmacol* 1993;40:131-6.
- Panchabai TS, Ambarkhane SV, Joshi AS, Samant BD, Rege NN. Protective effect of *Tinospora cordifolia*, *Phyllanthus emblica* and their combination against antitubercular drugs induced hepatic damage: An experimental study. *Phytother Res* 2008;22:646-50.
- Das SK, Vasudevan DM. Protective effects of Silymarin, a milk thistle (*Silybium marianum*) derivative on ethanol induced oxidative stress in liver. *Indian J Biochem Biophys* 2006;43:306-11.
- Yoganarasimhan SN. Medicinal plants of India (Tamilnadu). Vol II. Bangalore: Interline publishing private Ltd; 2000. p. 512.
- Anonymous. The Ayurvedic Pharmacopoeia of India. Ministry of Health and Family Welfare, Government of India, New Delhi; 2001. p. 127-8.
- Anonymous. The Ayurvedic Formulary of India. Ministry of Health and Family planning, Government of India, New Delhi; 1978. p. 209.
- Sharma PC, Yelne MB, Dennis TJ. Database on medicinal plants used in Ayurveda-V-5. New Delhi: Central council for Research in Ayurveda and Siddha, Government of India; 2002. p. 251-9.
- Geethalakshmi R, Sakravarthi C, Kritika T, Arul Kirubakaran M, Sarada DV. Evaluation of antioxidant and wound healing activity of *Sphaeranthus amaranthoides* Burm. f. *BioMed Res Int* 2013. doi.org/10.1155/2013/607109. [Article in press]
- Swarnalatha L, Neelakanta Reddy P. Hepatoprotective activity of *Sphaeranthus amaranthoides* on D-galactosamine induced hepatitis in albino rats. *Asian J Trop Biomed* 2012;2(3):S1900-5.
- Gamble JS. Flora of the presidency of madras. Vol. II. Dehra Dun: Bishen Singh Mahendra Pal Sing; 1921. p. 691.
- Kokate CK. Practical Pharmacognosy. New Delhi: Vallabh Prakashan; 1999. p. 107-21.
- Harborne JB. Phytochemical Methods. A guide to modern techniques of plant analysis, 3rd ed. London: Chapman and Hall; 1998. p. 4-7.
- Raaman N. Phytochemical Techniques. New Delhi: New India Publishing Agency; 2006. p. 19-24.
- Brain KR, Turner TD. The Practical evaluation of Phyto pharmaceuticals. Bristol: Wright-Scientific; 1975. p. 82.
- Wagner H, Bladt S. Plant drug analysis. 2nd ed. Bristol: Springer; 1996. p. 54-254.
- OECD/OCDE. OECD guidelines for testing of Chemical-423; 2001.
- Kulkarni SK. Hand book of Experimental Pharmacology. New Delhi: Vallabh Prakashan; 1999. p. 168-71.
- Nirmala M, Girija K, Lakshman K, Divya T. Hepatoprotective activity of *Musa paradisica* on experimental animal models. *Asian Pac J Trop Biomed* 2012;2(1):11-5.
- Jose MM, Aledo JL, Cristina PG, Estebandelvalle MS. Interrelationship between oxidative damage and antioxidant enzyme activities: an easy and rapid experimental approach. *Biochem Educ* 2000;28(2):93-5.
- Chatterjee M, Sil PC. Hepatoprotective effect of aqueous extract of *Phyllanthus niruri* on nimesulide induced oxidative stress *in vivo*. *Indian J Biochem Biophys* 2006;43:299-305.
- Sumanth M, Ahmed R. Antihepatotoxic and antioxidant activity of root of *Taraxacum officinale* in CCl₄-intoxicated rats. *Phcog Mag* 2008;16(4):188-94.
- Koop DR. Oxidative and reductive metabolism by cytochrome P450 2E1. *FASEB J* 1992;6:724-30.
- Lee WM. Acetaminophen and the U. S. Acute Liver Failure Study Group: lowering the risks of hepatic failure. *Hepatology* 2004;40:6-9.
- Larson AM, Polson J, Fontana RJ. Acetaminophen induced acute liver failure: results of a United States multicenter, prospective study. *Hepatology* 2005;42:1364-72.
- Bernal W. Changing patterns of causation and the use of transplantation in the United Kingdom. *Semin Liver Dis* 2003;23:227-37.
- Nanji AA, Jokelainen K, Foutouhinia M, Rahemtulla A, Thomas P, Tipoe GL. Increased severity of alcoholic liver injury in female rats: role of oxidative stress, endotoxin and chemokines. *Am J Physiol: Gastrointest Liver Physiol* 2002;281:G1348-56.
- Kapur V, Pillai KK, Hussain SZ, Balani DK. Hepatoprotective activity of Jigrine on liver damage caused by alcohol-carbon tetrachloride and Paracetamol in rats. *Indian J Pharmacol* 1994;26:35-40.
- Jollow DJ, Thorgeirsson SS, Potter WZ, Hashimoto M, Mitchell JR. Acetaminophen induced hepatic necrosis. VI. Metabolic disposition of toxic and nontoxic doses of acetaminophen. *Pharmacology* 1974;12:251-71.
- Taniguchi H, Yomota E, Nogi K, Onoda Y. Effects of anti-ulcer agents on ethanol-induced gastric mucosal lesions in D-Gal N induced hepatitis rats. *Drug Res* 2004;2:600-4.
- Keppeler D, Pausch J, Decker K. Selective uridine triphosphate deficiency induced by D-galactosamine in liver and reversed by pyrimidine nucleotide precursors. Effect on ribonucleic acid synthesis. *J Biol Chem* 1974;249:211-6.
- Quintero A, Pedraja CA, Siendones E, Kamal EI, Said AM, Colell A, et al. PGE1 protection against apoptosis induced by D-galactosamine is not related to the modulation of intracellular free radical production in primary culture of rat hepatocytes. *Free Radical Res* 2002;36:345-55.
- Sire O, Mangenev M, Montagne J, Nordmann R, Nordmann J. Carnitine palmitoyltransferase I. Inhibition by D-galactosamine and role of phospholipids. *Eur J Biochem* 1983;136:371-5.
- Juraj G, Zuzana C, Maria M, Zenobia C, Vladimira T, Gabriela M, et al. Effect of quercetin on paracetamol-induced rat liver mitochondria dysfunction. *Biologia Bratislava* 2004;59 (3):399-403.